

Neurology®

Conduction aphasia in multiple sclerosis : A case report with MRI findings

P. A. Arnett, S. M. Rao, M. Hussain, et al.

Neurology 1996;47;576

DOI 10.1212/WNL.47.2.576

This information is current as of December 9, 2012

The online version of this article, along with updated information and services, is located on the World Wide Web at:

<http://www.neurology.org/content/47/2/576.full.html>

Neurology® is the official journal of the American Academy of Neurology. Published continuously since 1951, it is now a weekly with 48 issues per year. Copyright © 1996 by AAN Enterprises, Inc. All rights reserved. Print ISSN: 0028-3878. Online ISSN: 1526-632X.



Conduction aphasia in multiple sclerosis: A case report with MRI findings

Article abstract—Aphasia is an uncommon manifestation of MS, which is somewhat surprising because various disconnection syndromes, such as conduction aphasia, would be expected to occur with some regularity in this white matter disease. We present a case study of an MS patient with conduction aphasia associated with a large white matter lesion underlying the left supramarginal gyrus.

NEUROLOGY 1996;47:576-578

P.A. Arnett, PhD; S.M. Rao, PhD; M. Hussain, MD; S.J. Swanson, PhD; and T.A. Hammeke, PhD

The cerebral hemispheric white matter can be extensively involved in patients with MS.¹ As a consequence, a wide range of disconnection syndromes² would be expected to occur in this disease. Our earlier research³ has shown that MS patients exhibit an exaggerated right ear effect on verbal dichotic listening and an abnormally slowed vocal reaction to naming stimuli presented tachistoscopically to the left visual field. These findings were observed primarily in MS patients with atrophy of the corpus callosum, suggesting a reduction or disconnection of information flow between the cerebral hemispheres.

To date, there have been no reports of intrahemispheric disconnection syndromes in MS. One such disconnection syndrome, conduction aphasia, is thought to result from lesions of the arcuate fasciculus, presumably separating temporal from frontal language areas.² Conduction aphasia is characterized by severely impaired repetition, fluent verbal output consisting of mostly literal paraphasic errors, and spelling errors characterized by alterations in the sequence of letters; in contrast, comprehension, reading, and naming are well preserved.² The most common lesion site involves the white matter tracts underlying the dominant supramarginal gyrus.^{2,4}

We report on an MS patient with large white matter lesions subjacent to the left supramarginal gyrus and a symptom pattern consistent with the diagnosis of conduction aphasia.

Case report. A 26-year-old right-handed woman presented with the acute onset of right arm weakness and decreased sensation, an inability to write or manipulate objects with her right hand, word-finding problems, speech abnormalities with normal comprehension, and severe fatigue. She also observed a worsening of right leg numbness, which initially presented 2 years previous to her current admission. One month before admission, she experienced left visual field changes with blurring, intermittent darkening, and photophobia. CSF results were abnormal with two oligoclonal bands, IgG index 1.22, IgG/albumin ratio 0.47, and IgG synthesis rate 16.81. Based on the clinical examination and medical workup, the patient was diagnosed with definite MS with a relapsing-remitting course. Past medical history included two episodes of minor head trauma without residual neurologic sequelae.

A comprehensive neuropsychological evaluation was

conducted during her admission. The patient was found to be oriented in all spheres. Spontaneous conversational speech was fluent (phrase length consistently exceeded 7 words) and coherent but characterized by aprosodia, word-finding problems approximately every other phrase, and occasional literal paraphasic errors. The table summarizes the results of formal language testing. On the Boston Diagnostic Aphasia Examination, the patient showed evidence of repetition speech difficulties with literal paraphasic errors. Her fluency, comprehension, oral reading, and naming skills were otherwise intact. Confrontation naming was also assessed with the Boston Naming Test and found to be normal. Because the patient's motor deficits precluded her from manipulating a writing instrument, agraphia could not be assessed directly; numerous literal paraphasic errors were noted, however, on an oral spelling task. Calculation skills were assessed orally and visually, again due to the patient's difficulty using a writing implement; she displayed significant calculation impairments that were particularly striking given her occupation as an accountant. On several problems, the patient attempted to count out solutions on her fingers without success.

Performance on the Benton Right-Left Orientation Test was impaired. Finger agnosia was assessed using a tactile finger localization task. With this task, the examiner assigns a number to each finger, then touches the fingers of each hand in a predetermined order with the subjects' eyes closed and hands extended. Subjects then report the number of the finger they believe the examiner touched. The patient's performance on this test was normal with the left hand and impaired with the right; this asymmetry indicates that the impaired right-sided performance was due to a reduction in tactile sensation rather than a higher order deficit in finger localization.

On the Wechsler Adult Intelligence Scale-Revised (WAIS-R) subtests, the patient's performance was impaired on a measure of auditory memory span (Digit Span), a finding consistent with the repetition speech abnormalities characteristic of conduction aphasia. The patient's performance was otherwise within the normal range on measures of verbal abstraction (Similarities) and visual-spatial construction/reasoning (Block Design) from the WAIS-R. She showed her only other area of cognitive impairment on a verbal word-list learning task (Verbal Selective Reminding Test). The patient's performance was within the normal range on measures of angle perception (Judgment of Line Orientation Test), discrimination of faces (Facial Recognition Test), visual-spatial memory (7/24 Spatial Recall Test), and conceptual reasoning (Wisconsin Card Sorting Test).

Table Results of language testing

Boston Diagnostic Aphasia Examination	
Impaired	Intact
Repetition (frequent phonemic paraphasic errors with repetitive attempts at self-correction)	Oral reading Fluency
Recitation, singing, and rhythm	Auditory comprehension
Articulation (halting)	Naming
Melodic line (flat)	Reading comprehension
Automatized sequences	
Boston Naming Test: Intact (55 correct)	
Oral Spelling Evaluation	
Stimulus	Patient response
Dog	"Dog"
Watch	"Watacw"
Shirt	NR
Pencil	"Pencil"
Shoe	NR
Finger	"Figna"
Calculation Evaluation	
Oral Calculation	
Stimulus	Patient response
6 + 3	"9"
3 + 5	"15"
8 + 6	"12"
24 - 9	NR
15 - 7	"8"
Visual Calculation	
Stimulus	Patient response
17 - 9	NR
6 - 3	"5"
3 + 5	"8"
16 + 75	NR
28 - 16	NR
Benton Right-Left Orientation: 12/20 correct (impaired)	
Finger Gnosis (Tactile Finger Localization Task): right (not administered due to primary sensory loss); left (20/20)	

NR = no response after 60 s.

An MRI revealed multiple white matter lesions (figure). Large confluent areas of demyelination were found within the left posterior cerebral hemisphere, involving primarily the white matter beneath the supramarginal gyrus and encroaching on the angular, precentral, postcentral, and middle temporal gyri. Small lesions were also observed in the periventricular white matter of the right hemisphere.

Discussion. Previous controlled neuropsychological investigations have shown that repetition speech, fluency, and comprehension are generally intact in MS patients, although mild deficits in naming and word generation occur with some regularity,^{5,6} presumably due to a more generalized deficit in semantic retrieval.⁵ Obvious aphasic symptoms (e.g., paraphasic errors) are considered to be uncommon and have been reported in only a small number of clinical case reports.⁷⁻⁹ Achiron et al.,⁹ for example, reported two MS patients with acute onset of nonfluent aphasia. Serial MRIs demonstrated the acute appearance

of large (>5 cm) plaques in the left frontal region in one case and the left centrum semiovale in the second that corresponded with the onset of the aphasia.

Our report is the first to describe a case of conduction aphasia in MS. In addition to having the hallmark features (impaired repetition, fluent but paraphasic verbal output, and impaired spelling in the context of normal comprehension, naming, and reading), the patient had multiple large lesions involving the white matter subjacent to the dominant supramarginal gyrus. This symptom cluster did not occur in the context of a more generalized decline in cognitive functioning, because she performed normally on measures of verbal abstraction, visuoconstruction, visuospatial memory, angle perception, facial discrimination, and conceptual reasoning. It is unclear as to why conduction aphasia is not more frequently reported in the MS literature. One possible explanation is that this patient had unusually large white matter lesions extending close to the cortical surface.

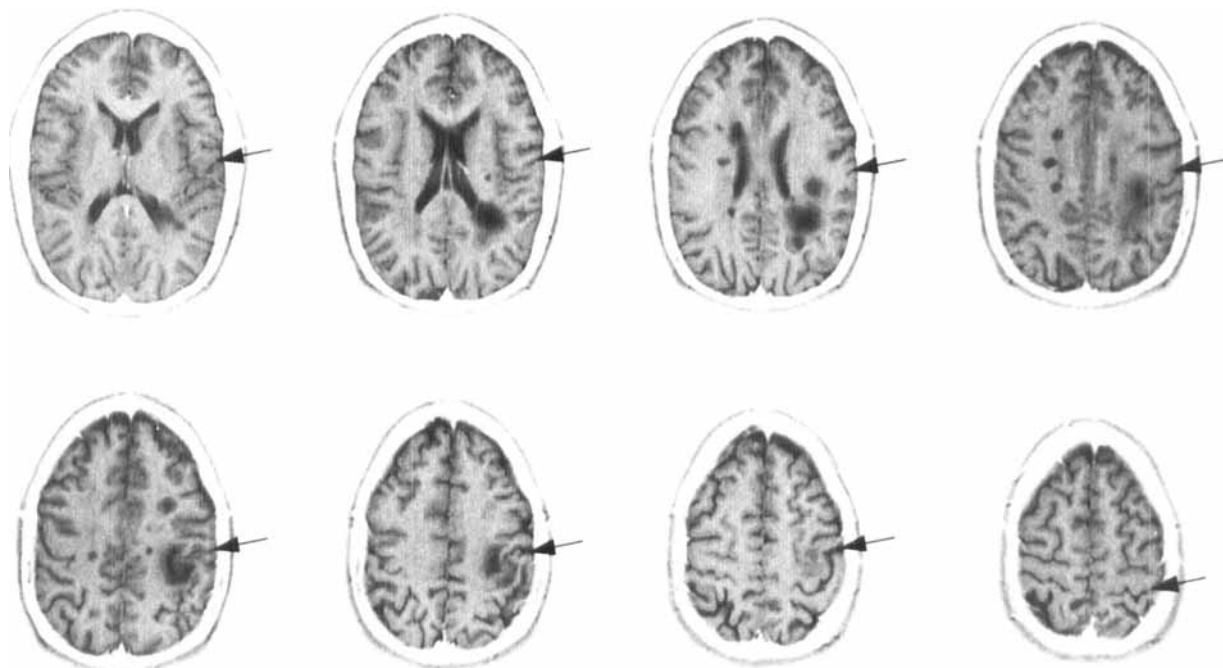


Figure. Results of a T_2 -weighted MRI (patient's left is on the reader's right). Arrows indicate the location of the central sulcus. See text for description of lesions. Note: images have been inverted to form a negative of the original scan.

The patient also exhibited symptoms of dyscalculia and right-left disorientation, typically associated with lesions of the angular gyrus. Our patient, therefore, displayed two of four elements of Gerstmann's syndrome, because she did not evidence bilateral finger agnosia and we were unable to assess her graphomotor skills. Inspection of the MRI suggests some degree of encroachment of the angular gyrus.

Our initial study correlating MRI findings with neuropsychological testing¹⁰ suggested a nonspecific relationship between total lesion burden and the overall severity of cognitive impairment in MS patients. The current report suggests that focal neurobehavioral syndromes occur in MS and can be related to the specific location of the white matter lesions observed on MRI.

From the Department of Psychology (Dr. Arnett), Washington State University, Pullman, WA; and the Department of Neurology (Drs. Rao, Hussain, Swanson, and Hammeke), Medical College of Wisconsin, Milwaukee, WI.

Supported in part by a grant from the National Multiple Sclerosis Society (RG2605) to Dr. Rao.

Presented in part at the 25th annual meeting of the International Neuropsychological Society, Seattle, WA, February, 1995.

Received September 19, 1995. Accepted in final form December 20, 1995.

Address correspondence and reprint requests to Dr. Peter Arnett,

Psychology Department, Washington State University, Pullman, WA.

References

1. Lumsden CE. The neuropathology of multiple sclerosis. In: Vinken PJ, Bruyn GW, eds. Handbook of clinical neurology. Vol. 9, Multiple sclerosis and other demyelinating diseases. New York: Elsevier, 1970:217-309.
2. Geschwind N. Disconnexion syndromes in animals and man. *Brain* 1965;88:237-294.
3. Rao SM, Bernardin L, Leo GJ, Ellington L, Ryan SB, Burg LS. Cerebral disconnection in multiple sclerosis: relationship to atrophy of the corpus callosum. *Arch Neurol* 1989;46:918-920.
4. Damasio H, Damasio A. The anatomical basis of conduction aphasia. *Brain* 1980;103:337-350.
5. Rao SM, Leo GJ, St. Aubin-Faubert P. On the nature of memory disturbance in multiple sclerosis. *J Clin Exp Neuropsychol* 1989;11:699-712.
6. Beatty WW, Monson N. Lexical processing in Parkinson's disease and multiple sclerosis. *J Geriatr Psychiatry Neurol* 1989; 2:145-152.
7. Olmos-Lau N, Ginsberg MD, Geller JB. Aphasia in multiple sclerosis. *Neurology* 1977;27:623-626.
8. Friedman JH, Brem H, Mayeux R. Global aphasia in multiple sclerosis. *Ann Neurol* 1983;13:222-223.
9. Achiron A, Ziv I, Djaldetti R, Goldberg H, Kuritzky A, Melamed E. Aphasia in multiple sclerosis: clinical and radiologic correlations. *Neurology* 1992;42:2195-2197.
10. Rao SM, Leo GJ, Haughton VM, St. Aubin-Faubert P, Bernardin L. Correlation of magnetic resonance imaging with neuropsychological testing in multiple sclerosis. *Neurology* 1989;39: 161-166.

Conduction aphasia in multiple sclerosis : A case report with MRI findings

P. A. Arnett, S. M. Rao, M. Hussain, et al.

Neurology 1996;47;576

DOI 10.1212/WNL.47.2.576

This information is current as of December 9, 2012

Updated Information & Services	including high resolution figures, can be found at: http://www.neurology.org/content/47/2/576.full.html
Citations	This article has been cited by 5 HighWire-hosted articles: http://www.neurology.org/content/47/2/576.full.html#related-urls
Permissions & Licensing	Information about reproducing this article in parts (figures, tables) or in its entirety can be found online at: http://www.neurology.org/misc/about.xhtml#permissions
Reprints	Information about ordering reprints can be found online: http://www.neurology.org/misc/addir.xhtml#reprintsus

