

## PURE ALEXIA WITHOUT AGRAPHIA: A CLASSICAL CORTICAL SYNDROME REVISITED

*J S Duffield R N de Silva R Grant*

Department of Medicine Royal Infirmary of Edinburgh and  
Department of Clinical Neurosciences, Western General Hospital, Edinburgh

**Abstract:** *A patient who developed pure alexia without agraphia following a stroke is described. An infarction of the left occipital pole was demonstrated by Magnetic Resonance Imaging (MRI). The literature on this rare syndrome is reviewed, and the localisation of damage in relation to the clinical findings discussed.*

**Key words:** Alexia; agraphia; cerebrovascular disease; magnetic resonance imaging

### Case Report

A 58 year-old, right-handed man presented with sudden-onset inability to read. Speech, comprehension and vision were unaffected. Past medical history was unremarkable, and he was on no regular medication. He smoked ten cigarettes a day and consumed ten units of alcohol weekly. Examination revealed normal orientation and speech functions. He was unable to read but wrote normally. Visual fields were normal. There was mild, left-sided finger-nose ataxia and dysidiadochokinesis. Blood pressure and heart sounds were normal. The following investigations were normal or negative: ESR, routine biochemistry and haematology, glucose and syphilis serology. Chest X-ray revealed cardiomegaly, and electrocardiography indicated left ventricular hypertrophy with strain. Computerised tomography ten days following the onset of symptoms was normal. Transthoracic echocardiography was normal.

Further cognitive assessment during his hospitalisation revealed mildly impaired short and medium term memory (two out of three objects were recalled after five minutes; past US presidents were described as

"the actor" (Reagan) and "wee fellow" (Bush)). There was no dysphasia or difficulties with repetition. He named objects and identified colours without difficulty. Individual letters were recognised normally and words were spelt correctly. He could not comprehend written words. Writing was preserved but comprehension of his own written output was poor. He had some difficulty recognising words that had been spelt out to him aloud. He recognised numbers and performed calculations normally.

On review three weeks later, his reading was slightly improved. He tended to read aloud, possibly in order to recognise words auditorily. There was a marked word length effect, so that he was slower at reading longer words. His cerebellar incoordination had resolved fully. He was initiated on Aspirin therapy, and arrangements made to monitor his blood pressure regularly. He was advised to stop smoking.

MRI was performed two months after the onset of symptoms. T2 axial images revealed a discrete area of high signal in the left occipital cortex (Fig. 1).

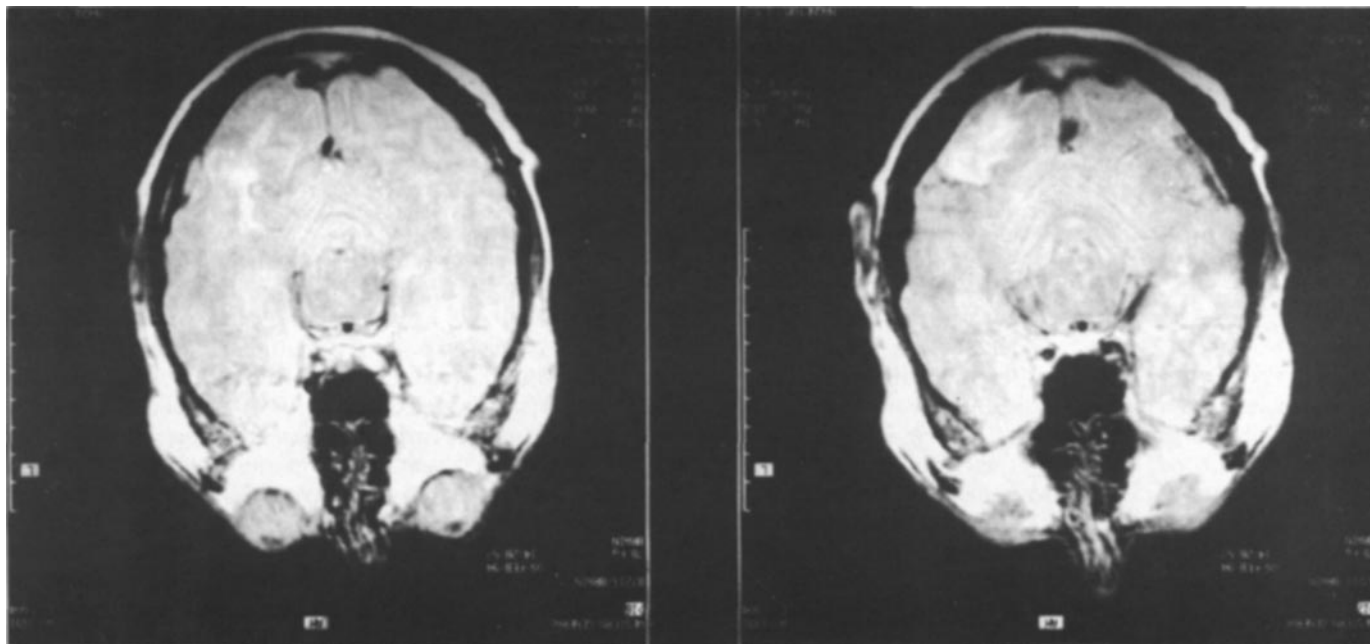
### Discussion

Pure alexia without agraphia is an unusual syndrome, first described by Dejerine in 1892.<sup>1</sup> He followed up an affected patient for four years, and at post-mortem an old infarction of the left occipital lobe and splenium of the corpus callosum was demon-

---

Correspondence and requests for reprints to: Dr R de Silva, Department of Clinical Neurosciences, Western General Hospital, Crewe Road, Edinburgh EH4 2XU

**Fig 1** Consecutive T2-weighted Magnetic Resonance Images of the brain, showing a discrete area of high signal in the left occipital cortex, indicative of infarction.



strated.<sup>1</sup> He argued that the visual cortex had been effectively disconnected from the speech area. In addition to the damaged left visual cortex, the connections (in the splenium of the corpus callosum?) between the intact right visual cortex and the language centre had been damaged. This view was popularised by Geschwind,<sup>2</sup> and subsequent communications have claimed its association with deficiencies of colour naming<sup>3</sup> and impairment of short-term memory.<sup>4</sup> A right hemianopia or superior quadrantanopia is said to be present almost always.<sup>5</sup>

Pure alexia with agraphia, in contrast, is acquired illiteracy, where a previously educated patient is rendered unable to read and write. Lesions typically involve the inferior parietal lobe, especially the angular gyrus.

The clinical findings and MRI appearances in the current patient were those of the first syndrome, although there were points at variance with the classical descriptions. A visual field defect could not be demonstrated clinically, and the patient had no difficulties in naming colours. His difficulties in formulating words spelt out to him was also interesting. Geschwind argued that this was normally preserved in patients with pure alexia without agraphia because the centre which converts spoken into written language and vice versa remained intact in this condition.<sup>2</sup> He went on to describe a mechanism for this task which entailed the generation of words from letters which are then "read". The cortical localisation of this process is not known. A recent report has drawn attention to an alternative strategy, where words are comprehended "whole" without the

requirement for a letter-by-letter analysis of each word.<sup>6</sup> If this patient was relying on such a mechanism for overcoming his disability, he would have been disadvantaged when words were spelt out to him letter-by-letter.

This report emphasises the usefulness of MRI in establishing cortical infarction, even several months after the event. It is worth reflecting on the fact that one of the latest techniques of neuroimaging has been utilised here to confirm the localisation during life of a syndrome first described more than a century ago.

Acknowledgements: The authors thank Dr. MF Sudlow for his permission to report the case, Dr. R Gibson for interpreting the MRI and Dr. J Greene for helpful comments.

#### REFERENCES

1. Dejerine J. Contribution a l'etude anatomo-pathologique et clinique des differentes varietes de cecite verbale. *Comptes Rendus Hebdomadaires des Seances et Memoires de la Societe de Biologie*, Ninth series 1892; 4: 61-90.
2. Geschwind N. Disconnexion syndromes in animals and man. Part I. *Brain* 1965; LXXXVIII: 237-94.
3. Geschwind N, Fusillo M. Color-naming deficits in association with alexia. *Arch. Neurol.* 1966; 15: 137-46.
4. Benson DF, Marsden CD, Meadows JC. The amnesic syndrome of posterior cerebral artery occlusion. *Acta Neurol. Scand.* 1974; 50: 133-45.
5. Kirshner HS. Language disorders. In: Bradley WG, Daroff RB, Fenichel GM, Marsden CD, eds. *Neurology in clinical practice*. Boston: Butterworth Heinemann 1989: 101-15.
6. Coslett HB, Saffran EM, Greenbaum S, Schwartz H. Reading in pure alexia. The effect of strategy. *Brain* 1993; 116: 21 -37.