

Arteriovenous Malformation Associated with Pleomorphic Xanthoastrocytoma

T. T. Lee, H. J. Landy, and J. H. Bruce

Department of Neurological Surgery and Department of Pathology, University of Miami/Jackson Memorial Hospital, Miami, FL, U.S.A.

Summary

A case of a left temporo-occipital arteriovenous malformation associated with a pleomorphic xanthoastrocytoma is described. The patient had the vascular lesion with a stable right hemiparesis for many years prior to his recent clinical deterioration. Correlation is made with nine previously reported cases of angiogliomas. With the close proximity and temporal correlation of the two components of this lesion, as well as pathological evidence, the authors propose that angioglioma may be the product of reactive glial proliferation and transformation secondary to a pre-existing vascular malformation and hemorrhage.

Keywords: Angioglioma; arteriovenous malformation (AVM); pleomorphic xanthoastrocytoma (PXA).

Case Report

The patient is a 45-year-old male with a 15-year history of generalized tonic-clonic seizures, right hemiparesis, and a known left temporo-occipital arteriovenous malformation. The patient recently noted increasing hemiparesis and frequency of tonic-clonic seizures. Cranial nerve examination revealed a dense right homonymous hemianopsia. Motor exam demonstrated a right hemiparesis and spasticity.

Computerized tomography (CT) and magnetic resonance imaging (MRI) revealed the left temporo-occipital enhancing lesion associated with edema and a degree of encephalomalacia. Cerebral angiogram showed a small AVM nidus with an early draining vein. Single photon emission computerized tomography (SPECT) demonstrated increased thallium uptake.

The patient underwent a left temporo-parieto-occipital craniotomy for resection of the lesion. The brain surface appeared grossly atrophic and thin. A cystic lesion was encountered, and yellow fluid was aspirated. A gross total resection of the lesion was achieved. The vessel feeding the arteriovenous malformation (AVM) was identified, coagulated, and serially divided. Postoperatively, his right upper and lower extremity strength remained unchanged. Postoperative CT scan showed no definite residual tumor, and a postoperative angiogram demonstrated no residual vascular malformation.

Hematoxylin and eosin (H & E) stained sections of the specimen showed two distinctive histological patterns. The discrete areas of vascular malformation were intersected by a diffusely infil-

trating glioma with focal microcystic change. The tumor consisted of bipolar neoplastic astrocytes lying in a densely fibrillated and reticulin-rich matrix. Abundant perivascular infiltration, cytoplasmic vacuolization, with pleomorphic cells were identified. Reactive gliosis and numerous hemosiderin-laden macrophages were found. The tumor stained positively for glial fibrillary acidic protein (GFAP), alpha-1-anti-trypsin, and S-100 protein. The glioma component was diagnosed as pleomorphic xanthoastrocytoma (PXA).

Discussion

The authors hypothesize the initial presence of the vascular malformation with possible hemorrhage, with resultant glial proliferation followed by transformation into glial tumor. Four cases [1, 2, 4], including ours, showed initial occurrence of the vascular malformation and the subsequent finding of a neoplastic component at the same site. In the remainder of the patients, both components were encountered at the time of surgery (Table 1).

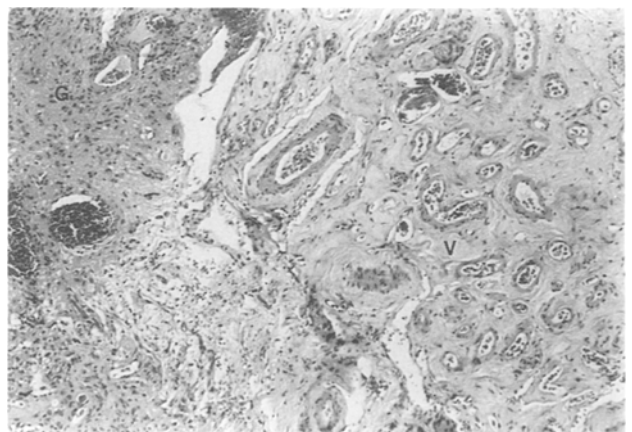


Fig. 1. Low-power view of the lesion showing an abnormal proliferation of hyalinized vessels (V) lying side-by-side with the glioma (G). (H & E 200×)

Table 1. Cases of Angiogliomas

Authors	Age	Sex	Location	Malformation	Tumor	Initial lesion
Chee <i>et al.</i>	25	M	R frontal	cavernous	oligodendroglioma	both
Crowell <i>et al.</i>	17	M	R frontal	AVM	oligodendroglioma	both
Fischer <i>et al.</i>	11	M	L frontal	cavernous	oligodendroglioma	malformation
	19	F	R frontal	cavernous	polymorphic glial	both
Goodkin <i>et al.</i>	9	F	L fronto-pariet.	AVM	astrocytoma	malformation
Heffner <i>et al.</i>	17	M	R frontal	AVM	astrocytoma	both
Lee <i>et al.</i>	45	M	L temporo-occip.	AVM	PXA	malformation
Licata <i>et al.</i>	44	M	R parietal	AVM	gliosarcoma	malformation
Lombardi <i>et al.</i>	17	M	L thalamic	AVM	oligodendroglioma	both
Zuccarello <i>et al.</i>	50	M	L temporal	AVM	astrocytoma	both

Pathological analysis also supports the above hypothesis. Hemosiderin-laden macrophages and reactive gliosis were found in the vicinity of this lesion, as in others [2, 3, 5]. These may represent the transition between the vascular precursors and angioglioma. Patients with known vascular malformations should be imaged to investigate the possibility of an associated neoplasm in the cases of clinical deterioration.

References

1. Fischer EG, Sotrl A, Welch K (1982) Cerebral hemangioma with glial neoplasia (angioglioma?): report of two cases. *J Neurosurg* 56: 430–434
2. Goodkin R, Zaias B, Michelsen WJ (1990) Arteriovenous malformation and glioma: coexistent or sequential? Case report. *J Neurosurg* 72: 798–805
3. Heffner RR, Porro RS, Deck MDF (1971) Benign astrocytoma with associated with arteriovenous malformation: case report. *J Neurosurg* 35: 229–233
4. Licata C, Pasqualin A, Freschini A, *et al* (1986) Management of associated primary cerebral neoplasms and vascular malformations: 2 intracranial arteriovenous malformations. *Acta Neurochir (Wien)* 83: 38–46
5. Lombardi D, Scheithauer BW, Piepgras D, *et al* (1991) Angioglioma and the arteriovenous malformation-glioma association. *J Neurosurg* 75: 859–886

Correspondence: Thomas T. Lee, M.D., Department of Neurological Surgery, University of Miami School of Medicine, P.O. Box 016960 (M813), Miami, FL 33101, U.S.A.