

sions [2] or more severe spinal cord lesions, which also interrupted connections between the brain stem and the spinal cord neurons. In our patient there must have been some influence of supraspinal centres upon spinal cord neurons, because the patient could still walk.

The use of a three-way stopcock during emptying and refilling is mandatory in the type of pump described. For safety reasons this pump type should be filled by the surgeon himself or under his supervision during surgery or by the attending physician after surgery. Further, we would advise an observation period of at least 1 h after a baclofen bolus or filling of a pump to reduce the risk of missing an acute overdose.

References

1. Delhaas EM, Brouwers JRBJ (1991) Intrathecal baclofen overdose: report of 7 events in 5 patients and review of the literature. *Int J Clin Pharmacol Ther Toxicol* 29:274–280
2. Kofler M, Saltuari L, Schmutzhard E, Berek K, Baumgartner H, Russegger L, Aichner F (1992) Electrophysiological findings in a case of severe intrathecal baclofen overdose. *Electroencephalogr Clin Neurophysiol* 83:83–86
3. Müller-Schwefe G, Penn RD (1989) Physostigmine in the treatment of intrathecal baclofen overdose. *J Neurosurg* 71:273–275
4. Ashworth B (1964) Preliminary trial of carisoprodol in multiple sclerosis. *Practitioner* 192:540–542
5. Sallerin-Caute B, Lazorthes Y, Monsarrat B, Cros J, Bastide R (1991) CSF baclofen levels after intrathecal administration in severe spasticity. *Eur J Clin Pharmacol* 40:363–365

J. Dressnandt (✉) · T. R. Tölle
A. Konstanzer · B. Conrad
Department of Neurology,
Technical University, Möhlstrasse 28,
D-81675 Munich, Germany
Tel.: +49-89-41404660
Fax: +49-89-41404867

F. X. Weinzierl
Department of Neurosurgery,
Technical University, Munich, Germany

D. G. Nabavi
P. Zunker
T. Mumme
D. Georgiadis

Cheiro-oral syndrome due to severe stenosis of the middle cerebral artery

Received: 6 December 1995
Accepted: 26 January 1996

Sirs: The cheiro-oral syndrome (COS), a pure sensory disorder restricted to the corner of the mouth and the hand on the same side, has been attributed exclusively to lesions of the central somatosensory pathways [4, 9, 10, 15] visualized on imaging studies [7] or at autopsy [14]. We describe a patient with relapsing-remitting COS due to high-grade stenosis of the contralateral middle cerebral artery (MCA) and without any other abnormality of the arterial system.

A 57-year-old woman was admitted to hospital with an 1-year history of repeated paraesthesias at the right corner of the mouth and the ulnar site of the ipsilateral hand. During the 2 months before admission, the frequency of attacks increased from once monthly to once weekly. She had moderate arterial hypertension, which was well controlled with an angiotensin-converting enzyme inhibitor. There was no history of smoking, hyperlipidaemia, diabetes mellitus or any other cardiovascular disease.

Neurological examination disclosed only a mild hypaesthetic area at the right corner of the mouth and in the right hand, while general examination was normal. After exclusion of intracranial bleeding by computed tomography of the brain, intravenous heparin was administered with a target partial thromboplastin time of 60–80 s. Four hours after initiation of anticoagulation, the sensory symptoms disappeared. Examination of the basal intracranial arteries by means of transcranial Doppler

sonography (TCD) revealed an extreme increase in blood flow velocity in the left MCA (mean flow about 245 cm/s) together with low-frequency components due to vessel wall vibrations. The diagnosis of a severe left-sided MCA stenosis was made and later confirmed by magnetic resonance angiography and intra-arterial digital subtraction angiography (Fig. 1). High-resolution magnetic resonance imaging of the brain 6 days after admission, including contrast-enhanced scans, did not disclose any pathological findings. Electrocardiogram, transthoracic echocardiography and coagulation tests were normal. Oral anticoagulation with phenprocoumon (Marcumar) was initiated 8 days after admission, and heparin was discontinued when the international normalized ratio reached target values (2.5–4.0).

Recent studies have suggested that TCD monitoring for microembolic signals (MES) provides information on the anticoagulation efficacy [5, 13] and is potentially of prognostic significance in patients with extracranial occlusive disease [12]. In our case, TCD monitoring for MES was performed on admis-

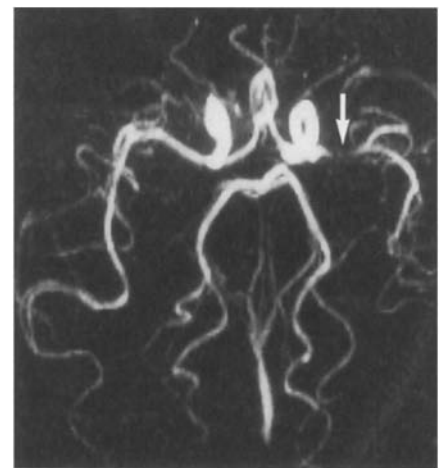


Fig. 1 Magnetic resonance angiography of the basal brain-supplying arteries showed > 70% narrowing (→) of the proximal left middle cerebral artery (MCA). Note that all basal arteries appear symmetrical, thus excluding an artificial loss of MCA flow signal due to erroneous plane section

sion, 1, 2 and 4 days after initiation of intravenous heparin and 3 months after discharge from hospital, when the patient was stabilized on oral anticoagulants. A pulsed ultrasound machine with a 2 MHz bigate probe was used, able to harvest simultaneously echos from spatially separated vessel portions (Pioneer 4040, EME, Überlingen, Germany). A proximal (depth: 58 mm) and distal segment (depth: 44 mm) of the left MCA were simultaneously monitored for 45 min. Sample volume was kept low (between 6 and 8 mm) throughout the examinations. All monitoring sessions were recorded on DAT tapes and evaluated by three independent observers blinded to the patient's clinical course. MES were detected according to criteria described elsewhere [3]. In the initial examination (observer 1: 4 MES; observer 2 and 3: 3 MES) MES were detected only in the poststenotic MCA segment, but neither in the prestenotic channel nor not in the following examinations (all three observers in agreement) while the patient was free of symptoms on anticoagulants.

The large somatotopic thalamic and cortical representation of the sensory fibres from the mouth and hand together with the close proximity in the brain stem and the thalamic nuclei [11] favour the simultaneous occurrence of sensory disturbances at these sites. A higher hypoxic vulnerability of these sensory fibres has been assumed to explain this particular distribution of symptoms [6], which is also seen in the hyperventilation syndrome [2], caused by hypocapnia-induced vasoconstriction leading to ischaemia [8]. In our case, both the detection of MES distal to the MCA stenosis while the patient was symptomatic and their cessation parallel to the regression of symptoms argue for an embolic rather than a haemodynamic induction of cerebral ischaemia, in accordance with current concepts [1]. The cessation of MES after initiation of intravenous heparin, which has already been reported by Siebler et al. [13], further underpins this hypothesis.

Use of the bigate probe in our patient identified the MCA stenosis as the active embolic source, since emboli of a more proximal origin (e.g. heart or internal carotid artery) would have been detected in both channels.

In conclusion, we have described a patient with repetitive COS due to severe MCA stenosis. TCD monitoring in this case provided information of potential clinical relevance.

References

- Adams HP, Gross CE (1981) Embolism distal to the stenosis of the middle cerebral artery. *Stroke* 12: 228–229
- Blau JN, Wiles CM (1983) Unilateral somatic symptoms due to hyperventilation. *BJM* 286: 1108
- Consensus Committee of the ninth international cerebral hemodynamic symposium (1995) Basic identification criteria of microembolic signals. *Stroke* 26: 1123
- Garcin R, Lapresle J (1960) Deuxième observation personnelle de syndrome sensitif de type thalamique et à topographie chéiro-orale par lésion localisée du thalamus. *Rev Neurol (Paris)* 103: 474–481
- Georgiadis D, Hill M, Zunker P, Stögbauer F, Ringelstein EB (1994) Anticoagulation monitoring with transcranial Doppler (letter). *Lancet* 344: 1373–1374
- Holter JT, Tijssen C (1988) Cheiro-oral syndrome: does it have a specific localizing value. *Eur Neurol* 28: 326–330
- Kawakami Y, Chikama M, Tanimoto T, Shimamura Y (1989) Radiological studies of the cheiro-oral syndrome. *J Neurol* 236: 177–181
- Kugelberg E (1948) Activation of human nerves by hyperventilation and hypocalcemia: neurological mechanism of symptoms of irritation in tetany. *Arch Neurol Psychiatry* 60: 153–164
- Omae T, Tsuchiya T, Yamaguchi T (1992) Cheiro-oral syndrome due to lesions in the corona radiata. *Stroke* 23: 599–601
- Ono S, Inoue K (1985) Cheiro-oral syndrome following midbrain haemorrhage. *J Neurol* 232: 304–306
- Penfield W, Boldrey E (1937) Somatic motor and sensory representation in the cerebral cortex of man as studied by electrical stimulation. *Brain* 60: 389–443
- Siebler M, Sitzer M, Rose G, Benfeldt D, Steinmetz H (1993) Silent cerebral embolism caused by neurologically symptomatic high-grade carotid stenosis. Event rates before and after carotid endarterectomy. *Brain* 116: 1005–1015
- Siebler M, Nachtmann A, Sitzer M, Steinmetz H (1994) Anticoagulation monitoring and cerebral microemboli detection (letter). *Lancet* 344: 555
- Sittig O (1914) *Klinische Beiträge zur Lehre von der Lokalisation der sensiblen Rindenzentren*. *Prag Med Wochenschr* 45: 548–550
- Yasuda Y, Akiguchi I, Ishikawa M, Kameyama M (1988) Bilateral cheiro-oral syndrome following pontine haemorrhage. *J Neurol* 235: 489–490

D. G. Nabavi (✉) · P. Zunker
T. Mumme · D. Georgiadis
Department of Neurology,
University of Münster,
Albert-Schweitzer-Strasse 33,
D-48129 Münster, Germany
Tel.: 49 251 838172
Fax: 49 251 838181

Marc Sanson
Charles Duyckaerts
Jean-Luc Thibault
Jean-Yves Delattre

Sarcoidosis presenting as late-onset dementia

Received: 12 September 1995
Received in revised form:
8 December 1995
Accepted: 17 December 1995

Sirs: There is neurological involvement in about 5% of patients with sarcoidosis, and neurological symptoms are the presenting manifestation of the disease in half the cases [8, 9]. Lesions may be found in the leptomeninges, particularly in the skull base, peripheral (including cranial) nerves, muscles and in the central nervous system, particularly the hypothalamus. In exceptional cases, sarcoidosis may cause a progressive dementia [4], mimicking more common degenerative or vascular processes. We report here a case in which neurosarcoidosis was responsible for slowly progressive dementia with widespread involvement of the central nervous system.