

A Pitfall in the Surgery of a Recurrent Aneurysm after Coil Embolization and Its Histological Observation: Technical Case Report

Kazuo Mizoi, M.D., Takashi Yoshimoto, M.D.,
Akira Takahashi, M.D., Yoshihide Nagamine, M.D.

Department of Neurosurgery (KM, TY), Tohoku University School of Medicine, and
Departments of Neurosurgery (YN) and Intravascular Neurosurgery (AT), Kohnan Hospital,
Sendai, Japan

OBJECTIVE AND IMPORTANCE: This case report details the unexpected surgical difficulty encountered in treating a recurrent aneurysm after coil embolization and presents the histological findings of the resected aneurysm. This is only the second reported case of histological description of an aneurysm after coil embolization in a human.

CLINICAL PRESENTATION: A 60-year-old woman experienced a 3-month history of chronic headache. Neuroimaging studies demonstrated a 2-cm anterior communicating artery aneurysm. The aneurysm was treated with a two-stage endovascular coil embolization, resulting in almost complete occlusion of the aneurysm. A cerebral angiogram at 6-month follow-up demonstrated slight refilling of the aneurysm, and angiography at 18 months showed a marked increase in the size of the small remnant. Therefore, the patient was referred for direct surgical repair of the aneurysm.

INTERVENTION: The distal aneurysm dome, which had been packed with the coils and thrombus, was resected under temporary arterial trapping. An intra-aneurysmal endarterectomy was required, because the aneurysm wall developed intimal dissection that extended to the orifices of afferent and efferent arteries. The aneurysm was then obliterated with multiple clips, reconstructing the patent vessel lumen. However, the patient awoke from surgery with left hemiparesis. A postoperative angiogram disclosed occlusion of the right anterior cerebral artery. An histological study of the thrombosed aneurysm showed that the luminal surface of thrombus was not lined by endothelium.

CONCLUSION: This case demonstrated not only the limited efficacy of coil embolization treatment for wide-necked aneurysms but also the potential difficulty in the direct surgical repair for such recurrent aneurysms. (Neurosurgery 39:165-169, 1996)

Key words: Cerebral aneurysm, Detachable coils, Embolization

Although endovascular therapy is attractive as a minimally invasive approach for treating intracranial aneurysms, it is not without morbidity

related to the procedure itself. In addition, the problem regarding the long-term efficacy of this technique in preventing subsequent growth and/or

rupture of the aneurysm is still unsettled. Recently, we treated a patient who required surgical repair of a recurrent aneurysm 18 months after the endovascular treatment with Guglielmi detachable coils (GDCs) (5, 6). This communication details unexpected surgical complications in treating such a recurrent aneurysm and presents the histological findings of the surgically resected recurrent aneurysm, which showed enlargement of the small remnant after electrothrombosis treatment.

CASE REPORT

A 60-year-old woman was referred to our facility for endovascular treatment of a large unruptured anterior communicating artery (ACoM) aneurysm, which was discovered by routine neuroimaging studies for a 3-month history of persistent headache. Angiograms showed a 2.0-cm global ACoM aneurysm with a wide neck of 6 mm (Fig. 1A). Because the A1 segment of the right anterior cerebral artery is hypoplastic, the aneurysm and bilateral distal anterior cerebral arteries were visualized only by a left carotid angiogram.

Endovascular procedure

Endovascular embolization was performed in two stages, using GDCs. At the first operation, nine coils were introduced into the aneurysm lumen through transfemoral catheterization under systemic anticoagulation. A postoperative angiogram demonstrated almost total obliteration of the aneurysm, with a small remnant of the neck. One month later, in the second-stage operation, three additional coils were placed into the aneurysmal remnant with a satisfactory result (Fig. 1B). The patient showed no new neurological deficits after both procedures.

Follow-up results

At the 6-month follow-up examination, a partial refilling of the aneurysm neck was identified. The patient was scheduled for further follow-up evaluation. At the 18-month review, angiogra-

phy demonstrated a marked increase in the size of the previously identified small remnant (Fig. 1C). Therefore, the patient was referred for direct surgery of the aneurysm.

Operation

At the operation, the entire dome of the aneurysm was exposed through a bifrontal interhemispheric approach. The aneurysm neck was located on the lateral side of the right A1-A2 junction, fed from the AComA (Fig. 2). By placing temporary clips on the AComA and right A1 and A2 segments, the aneurysm was completely trapped. The dome was then incised. The dome was packed with relatively fresh and nonorganized thrombus, with numerous coils (Fig. 3). It seemed that the luminal surface of thrombus was not lined by the endothelium. During the removal of the thrombus, dissection of the thickened intimal layer developed, which extended to the orifices of afferent and efferent arteries. Therefore, intra-aneurysmal endarterectomy was required. Multiple clips were placed on the base of the aneurysm, reconstructing the sufficient vessel lumen of afferent and efferent arteries. After surgery, however, the patient presented with left motor weakness. Postoperative angiography demonstrated occlusion of the right A2 segment. Distal segments of the

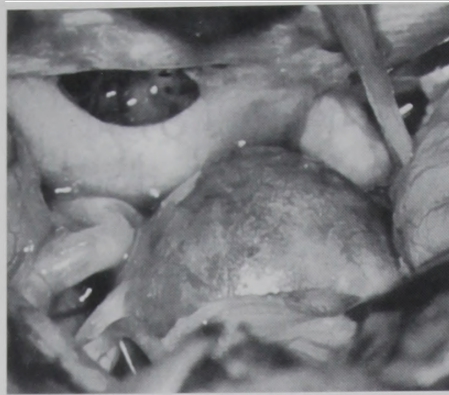

FIGURE 2. Intraoperative photograph showing the AComA aneurysm packed with numerous coils and organized thrombus. This thrombosed aneurysm had to be opened and resected for a better visualization of the surrounding arteries.

right anterior cerebral artery were visualized through leptomeningeal anastomosis from the left posterior cerebral artery.

The right hemiparesis gradually improved over several weeks, but weakness (three-fifths) of the right lower extremity persisted. The patient was discharged 1 month after surgery for rehabilitation at another hospital.

Histological study

Hematoxylin and eosin- and Masson's trichrome-stained sections demonstrated that the aneurysm wall was regularly thickened by dense sclerous collagen, with disappearance of the media and the internal elastic lamina. The intraluminal thrombus containing the platinum coils was poorly organized without fibrous tissue formation. There was no endothelial proliferation covering the luminal surface of the thrombus (Fig. 4). This was also confirmed by an immunohistochemical stain with Factor VIII.

DISCUSSION

Among several endovascular techniques for the treatment of aneurysms, coil embolization is recently thought to be the most promising approach. However, the success rate and long-term efficacy of this recent technique is still unknown. Casasco et al. (2) reported 71 patients with ruptured cerebral aneu-

rysms that were treated by endovascular techniques, with the use of Dacron-coated microcoils. Of 71 aneurysms, 60 (85%) were completely occluded and the other 11 (15%) were more than 90% occluded. However, follow-up angiography, with a mean follow-up period of 13 months, demonstrated the recurrence of aneurysms in 3 of the 60 completely occluded aneurysms and in 3 of the 11 residual aneurysms. Similar cases with recurrent or partially recanalized aneurysms after coil embolization have been reported (7-9).

Guglielmi et al. (5) reported an experimental study in which a side-wall aneurysm was surgically constructed in the common carotid artery of swine and treated by coil embolization. Histological observation demonstrated that the neck of the aneurysm is entirely occluded by organized thrombus, and the free luminal surface seems to be totally lined by endothelium. There are also several experimental studies that demonstrate the intimal proliferation over the platinum coils (3, 4, 10).

Only when such intimal overgrowth across the aneurysm neck is developed can the aneurysm be evaluated as completely isolated from the circulation. However, Molyneux et al. (13) recently reported autopsy studies in two patients with wide-necked giant aneurysms treated by GDCs. Although autopsies of these patients were performed at relatively short periods after endovascular treatment (2 and 6 mo, respectively), neither aneurysm demonstrated evidence of endothelialization of the aneurysm neck. In the present case, as well, the unorganized intra-aneurysmal thrombus was directly exposed to the blood circulation without neointimal formation. In such a situation, the effect of arterial blood pressure acting on the intra-aneurysmal thrombus is essentially similar to that in balloon embolization (water-hammer effect) (11). Subsequently, the coils can be pushed by the arterial pressure and become compacted toward the aneurysm dome (coil compaction), with further expansion of the aneurysm. Guglielmi et al. (7) stressed that dense packing with coils is essential for the endovascular treatment of aneurysms, because the densely packed coils bridge the intimal defect and prevent aneurysm redevelopment. How-

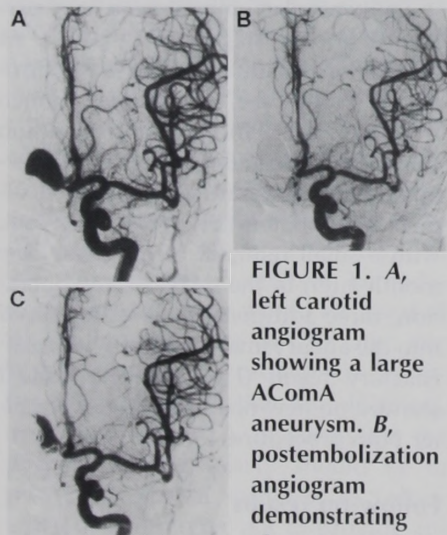


FIGURE 1. A, left carotid angiogram showing a large ACoM aneurysm. B, postembolization angiogram demonstrating almost complete

occlusion of the aneurysm. C, follow-up angiogram at 18 months post-embolization, showing recurrence of the aneurysm.

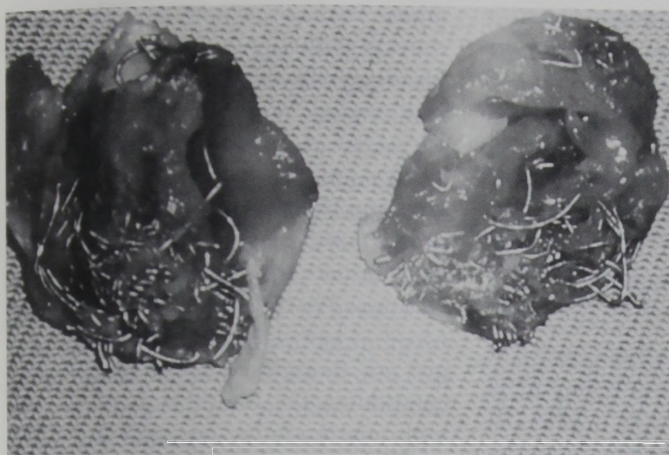


FIGURE 3. Photograph of the resected dome, looking into the aneurysm lumen. The relatively fresh thrombus mixed with coils was tightly adherent to the aneurysm dome. It seemed that there was no intimal overgrowth on the blood clot.

ever, they also report a clear relationship between the aneurysm neck size and treatment results; among 79 aneurysms, complete aneurysm thrombosis was observed in 85% of the small-necked aneurysms and in 15% of the wide-necked aneurysms (14). In this report, 4 mm was determined to be the discriminative value for small and wide necks.

For subsequent treatment of recurrent aneurysms after coil embolization, the choice of the appropriate management option is still controversial. Casasco et al. (1) and Knuckey et al. (9) reported cases for which coils were used for subsequent treatment. However, it seems it would be difficult and unreasonable to try to completely occlude the wide-necked recurrent aneurysm because repeated results can be anticipated. Consequently, for the present case, we selected direct surgery for subsequent treatment of the aneurysm. Nevertheless, in this case, dissection of the thickened intimal wall occurred during the

removal of the intraluminal clot. Intra-aneurysmal endarterectomy was performed, but it was very difficult to preserve the smooth luminal surface around the orifice of each vessel. Recently, Litofsky et al. (12) also described a similar surgical complication in a patient with a giant internal carotid artery aneurysm who experienced worsening visual deficit after embolization with GDCs. In that case, the aneurysm was opened and decompressed by a combination of endarterectomy and coil removal, as was done in our case. However, the attempt at direct clipping of the aneurysm resulted in occlusion of the parent artery.

More recently, Gurian et al. (8) reported 21 patients who required subsequent surgical treatment of cerebral aneurysms after failed or incomplete endovascular embolization. In five of these cases, the aneurysm neck was patent and pliable because the embolic agent (balloon or GDCs) had been com-

pacted into the aneurysmal dome. It is likely that proper clip application can be achieved without difficulty if embolic material does not exist around the base of the aneurysm. However, it seems that such a situation is uncommon, particularly when the aneurysm is densely packed with numerous coils and considerable time has elapsed since the last embolization.

In conclusion, the present case implied two important problems with coil embolization of aneurysms: 1) it is difficult to gain permanent obliteration of wide-necked aneurysms using GDCs; and 2) aneurysm surgery after coil embolization is hazardous because of the presence of numerous intraluminal coils and blood clot, and there exists the potential surgical pitfall of vessel occlusion. For the surgical treatment of the recurrent aneurysm after electrothrombosis, avoiding the development of intimal dissection seems to be crucial.

Received, January 16, 1996.

Accepted, February 6, 1996.

Reprint requests: Kazuo Mizoi, M.D., Department of Neurosurgery, Tohoku University School of Medicine, 1-1 Seiryō-Cho, Aoba-ku, Sendai, 980-77, Japan.

REFERENCES

1. Casasco A, Arnaud O, Gobin P, Aymard A, George B, Cophignon J, Merland JJ: Giant intracranial aneurysm: Elective endovascular treatment using metallic coils. *Neurochirurgie* 38: 18-26, 1992.
2. Casasco AE, Aymard A, Gobin YP, Houdart E, Rogopoulos A, George B, Hodes JE, Cophignon J, Merland JJ: Selective endovascular treatment of 71 intracranial aneurysms with platinum coils. *J Neurosurg* 79:3-10, 1993.
3. Dawson RC, Krisht AF, Barrow DL, Joseph GJ, Shengelaia GG, Bonner G: Treatment of experimental aneurysms using collagen-coated microcoils. *Neurosurgery* 36:133-140, 1995.
4. Graves VB, Partington CR, Rufenacht DA, Rappe AH, Strother CM: Treatment of carotid artery aneurysms with platinum coils: An experimental study in dogs. *AJNR Am J Neuroradiol* 11:249-252, 1990.
5. Guglielmi G, Viñuela F, Sepetka I, Macellari V: Electrothrombosis of saccular aneurysms via endovascular approach: Part 1—Electrochemical basis, technique, and experimental results. *J Neurosurg* 75:1-7, 1991.
6. Guglielmi G, Viñuela F, Dion J, Duckwiler G: Electrothrombosis of saccular aneurysms via endovascular approach: Part 2—Preliminary clinical experience. *J Neurosurg* 75:8-14, 1991.




FIGURE 4. Photomicrograph of the resected aneurysm dome. The aneurysm wall was made of dense sclerous collagen tissue without smooth muscle cells. Fresh, unorganized, intra-aneurysmal thrombus was seen on the left. Note

the lack of endothelial lining over the luminal side of the thrombus (hematoxylin and eosin; original magnification, $\times 40$).

7. Guglielmi G, Viñuela F, Duckwiler G, Dion J, Lylyk P, Berenstein A, Strother C, Graves V, Halbach V, Nichols D, Hopkins N, Ferguson R, Sepetka I: Endovascular treatment of posterior circulation aneurysms by electrothrombosis using electrically detachable coils. *J Neurosurg* 77:515-524, 1992.
8. Gurian JH, Martin NA, King WA, Duckwiler GR, Guglielmi G, Viñuela F: Neurosurgical management of cerebral aneurysms following unsuccessful or incomplete endovascular embolization. *J Neurosurg* 83:843-853, 1995.
9. Knuckey NW, Haas R, Jenkins R, Epstein MH: Thrombosis of difficult intracranial aneurysms by the endovascular placement of platinum-Dacron microcoils. *J Neurosurg* 77:43-50, 1992.
10. Kwan ES, Heilman CB, Roth PA: Endovascular packing of carotid bifurcation aneurysm with polyester fiber-coated platinum coils in a rabbit model. *AJNR Am J Neuroradiol* 14:323-333, 1993.
11. Kwan ESK, Heilman CB, Shucart WA: Enlargement of basilar artery aneurysms following balloon occlusion: "Water-hammer effect"—Report of two cases. *J Neurosurg* 75:963-968, 1991.
12. Litofsky NS, Viñuela F, Giannotta SL: Progressive visual loss after electrothrombosis treatment of a giant intracranial aneurysm: Case report. *Neurosurgery* 34:548-551, 1994.
13. Molyneux AJ, Ellison DW, Morris J, Byrne J: Histological findings in giant aneurysms treated with Guglielmi detachable coils: Report of two cases with autopsy correlation. *J Neurosurg* 83:129-132, 1995.
14. Zubillaga AF, Guglielmi G, Viñuela F, Duckwiler GR: Endovascular occlusion of intracranial aneurysms with electrically detachable coils: Correlation of aneurysm neck size and treatment results. *AJNR Am J Neuroradiol* 15: 815-820, 1994.

COMMENTS

The authors concisely report a 60-year-old patient with what seems, angiographically, to be a partially thrombotic anterior communicating aneurysm of large but not giant size. This lesion was symptomatic although unruptured. The patient underwent two embolization procedures, which resulted in virtually complete obliteration of the aneurysm, as revealed by angiography. The lesion recurred progressively over the next 18 months, and a surgical procedure was then performed and complicated by intimal and aneurysm wall thickening, leading to the occlusion of an efferent branch.

Guglielmi detachable coil (GDC) embolization is now in widespread use and seems to be expanding in terms of frequency and in terms of specific indications in the endovascular radiological community. Neurosurgeons are en-

countering the complication reported in this article with increased frequency. Intraluminal thrombosis is a concept that is not new. Drake and Mullan (personal communication) applied this approach via open craniotomy several decades ago, only to note an alarming tendency toward aneurysm recurrence in the ensuing months. That experience and more recent experience with detachable balloons and GDCs bring into question whether this strategy is fundamentally sound. If one has an oval defect in an arterial wall together with a hemodynamic predisposition toward aneurysmal growth, can thrombosis of that sac, with or without endothelialization, provide long-term protection against recurrence?

Once an aneurysm recurs, the surgical treatment can be extremely complicated. In my experience, when an aneurysm is incompletely treated and surgery is then performed in the ensuing days or weeks, the residual filling is intimately associated with the neck of the aneurysm and surgical treatment is straightforward. If, however, months have passed, the fibrotic reaction to the coils renders reconstruction of the neck a significant problem.

It should be kept in mind that this particular patient with a symptomatic lesion could have been treated with a single surgical procedure with expected morbidity in the range of 5 to 10%. The reported strategy resulted in at least six angiograms, two embolization procedures that likely required separate anesthetics, an open craniotomy, postoperative neurological deficit, 1 month in the acute care hospital, and extended rehabilitation care. The financial, as well as neurological, impact of this strategy should not be overlooked.

It is my opinion that the existing literature regarding the long-term stability of GDCs does not support this technique as an alternate strategy comparable with direct surgical clipping when surgery is deemed feasible by an experienced neurosurgeon. On the other hand, the technique seems to be extremely useful in complicated situations. An outstanding indication is in the poor-grade patient after subarachnoid hemorrhage, in whom delayed surgery would be a reasonable consider-

ation. Such a patient can be treated quickly with GDCs, minimizing the rebleeding risk and allowing appropriate care should vasospasm develop. If recurrence is demonstrated on subsequent studies and the patient seems to be recovering from his or her illness, a craniotomy could be performed at that time. An alternative patient group would be comprised of those individuals who, because of associated medical conditions, are not thought to be good operative candidates. On the other hand, if general anesthesia is required for GDC placement, much of the "minimally-invasive" benefit of interventional therapy is lost. In the clinical environments with which I am familiar, the anesthesiologist has better control of the patient if cardiac or pulmonary complications should develop in the operative suite as opposed to the interventional radiology suite.

This is obviously an exciting new technological development that justifies careful study. Only if careful follow-up of patients so treated demonstrates long-term "cure" can endovascular therapy be considered an effective alternative strategy to precise surgical clipping. It is well known that imprecise surgical clipping often leads to significant aneurysm recurrence, and treatment of these recurrences carries increased risk to the patient. In my opinion, only when an experienced cerebrovascular surgeon thinks that the attendant neurological risks to the patient are inordinately high should primary endovascular therapy be initiated.

H. Hunt Barger
Chicago, Illinois

Unfortunately, this is a highly representative case of the problems that can arise after successful GDC embolization. Because coils do not incite endothelial repair, aneurysms that grow in a direction line with the normal direction of arterial blood flow have a high tendency to recur after successful coil embolization. It seems that only aneurysms that are at a right angle to the parent vessel have good results with long-term obliteration. Aneurysms at the basilar apex and at the ophthalmic level of the carotid

artery recur with notorious frequency, even after complete embolization.

The difficulty with surgical treatment of a recurrent aneurysm is also well represented by this case report. When the coils are present near the neck region of the aneurysm, it is almost impossible to clip the aneurysm without opening the dome and removing the obstructing coils. This type of maneuver greatly increases the risk of surgical clipping, as compared to clipping an aneurysm that has no intraluminal coil mass. Intimal dissection, air embolus, and intralumi-

nal thrombosis are going to be much more common in patients who are operated on with preexisting coil masses than with patients who are operated on primarily.

The introduction of GDC embolization is a major advance and a significant part of our armamentarium in dealing with intracranial aneurysms. However, because of the problems represented by this case report, aneurysms that are surgically clippable should be surgically treated unless there are major medical contraindications. Coil embolization

should be reserved for aneurysms that have been explored and found to have significant contraindications to clipping or in patients with medical or neurological problems that preclude safe surgical procedures. Aneurysm clipping is a proven technology with well-known long-term efficacy. This technique needs to be offered to all appropriate patients. Coil embolization should be reserved for aneurysm with significant technical limitations to safe clipping.

Robert A. Solomon
New York, New York

ANNOUNCEMENT

International Society for the History of the Neurosciences

The International Society for the History of the Neurosciences, Inc., was founded by a group of neurohistorians at a meeting in Montreal, Canada, in May 1995. Its mission is to promote the history of the neurosciences by improving communication and education among neurohistorians and to improve the quality and quantity of work in the field. We hope to attract participants from all of the clinical and experimental neurosciences, as well as professional historians and others with related interests. There will be annual meetings (usually in the spring), which will be held in alternate years in North America and on another continent (usually Europe). The Society's official publication is the *Journal of the History of the Neurosciences*, whose founder and continuing editor is F. Clifford Rose, M.D., of the Neurological Centre, London, England.

The founding officers of the Society include President Stanley Finger, Ph.D. (Psychology/Neural Science, Washington University, St Louis, MO); President-Elect, Peter Koehler, M.D. (Neurology, De Wever Hospital, Heerlen, The Netherlands); Duane Haines, Ph.D., Secretary (address below); and Treasurer, Samuel Greenblatt, M.D. (Neurosurgery, Brown University, Pawtucket, RI). Annual dues of \$95.00 (U.S. dollars) include a subscription to the *Journal*, published by Swets & Zeitlinger of Lisse, The Netherlands. For information and membership application forms, please contact Duane Haines, Secretary ISHN, Department of Anatomy, University of Mississippi Medical Center, 2500 North State Street, Jackson, MS 39216-4505. Tel: 601/984-1640. Fax: 601/984-1655. e-mail: dehaines@fiona.usmed.edu.