

Brain Infarction Caused by Syphilitic Aortic Aneurysm A Case Report

Hiroshi Nakane, M.D.*†
Yasushi Okada, M.D.*†
Setsuro Ibayashi, M.D.†
Seizo Sadoshima, M.D., F.A.C.A.†
and Masatoshi Fujishima, M.D.†

FUKUOKA CITY, JAPAN

ABSTRACT

Neurosyphilis often develops brain infarction. Recently, the authors experienced a case of brain infarction caused by syphilitic aneurysm on the thoracic aorta, and its clinical significance is reported. A seventy-eight-year-old woman with strongly positive serologic tests for syphilis suddenly developed global aphasia and right hemiplegia. Brain computed tomography (CT) showed a large brain infarction in the left middle cerebral artery territory. A huge aneurysm of the ascending aorta eroded the sternum and the second and third ribs. The left common carotid artery was completely compressed by the aneurysm, and blood flow was not demonstrated on enhanced CT. A cerebrospinal fluid examination revealed normal cell counts, and the titer of a syphilis test was very low. She did not have any arrhythmia, ischemic heart disease, or valvular heart disease as an embolic source. Brain infarction may be developed by pressure of an aortic aneurysm on the left common carotid artery. They recommend consideration of syphilis as an etiology of brain infarction when luetic patients are seen in old age.

From the *Cerebrovascular Disease Clinic and Division of Clinical Research National Kyushu Medical Center Hospital, and the †Second Department of Internal Medicine, Faculty of Medicine, Kyushu University, Fukuoka City, Japan.

©1996 Westminister Publications, Inc., 708 Glen Cove Avenue, Glen Head, NY 11545, U.S.A.

Introduction

Recent chemotherapy has extremely reduced the incidence of syphilis, and we rarely see patients with neurosyphilis or syphilitic aortic aneurysm. Neurosyphilis is known to accompany brain infarction due to stenosis or occlusion of intracranial arteries, ie, syphilitic arteritis, but a case with brain infarction by syphilitic aneurysm is very rare. We herein reported a case of huge syphilitic aortic aneurysm that caused brain infarction.

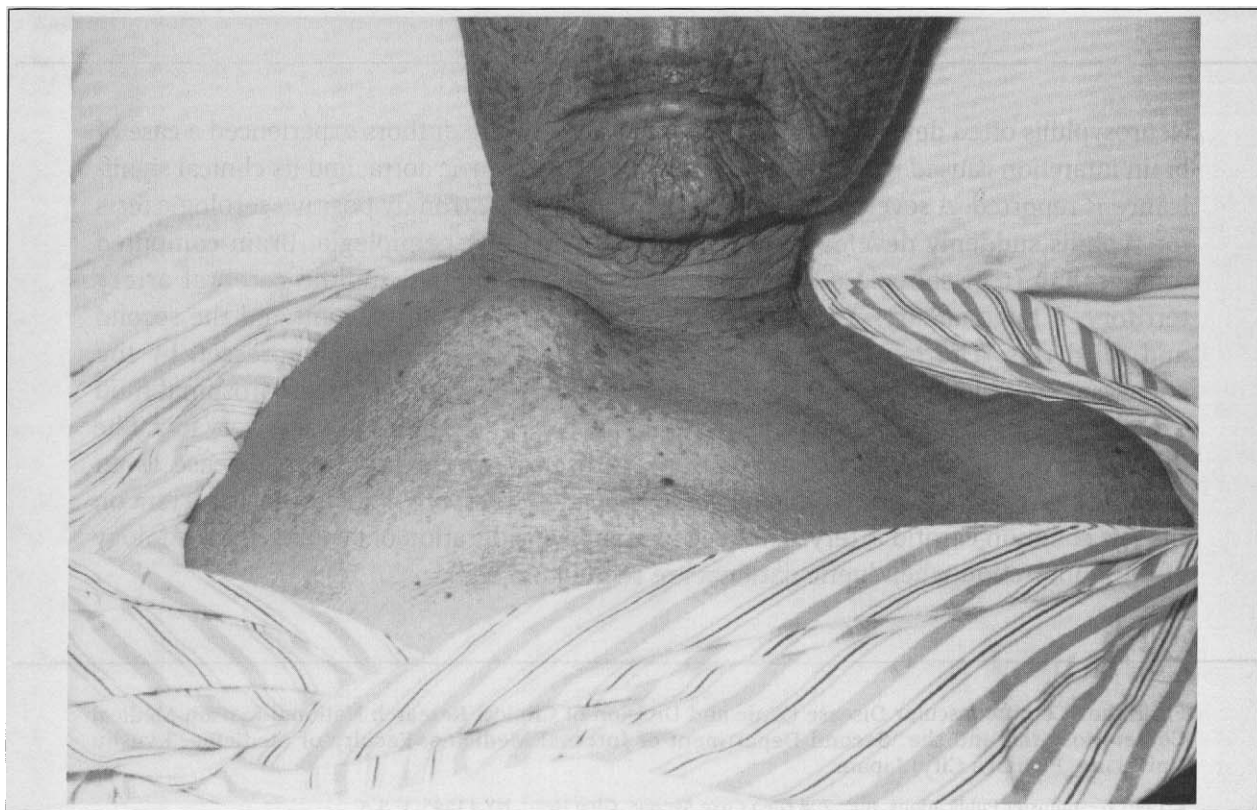Case Report

In the spring of 1991, a seventy-eight-year-old woman first noticed a small, elastic, hard tumor, that had pulsation without pain on the right upper chest, but she did not have any medical examinations. During the next three years, the tumor increased in size, but no pain or erosion of the skin were observed. On February 22, 1994, at 6 AM, her daughter found that the patient devel-

oped right hemiparesis and severe dysarthria. She was admitted to the hospital on the same day with the diagnosis of brain infarction. Six days after the first ictus, February 28 during hospitalization, she suddenly fell into coma. Although her consciousness gradually recovered in a few days, right hemiplegia and global aphasia were unchanged. On July 16, she transferred to our hospital for further evaluation of the neurologic disorders and tumor on the right chest.

On physical examination, blood pressure was 144/100 mmHg and pulse rate was 80/minute and regular on admission. There were no abnormalities in the respiratory and heart sounds. A round and pulsatile mass was palpated on the right edge of the sternum just below right clavicle. The surface was smooth and the margin was sharp. The size of the tumor was 4×5 cm in diameter and 1 cm in height (Figure 1). Her consciousness was clear with global aphasia. She was right hemiplegic and had hypesthesia on the right. The pupils were round and isocoric, and

Figure 1. A huge pulsatile mass protruded from the right upper chest. The surface was smooth, 4×5 cm in diameter, and 1 cm in height.



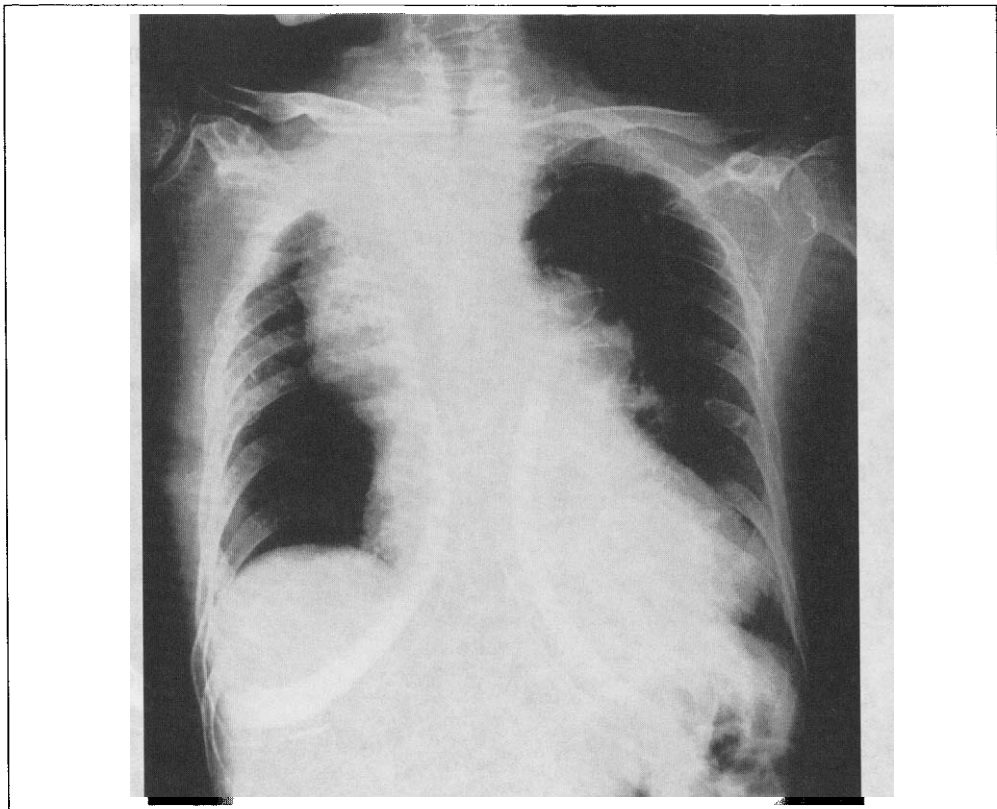
light reflex was prompt. Deep tendon hyper-reflex and Babinski's sign were positive on her right side.

Laboratory data of peripheral blood cell counts and serum chemistry demonstrated no abnormalities. Serologic test for syphilis was positive (Rapid Plasma Reagin Card Test [RPR] 128x, Treponema Pallidum Hemagglutination Test [TPHA] 40,960x: TPHA IgM negative, IgG 128x and Fluorescent Treponemal Antibody Absorption Test [FTA-ABS] positive). The examination of cerebrospinal fluid (CSF) revealed normal cell counts and protein content. The CSF test for syphilis was positive, but the titer was low (RPR negative, TPHA 4x, TPHA IgM negative, IgG 4x, FTA-ABS positive).

A chest x-ray film demonstrated a marked enlargement of the upper mediastinum to the right (Figure 2). The chest computed tomography (CT) with contrast enhancement revealed a huge saccular aortic aneurysm in the ascending aorta extending to the innominate artery with occluding

thrombus in the lumen (Figure 3). This aneurysm had grown forward and destroyed the upper sternum and the second and third ribs. Furthermore, the aneurysm involved the aortic arch and compressed the left common carotid artery (CCA). The contrast medium was not visible in the left CCA from its origin. The lumen of the left CCA was packed by soft-density material the same as that of the aortic aneurysm. This suggested that the left CCA was filled with organizing thrombus and occluded from the origin. A brain CT showed a widespread low-density area in the territory of the left middle cerebral artery (Figure 4). Magnetic resonance angiography (MRA) did not demonstrate any stenosis of segmental constriction or occlusion of any other intracranial arteries except for the left internal carotid artery (ICA) (Figure 5). The cervical pulsed Doppler echo demonstrated that the left CCA was packed with thrombus and there was no flow in it. Atherosclerotic change of the left ICA and external carotid artery was not evident.

Figure 2. The chest x-ray film showed the enlargement of the right upper mediastinum and cardiomegaly.



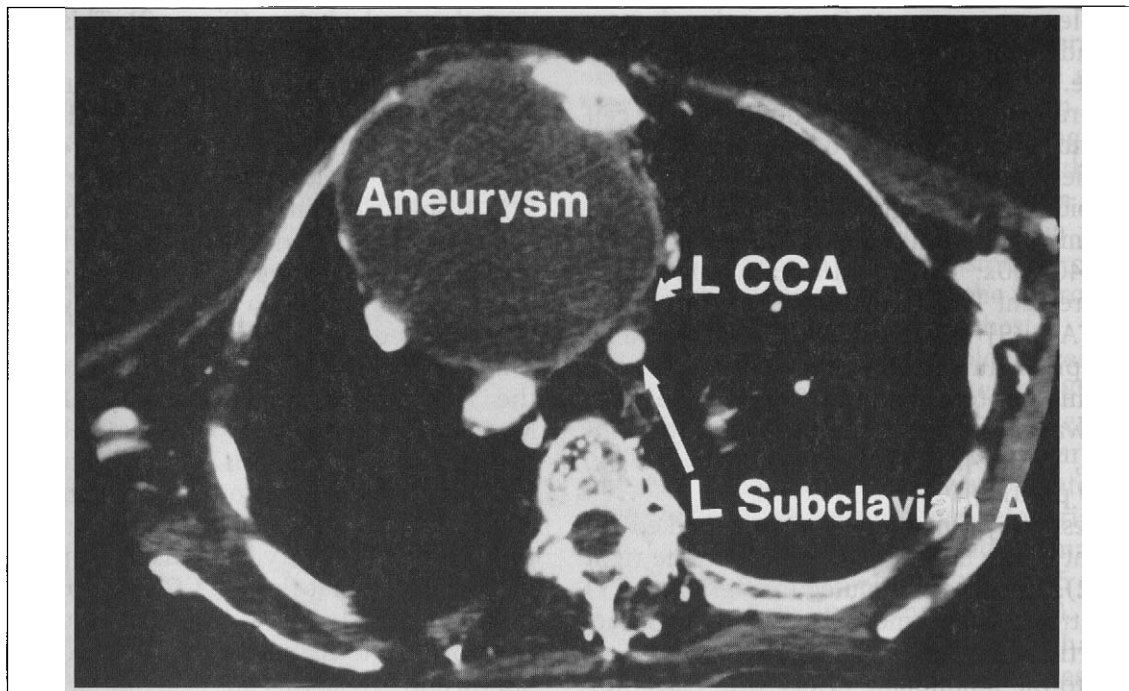
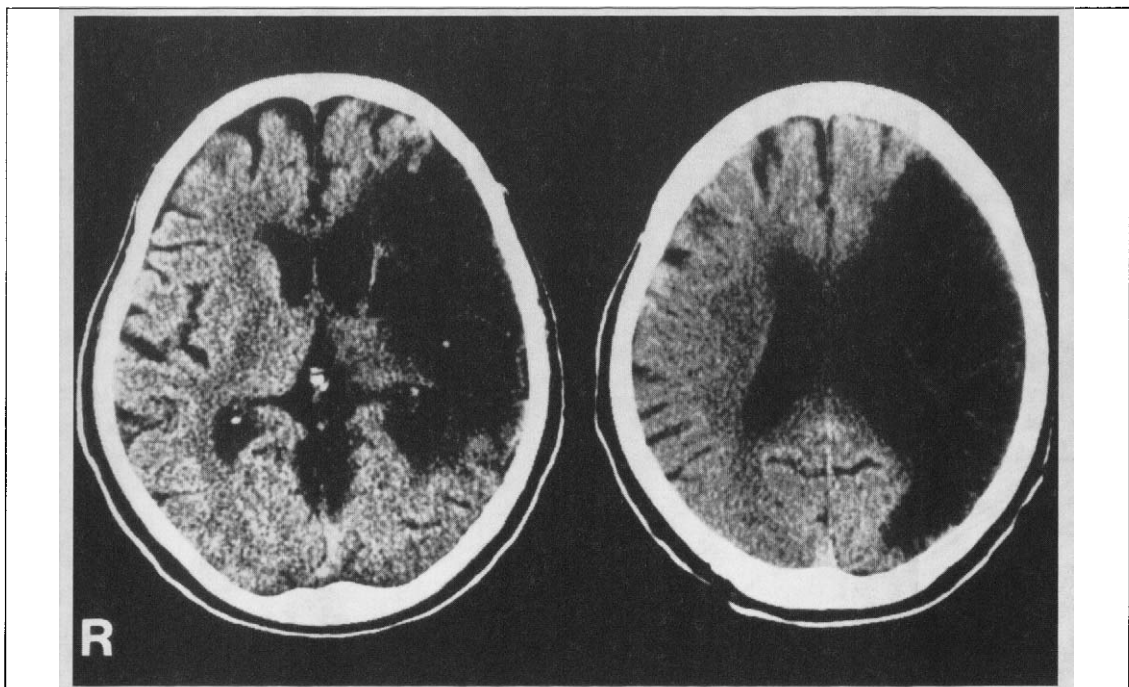


Figure 3. The chest computed tomography enhanced with contrast medium showed a huge saccular aortic aneurysm filled with thrombus. The aneurysm destroyed the sternum and ribs, compressing the proximal part of the left common carotid artery. The left common carotid artery was occluded with thrombus, and blood flow was not detected. L CCA, left common carotid artery; L subclavian A, left subclavian artery.

Figure 4. Brain computed tomography on admission showed a widespread low-density area in the left middle cerebral artery territory.



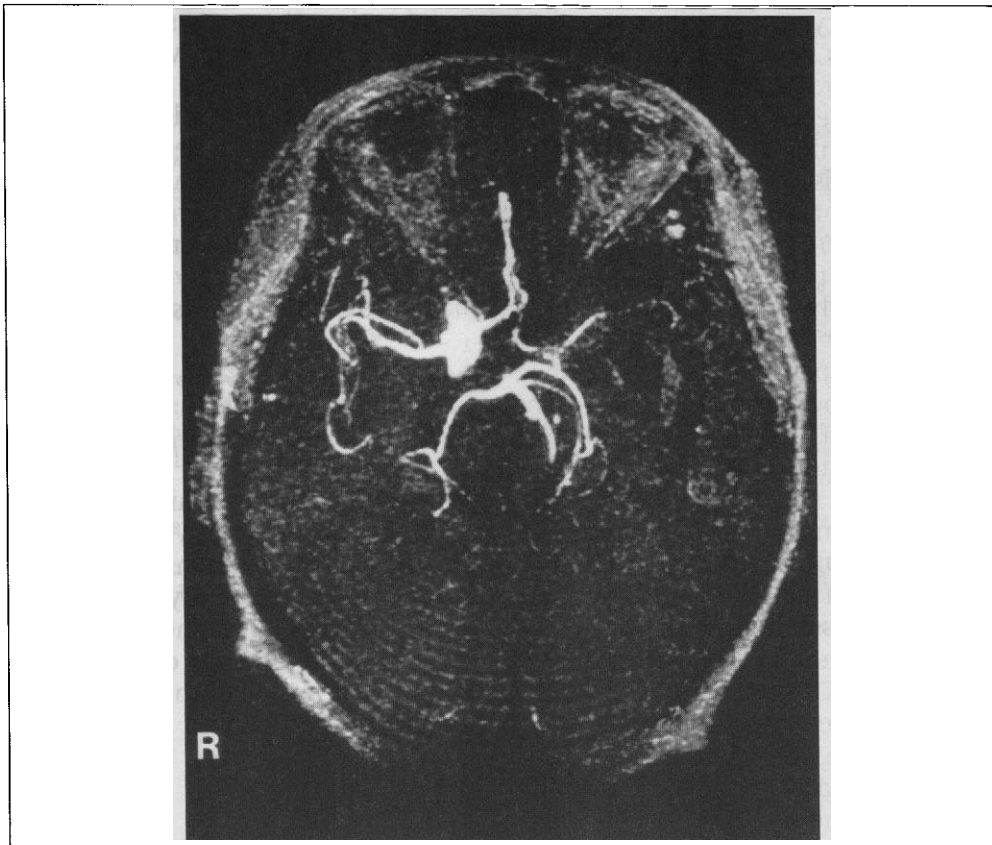


Figure 5. Magnetic resonance angiography in axial view demonstrated the occlusion of the left internal carotid artery. The other intracranial arteries except for left internal carotid artery did not show segmental occlusion or marked stenosis.

We speculated that her brain infarction may have been caused by the left CCA occlusion on the basis of syphilitic aortitis. We started to administer benzylpenicillin benzathine 2,400,000 units per day orally for thirty days. The titer of the serum syphilis test did not change after the treatment. During the hospitalization for ninety-four days, she did not experience recurrence of ischemic stroke, and her neurologic status was not changed.

Discussion

The patient in this report had a huge aortic aneurysm on the ascending aorta. The saccular aneurysm eroded the ribs and the sternum and

protruded to the right upper chest. The characteristic of a luetic aneurysm is to expand enough to reach, compress, and erode the contiguous sternum and anterior right thoracic cage.¹ The size and structure of the aneurysm of our patient is compatible with luetic aneurysm. Furthermore, she showed a markedly high titer for the serum syphilis test. The titer for RPR was 128x, TPHA was 40,960x and, FTA-ABS was positive but TPHA IgM was negative. Cardiovascular complications have been observed in approximately 10% of untreated lues.¹ These are uncomplicated aortitis, aortic aneurysm, valvulitis with aortic regurgitation, and coronary ostial stenosis.² These cardiovascular diseases may cause cerebrovascular accidents, but brain infarction is very rare as a cardiovascular complications caused by syphilis.

The most common type of syphilitic vasculitis with brain infarction is neurosyphilis. Less than 10% of patients with seropositive syphilis develop neurosyphilis.³ Merritt et al⁴ described the characteristics of neurosyphilis as follows: asymptomatic (31%), meningitis (6%), vascular syphilis (10%), tabes dorsalis or general paresis (42%), and miscellaneous (11%). In another study, 8.8% of 2019 neurosyphilis patients had meningitis, 19% had meningovascular disease and more than 70% had parenchymal brain disease.⁵

Meningovascular syphilis frequently develops stroke owing to the occlusion of intracranial arteries. Two types of syphilitic arteritis are proposed. Heubner arteritis affects large and medium-sized arteries and is characterized by fibroblastic proliferation of the intima, thinning of the media, and fibrous and inflammatory changes of the adventitia. The other is Nissl arteritis, which affects small vessels and is characterized by the proliferation of endothelial and adventitial cells.^{6,7} The CT findings in neurosyphilis consist of small infarcts affecting both the gray and white matter in the multiple arterial distributions.⁸ In the present case, first, the CSF syphilis test was positive, but the titer was very low and the cell counts were within normal limits. Second, on MRA there were no characteristic neurosyphilitic changes in intracranial arteries, such as segmental constriction and occlusion.⁸ Third, the CT findings were not small infarcts but large and widespread infarcts in the middle cerebral artery territory. Thus, we reasonably assume that in our case, neurosyphilis may not have been a potential cause of brain infarction.

There have been few reports on a syphilitic aneurysm developing into brain infarction. Iemura et al⁹ reported a case of brain infarction associated with syphilitic aneurysm, in which they speculated that atrial fibrillation or ulceration of aorta may have been possible embolic sources. On the other hand, in our case, the main mechanism of the brain infarction may have been the saccular syphilitic aneurysm that markedly enlarged and completely occluded the left CCA. The chest CT revealed that a huge and saccular aortic aneurysm compressed the left CCA, and contrast medium was not visible in its lumen. Thus, blood flow through the left CCA seemed to be severely obstructed. The other possible mechanism is embolic infarction. The CT findings in this case were a widespread low-density area with clear margin. These findings are rather compatible with embol-

ic infarction. However, she did not have arrhythmia, atrial fibrillation, valvular heart disease, or ischemic heart disease. So we assume that brain embolism from heart disease can be ruled out. Furthermore, the chest CT, cervical pulsed Doppler echo, and MRA findings did not demonstrate severe atherosclerotic or thrombotic change of cervical arteries. Considering these findings, we assumed that artery-to-artery embolism may be impossible in this case.

Conclusion

We report a case of brain infarction caused by a syphilitic aortic aneurysm protruding from the right upper chest. Brain infarction may have developed by direct aneurysmal compression of the carotid artery. We should consider vascular syphilis as the etiology of an ischemic complication when we see the patients with aortic aneurysm and syphilis.

Acknowledgments

We thank Akira Kawashima, M.D., for his helpful advice on the radiographic examination.

Hiroshi Nakane, M.D.
Second Department of Internal Medicine
Faculty of Medicine, Kyushu University
Maidashi 3-1-1, Higashi-ku
Fukuoka City, 812 Japan

References

1. Eagle KA, de Sanctis RW: Disease of aorta. Cardiovascular syphilis. In: *Heart Disease, A Textbook of Cardiovascular Medicine*, ed. by Braunwald E. Philadelphia: WB Saunders, 1992, pp 1528-1557.
2. Heggtveit HA: Syphilitic aortitis. A clinicopathologic autopsy study of 100 cases, 1950 to 1960. *Circulation* 29:346-355, 1964.
3. Dalal PM, Dalal KP: Cerebrovascular manifestations of infectious disease. In: *Handbook of Clinical Neurology*, vol. 11: Vascular Disease, part III, ed. by Toole JF. Amsterdam: Elsevier, 1989, pp 411-441.
4. Merritt HH, Adams RD, Solomon H: *Neurosyphilis*. New York: Oxford University Press, 1946, pp 62-66.
5. Burke JM, Schaberg DR: Neurosyphilis in the antibiotics era. *Neurology* 35:1368-1371, 1985.
6. Harriman DGF: Bacterial infections of the central nervous system. In: *Greenfield's Neuropathology*, ed. by Blackwood W, Dorsellis JAN. London: Edward Arnold, 1976, pp 253-256.
7. Vatz K, Scheibel R, Keiffer S, et al: Neurosyphilis and diffuse cerebral angiography: A case report. *Neurology* 24:472-476, 1974.
8. Holland BA, Perrett LV, Mills CM: Meningovascular syphilis: CT and MR findings. *Radiology* 158:439-442, 1986.
9. Iemura J, Yamada T, Ueda M, et al: Surgical treatment of syphilitic ascending aortic aneurysm: A case report. *Kyobu-Geka* 43:908-911, 1990.