

L. Picard
S. Bracard
S. Lehéricy
R. Anxionnat
S. Miyachi
E. Prada
A. Per
D. Burdin
J. Auque
J. C. Marchal

Endovascular occlusion of intracranial aneurysms of the posterior circulation: comparison of balloons, free coils and detachable coils in 38 patients

Received: 15 January 1995
Accepted: 25 January 1995

L. Picard (✉) · S. Bracard · R. Anxionnat ·
S. Miyachi · E. Prada
Department of Diagnostic and
Therapeutic Neuroradiology,
C. H. U. Nancy, Hôpital Saint Julien,
F-54035 Nancy, France

S. Lehéricy
Department of Radiology,
Hôpital Beaujon,
100 Bd du Général Leclerc,
F-92110 Clichy, France

A. Per · D. Burdin
Department of Anaesthesiology,
Hôpital Saint Julien, Nancy, France

J. Auque · J. C. Marchal
Department of Neurosurgery,
Hôpital Saint Julien, Nancy, France

Abstract We treated 38 patients with 39 aneurysms of the posterior circulation by an endovascular technique using balloons, free coils or Guglielmi detachable coils (GDC) from 1986 to May 1993. The patients ranged in age from 10 to 71 years. Subarachnoid haemorrhage was the most frequent presentation (29 patients), followed by mass effect (5 patients) and epilepsy (2 patients). Treatment consisted of embolisation of the aneurysm with preservation of the parent vessel (in 29) or occlusion of the parent vessel (in 5). Multiple procedures were performed in 12 patients (32%, maximum 3 embolisations, total 17 treatments), because of incomplete initial aneurysm occlusion (in 8 cases) or re-opening of the aneurysm (in 9). Treatment could not be achieved in 5 patients. Good to excellent aneurysm occlusion was obtained in 28 patients (72%). Little or no neurological impairment occurred in 31 patients (82%). Complications related to treatment (11 patients, 29%) included 4 cases of transient cerebral ischaemia, 7 of

stroke resulting in minimal neurological impairment (in 5), severe impairment (in 1) and one death. There were 6 patients who died, of rebleeding from the same aneurysm (2), basilar stroke (1) and unrelated causes (3). Comparison of the different occlusion techniques showed that the best angiographic results were obtained with balloons (good to excellent aneurysm occlusion was obtained in 17 of 22 patients treated) and the GDC (12 of 13 patients), and that less good results were given by free coils (4 of 9 patients). Complications related to treatment were fewest in patients treated with GDC (1 of 16 treatments, including multiple procedures) or free coils (2 of 12 treatments) and were more frequent with balloons (6 of 27 treatments). All five treatment failures occurred with balloon embolisation, whereas treatment was possible in all cases treated with free coils or GDC.

Key words Aneurysm, intracranial · Embolisation

Introduction

Aneurysms of the posterior circulation represent 5–10% of intracranial aneurysms. They rupture in less than 1% of cases, and cause subarachnoid haemorrhage. Surgical treatment has high morbidity, mortality rates ranging from 16% to over 50% [1–4]. Endovas-

cular treatment has proved a reliable alternative to surgery [5–9]. The first report of intravascular embolisation of intracranial aneurysm involved the use of detachable balloons [10]. This technique has been developed [11–13], and other embolisation materials have been suggested, such as free [14–18] or more recently detachable coils (GDC) [19]. Few studies have evaluated the effi-

Table 1 Characteristics of the aneurysms

Number		39
Size	Small	27
	Large	8
	Giant	4
Location	Vertebral artery	7
	Posterior inferior cerebellar artery	2
	Superior cerebellar artery	1
	Basilar artery	24
	Posterior cerebral artery	5

ciency of and indications for these different treatments. We report endovascular treatment of 38 patients with 39 aneurysms of the posterior circulation over the past 8 years, using balloons, free coils or GDC, and evaluate the angiographic results, clinical outcome and complication rates of the different techniques.

Materials and methods

Patients

From 1986 to May 1993, 38 patients with 39 aneurysms were treated by intravascular embolisation. They were 16 males and 22 females, aged 10–71 years (mean age at diagnosis 45 years). The time from diagnosis to treatment varied from 1 day to 5 years. The presentation was subarachnoid haemorrhage (SAH) in 29 patients (76%), mass effect in 5 (13%) and epilepsy in 2 (5%). In the 2 remaining patients, the aneurysms were discovered incidentally during MRI for cervicobrachial neuralgia and for headache unrelated to SAH. The aneurysms were located on the intracranial vertebral artery (in 7 cases), the posterior inferior cerebellar artery (in 2), the superior cerebellar artery (in 1), the basilar artery (in 24), and the posterior cerebral artery (in 5) (Table 1). They were small (< 12 mm) in 27 cases, large (12–25 mm) in 8, and giant (> 25 mm) in 4.

The patients referred with SAH were graded according to a modified Hunt and Hess scale [20]. Of the 29 patients, 4 were grade I, 13 grade II, 8 grade III, and 4 grades IV or V. Clinical outcome was assessed according to the Glasgow Outcome Scale (GOS) [21].

Occlusion technique

The procedures were performed under neuroleptanalgesia or general anaesthesia, when the patient was confused or had uncontrolled movements. Heparin (30 U/kg per hour) and acetylsalicylate (250 mg) were given intravenously. Digital subtraction angiography with a "roadmapping" facility was used in most cases. The embolisation material consisted of balloons (1986–1991), free coils (1991–1992) or Guglielmi detachable coils (GDC, since October 1992). For balloon, and sometimes free coil, procedures, an 8 F catheter was placed in the affected vertebral artery and a 6 F catheter in the other vertebral artery via bilateral femoral punctures. This technique was thought necessary in case a second coaxial system with a nondetachable balloon was required to reposition an embolus which had migrated. For free coil and GDC procedures, a 6 F catheter was placed in the parent vertebral artery via right femoral puncture. The coaxial system was under continuous pressure flushing to avoid clotting. The axillary approach was

used in one case. Postembolisation angiography was performed to assess the adequacy of treatment and parent vessel patency. Once embolisation was performed, the heparin was reversed by giving protamine sulphate. Control angiography was performed at about 2 weeks, 6 months and 1 year after embolisation.

Balloon embolisation

The balloons were made of latex. When uninflated, their diameter was 1.2–1.5 mm. The balloons can contain volumes of 0.15–0.8 ml and inflate to a maximum size of 9 × 18.9 mm (diameter and length).

For aneurysm embolisation the balloons were attached to a double-lumen Moret catheter, and propelled to the aneurysm by flow, with the aid of slight inflation. Up to 3 balloons were sometimes required to fill large or giant aneurysms. The balloon was placed in the aneurysm. After confirmation of obliteration of the aneurysm sac and preservation of the parent vessel, the contrast medium in the balloon was replaced by hydroxyethylmethacrylate, which solidifies in 40–60 min. The balloon was detached by applying traction to the catheter.

For vertebral artery occlusion the balloon was attached to a single-lumen catheter. The balloon was placed in the intracranial vertebral artery immediately below or at the level of the aneurysm, to preserve flow in the posterior inferior cerebellar artery. Test occlusion was performed in all patients for 30 min. Neurological status and the EEG were assessed by a clinician, collateral blood supply by angiography. When test occlusion was tolerated well and angiography showed adequate collateral supply, the balloon was detached. This was followed by placement and detachment of a second balloon immediately below the first. When the occlusion test was not tolerated, the balloon was deflated after flushing the temporarily occluded vertebral artery.

Free coil embolisation

The coils, made of platinum ranged in length from 2 to 60 mm. A microcatheter was placed into the aneurysm with the aid of a microguidewire, through the 6 F catheter. The guidewire was removed once the catheter tip was inside the aneurysm, to avoid perforation of the aneurysm. The coils were introduced into the microcatheter and into the aneurysm with the aid of a coil-pusher.

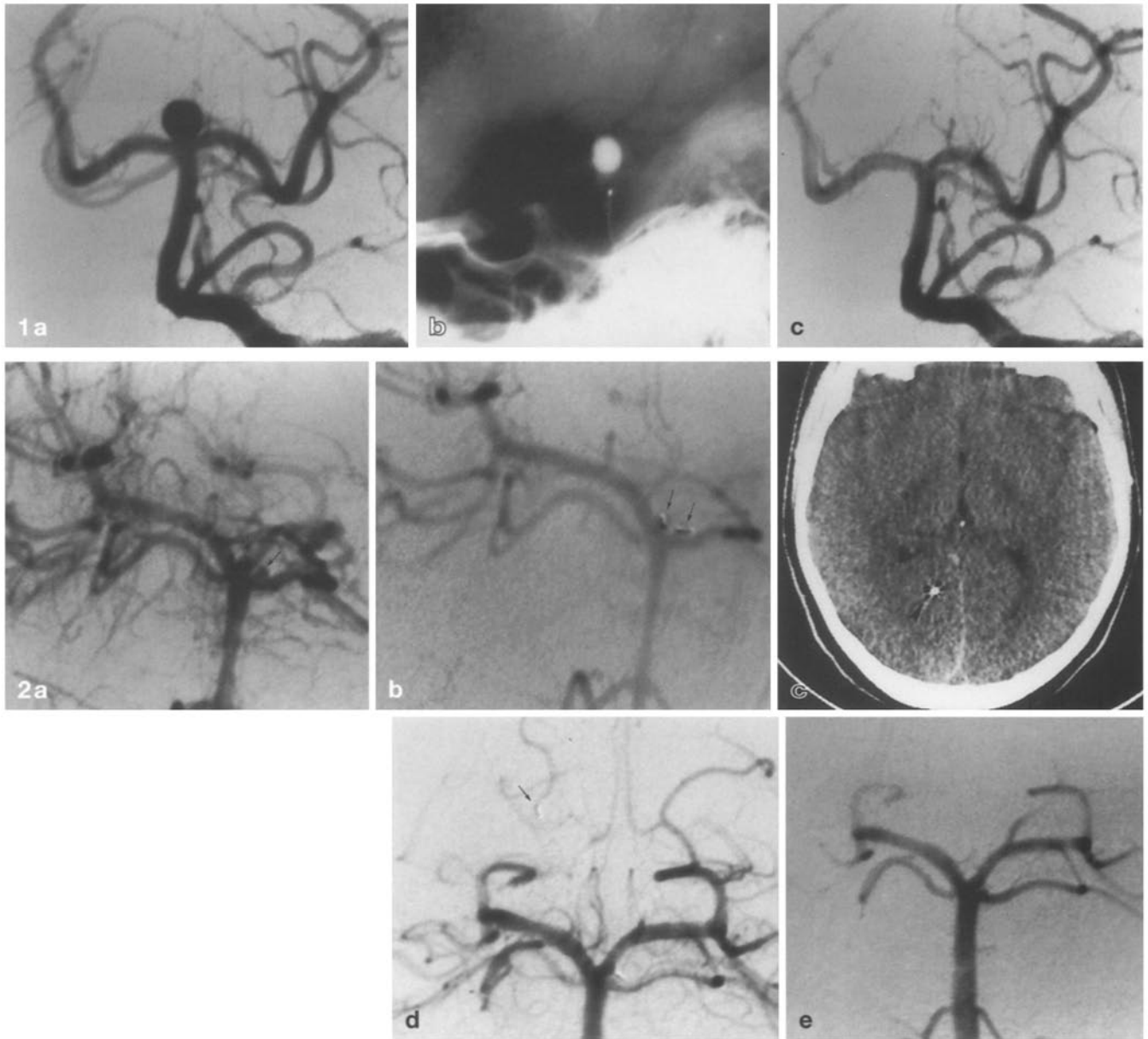
GDC embolisation

The GDC are composed of a platinum coil soldered to a stainless steel delivery wire. Their size ranged from 2 mm × 8 cm to 4 mm × 40 cm (diameter and length). A microcatheter was advanced coaxially into the aneurysm with the aid of a microguidewire. The latter was removed once the catheter tip was inside the aneurysm. The detachable coil was introduced into the microcatheter with the aid of a special introducer, and advanced into the aneurysm. If necessary, the coil can be retrieved and repositioned in a better location. As many as 8 coils were introduced into one at the same session. Electrical detachment was realised as described elsewhere, and the microcatheter was then removed.

Representative case reports

Case 1

A 59-year-old woman was referred 2 weeks after SAH (grade II). Cerebral angiography demonstrated one small distal basilar artery aneurysm (Fig. 1a). Balloon embolisation was performed 1 week



after admission. One latex balloon was introduced into the aneurysm through the left vertebral artery with the aid of a double-lumen catheter, filled with 0.11 ml hydroxyethylmethacrylate, and detached (Fig.1b). Postembolisation angiography showed complete obliteration of the aneurysm with preservation of the parent vessel (Fig.1c). Angiography 6 months later showed persistent obliteration of the aneurysm. The patient remained stable over time, in normal neurological condition.

Case 2

A 32-year-old woman presented with SAH (grade I); she was 6 months pregnant. CT showed haemorrhage in the region of the midbrain and pons. Cerebral angiography 2 days later demonstrated two small aneurysms, one at the junction of the right pos-

Fig.1a-c Case 1. **a** Left vertebral angiogram, anteroposterior, demonstrating a small distal basilar artery aneurysm. **b** Plain skull film, lateral view, showing the balloon within the aneurysm. **c** Left vertebral angiogram, anteroposterior, showing occlusion of the aneurysm

Fig.2a-e Case 2. **a** Left vertebral angiogram, oblique, demonstrating small aneurysms at the junction of the right posterior cerebral artery (PCA) and basilar artery and on the proximal left superior cerebellar artery (arrows). Note spasm of basilar artery (arrowhead). **b** Left vertebral angiogram, oblique, showing one free microcoil (2 mm long) in each aneurysm (arrows). **c** CT 2 days later, showing that one free microcoil has migrated into the right parieto-occipital region (arrowhead), with no evidence of parenchymal ischaemia. **d** Left vertebral angiogram, anteroposterior, 1 week later, showing the coil in the parieto-occipital branch of the right PCA but not occluding it (arrow). **e** Left vertebral angiogram, anteroposterior, 6 months later, demonstrating complete occlusion of the 2 aneurysms

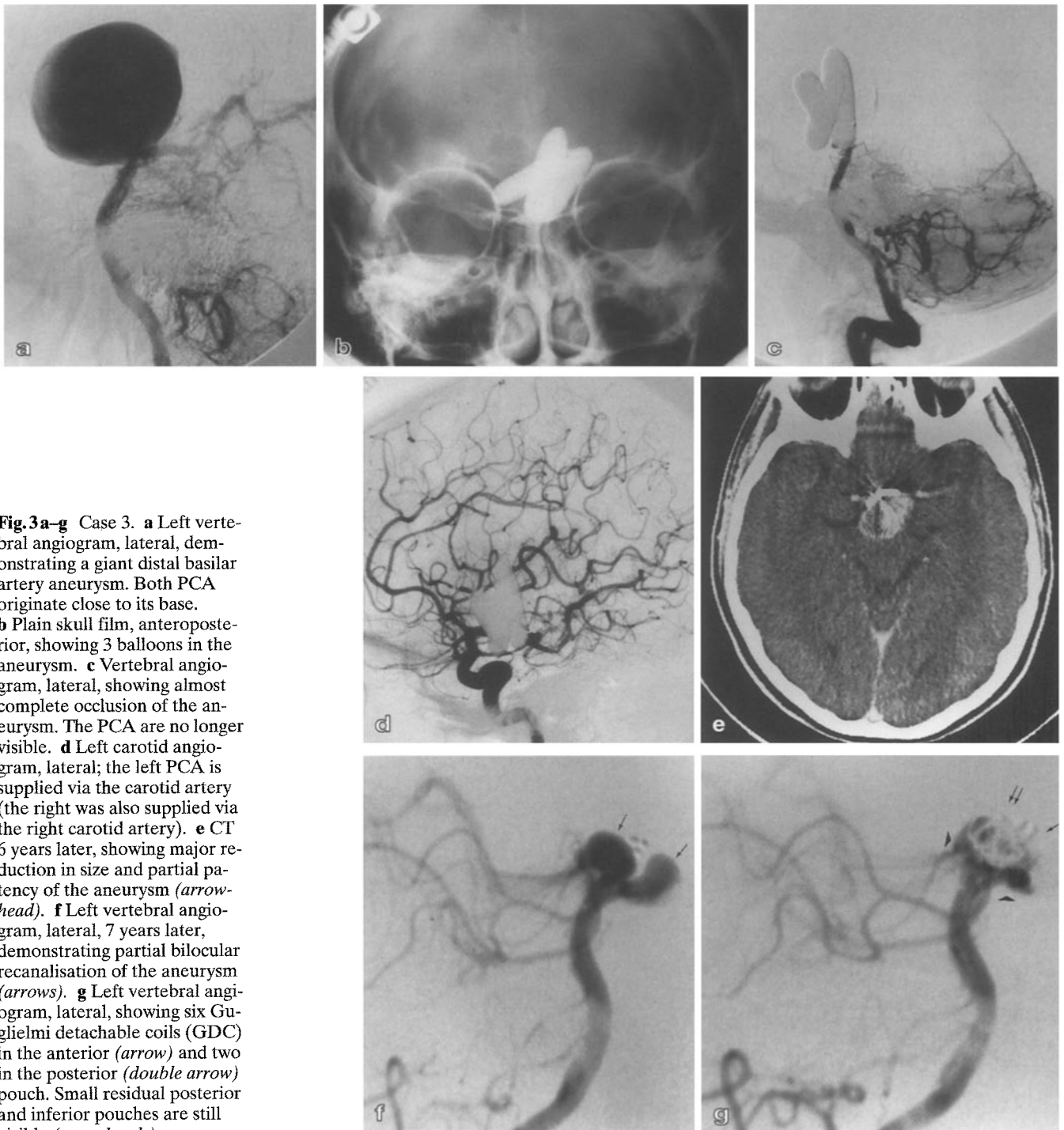
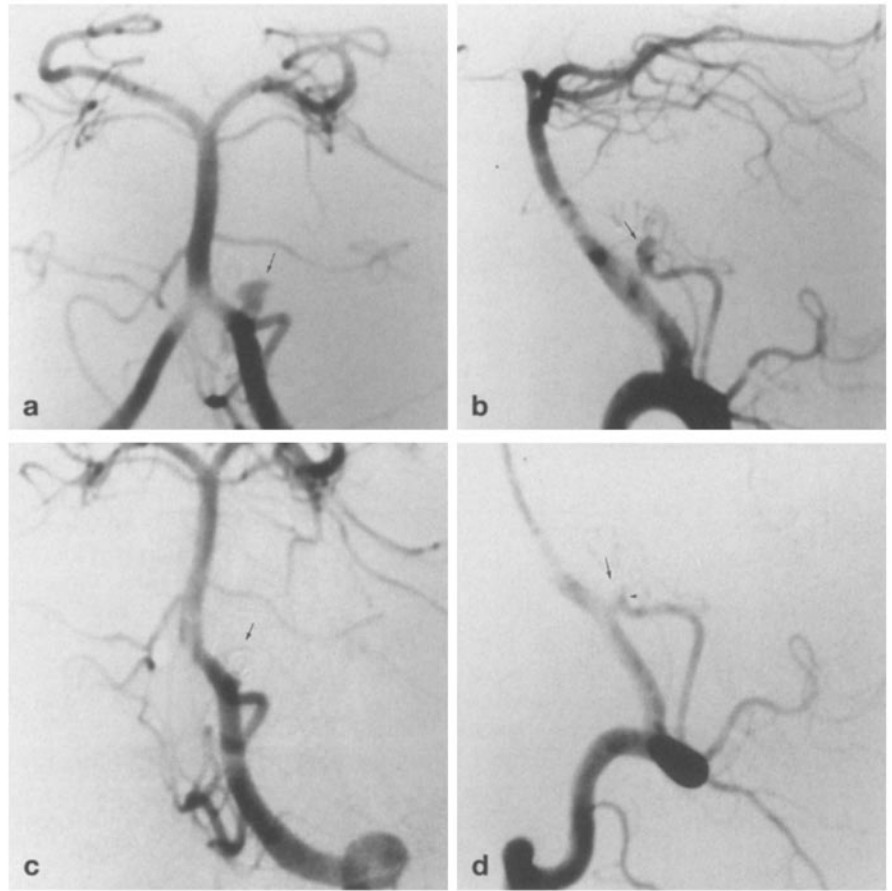


Fig. 3a-g Case 3. **a** Left vertebral angiogram, lateral, demonstrating a giant distal basilar artery aneurysm. Both PCA originate close to its base. **b** Plain skull film, anteroposterior, showing 3 balloons in the aneurysm. **c** Vertebral angiogram, lateral, showing almost complete occlusion of the aneurysm. The PCA are no longer visible. **d** Left carotid angiogram, lateral; the left PCA is supplied via the carotid artery (the right was also supplied via the right carotid artery). **e** CT 6 years later, showing major reduction in size and partial patency of the aneurysm (*arrowhead*). **f** Left vertebral angiogram, lateral, 7 years later, demonstrating partial bilocular recanalisation of the aneurysm (*arrows*). **g** Left vertebral angiogram, lateral, showing six Guglielmi detachable coils (GDC) in the anterior (*arrow*) and two in the posterior (*double arrow*) pouch. Small residual posterior and inferior pouches are still visible (*arrowheads*)

terior cerebral and basilar arteries and one on the proximal left superior cerebellar artery (Fig. 2a). Spasm of the basilar artery was present. Endovascular treatment was chosen and performed next day. A single microcoil (2 mm long) was deposited in each aneurysm resulting in subtotal occlusion, with preservation of the parent vessels (Fig. 2b). Two days later, the patient had weakness of the left arm, and CT revealed that one microcoil had migrated into

the right posterior cerebral artery, with no evidence of parenchymal ischaemia (Fig. 2c). The patient was kept under continuous heparinisation for several weeks to avoid clotting. Angiography at 1 week did not show any change in the aneurysms except that the microcoil in the right-sided aneurysm had migrated into the parieto-occipital branch of the right posterior cerebral artery without occluding it (Fig. 2d). The right arm weakness resolved and no

Fig. 4a–d Case 4. **a** Left vertebral angiogram, anteroposterior, showing a small, irregular aneurysm at the junction of the left posterior inferior cerebellar and vertebral arteries (*arrow*). **b** Lateral view, showing that the aneurysm lies on the posterior inferior cerebellar artery (*arrow*). **c** Anteroposterior view, demonstrating the detached 3.5 cm GDC in the aneurysm (*arrow*). **d** Vertebral angiogram 7 days after embolisation, lateral, showing complete occlusion of the aneurysm (*arrow*). Note loop of posterior inferior cerebellar artery at its base (*small arrowhead*)



further endovascular treatment was undertaken until delivery 2 months later. Angiography at 6 months demonstrated complete occlusion of the aneurysms (Fig. 2e). At 9 months after the procedure, the patient remained in stable neurological condition.

Case 3

A 27-year-old woman presented with headaches, progressive loss of vision over 1 year, and amenorrhea. CT showed a giant distal basilar aneurysm (Fig. 3a). The patient was referred for balloon embolisation. Three latex balloons were placed in the aneurysm, inflated with contrast medium, and detached (Fig. 3b). Transient oculomotor palsies were observed on inflation of the third balloon, which resolved when the balloon was repositioned. No further neurological complication occurred. The immediate postembolisation angiogram showed almost complete occlusion of the aneurysm and angiography at 1 week complete occlusion (Fig. 3c, d).

Following embolisation, the patient gradually recovered normal vision and menses, and her headaches disappeared. CT and angiography at 9 months showed residual filling of the aneurysm (Fig. 3e). A second embolisation was therefore performed in which one latex balloon was placed in the residual pouch. As the balloon moved out of the aneurysm each time it was inflated, the balloon was left in the aneurysm, still attached to the microcatheter. The patient was started on heparin therapy for several weeks until the microcatheter had incorporated into the vessel wall. Angiography

at 1 year demonstrated good occlusion of the aneurysm, except for a residual proximal neck.

Repeat CT showed that the aneurysm gradually decreased in size. The patient remained neurologically intact for 5 years, when CT showed that the aneurysm was slightly bigger. Angiography confirmed that a small new bilocular pouch had formed (Fig. 3f). This gradually increased in size over 1 year, when a third embolisation procedure was decided upon. We placed 6 GDC [8 mm/20 cm, 4 mm/10 cm ($\times 2$), 3 mm/8 cm ($\times 3$)] and two more (8 mm/40 cm and 8 mm/20 cm) in the anterior and posterior pouches respectively, detaching them without neurological complications (Fig. 3g). Angiography 1 week later demonstrated subtotal aneurysm occlusion, leaving a small proximal residuum. The patient remains neurologically intact.

Case 4

A 43-year-old woman was referred 10 days after SAH (grade III). Cerebral angiography demonstrated a small aneurysm of the left posterior inferior cerebellar artery (Fig. 4a, b). Treatment, performed 3 days later, consisted of introduction of one GDC (4 mm diameter) into the aneurysm (Fig. 4c). Initially, the coil was too long (10 cm), pushing the microcatheter out of the aneurysm when all of it was introduced, so it was shortened to a final length of 3.5 cm. No neurological complication occurred. The postembolisation angiogram showed subtotal occlusion of the aneurysm with preservation of the parent vessel. Angiography 1 week later dem-

Table 2 Clinical outcome

	Patients	Glasgow		Outcome	Scale	
		1	2	3	4	5
Subarachnoid haemorrhage	29					
Hunt and Hess grade						
I	4	3	1	0	0	0
II	13	10	0	0	0	3
III	8	5	2	0	0	1
IV/V	4	3	0	0	0	1
No subarachnoid haemorrhage	9	7	0	1	0	1

onstrated complete occlusion of the aneurysm (Fig. 4d). Follow-up was short (1 month), but the patient remained in stable neurological condition (GOS 1).

Results

We treated 29 aneurysms by embolisation with preservation of the parent vessel, 5 by occlusion of the parent vessel, and 5 aneurysms could not be treated. The aneurysms treated by occlusion of the parent vessel were all on the vertebral artery, and were fusiform (3) or saccular (2). In 5 patients, embolisation failed because of technical failure (2), transient oculomotor palsies on balloon inflation (1), transient angiographic vessel occlusion on balloon inflation (1), or angiographic vessel occlusion due to clotting (1). All five treatment failures occurred with attempted balloon embolisation.

Angiographic results following embolisation were excellent: complete aneurysm occlusion in 22 aneurysms (54%), good (occlusion > 90%) in 7 (18%), and incomplete (50% < occlusion < 90%) in 5 (13%). Multiple treatments were performed in 12 patients (32%): either one (5 patients) or two (7 patients) embolisations were carried out (maximum 3, total 17 repeated procedures). These were performed because of incomplete aneurysm occlusion (8) or re-opening of the aneurysm (9).

Clinical follow-up ranged from 1 month to 7 years (mean 11 months). There were 28 patients (73.7%) who recovered fully, with normal neurological status (GOS 1) over the follow-up period (Table 2); 3 patients (7.9%) had moderate neurological deficit (GOS 2), 1 (2.6%) severe neurological deficit (GOS 3) and 6 (15.8%) died (GOS 5). Of these patients, 2 died of re-bleeding from the same aneurysm, one died of a basilar artery stroke and 3 from unrelated causes (rupture of another aneurysm, rupture of the middle cerebral artery during angioplasty, and pulmonary embolism). Of 29 patients presenting with SAH, 21 (72%) had a final GOS of 1, 3 (10%) had a GOS of 2 and 5 (18%) died (Table 2).

Complications related to treatment were observed in 11 of 38 patients (29%). There were 4 patients (11%)

who had transient cerebral ischaemia during or immediately after the procedure, which resolved, and 6 (16%) who developed longer-lasting neurological complications due to strokes. Of these 6 patients, 2 had visual field deficits (one quadrantanopia and one hemianopia), one a left hemiparesis, dysarthria and diplopia; one patient was severely impaired (left hemiplegia, mutism, diplopia), and 2 patients died from rebleeding from the same aneurysm or SAH from another aneurysm. A seventh patient suffered a stroke immediately after the procedure, of which he died a few days later. Thus, in 31 patients (82%), there was no lasting neurological deficit secondary to embolisation. Neurological complications were twice as frequent when vasospasm was present.

The different embolisation procedures are analysed in Tables 3 and 4. The best angiographic results were obtained with balloons (complete or good aneurysm exclusion in 20 of 27 treatments) and GDC (15 of 16 treatments) (Table 3). Angiographic results were less good with free coil embolisation (6 of 12 treatments). Re-opening of aneurysms after embolisation was more frequent with balloons (4) or free coils (4) than with GDC (1). Follow-up angiography showed that intra-aneurysmal thrombosis progressed with time in 3 patients treated with GDC, one with free coils and 2 with balloons. The GOS was lower with balloon treatment, with a total of 5 deaths in this series (Table 4). With balloon embolisation, 14 of 21 patients had a final GOS of 1, as compared to the free coils (6 of 9) and GDC (11 of 13). The lowest rate of neurological complications related to treatment was in patients treated with GDC (1 transient deficit in 16 treatments) or free coils (2 transient and 1 lasting deficits in 12 treatments); they were more frequent when balloons were used (1 transient and 5 lasting deficits and 1 death in 27 treatments) (Table 3).

Discussion

In this series, excellent or good aneurysm occlusion was obtained in 72% of cases. Of 38 patients, 31 (82%) had little (GOS 2) or no (GOS 1) neurological impairment. The overall morbidity and mortality rates were 10.5%

Table 3 Angiographic results and complications of the different techniques

		Treatment failure	Angiographic results				Recanalisation	Neurological complications		
			100 %	> 90 %	50 %–90 %	< 50 %		None	Morbidity	Death
Balloons										
Patients ^a	22	5	15	2	0	0		15	6	1
Treatments ^a	27	6	16	4	1	0	4	20	6	1
Free coils										
Patients	9	0	1	3	2	3		6	3	0
Treatments	12	0	1	5	3	3	4	9	3	0
GDC										
Patients	13	0	6	6	1	0		12	1	0
Treatments	16	0	6	9	1	0	1	15	1	0

^a Some patients were treated using 2 or even 3 different methods on more than 1 occasion

Table 4 Clinical outcome obtained with the different techniques

Treatment	Glasgow		Outcome	Scale		Total
	1	2	3	4	5	
Balloons	14	1	1	0	5	22
Free coils	6	2	0	0	1	9
GDC	11	1	0	0	1	13

and 15.8 % respectively. Previous reports of posterior circulation aneurysms treated by surgery have indicated morbidity and mortality rates ranging from 25 % to 50 % [1, 3, 4]. In the largest series, reported by Peerless and Drake [2], morbidity and mortality rates varied with the size of the aneurysm, ranging from 13 % for small aneurysms to 25 % for large aneurysms and 42 % for giant aneurysms. In our series, no correlation was found between the size of the aneurysm and outcome.

Rebleeding occurred in 3 of our patients, 1–3 weeks after embolisation; 2 died. In one of these patients, treatment could not be achieved, and in the other two treatment was incomplete, leading to only 70 %–80 % aneurysm occlusion. Thus, the possibility of rebleeding after subtotal occlusion remains. This underlines the need for complete aneurysm exclusion, as in previous reports of surgical [22] or endovascular series [7].

The best angiographic results were obtained with balloon embolisation (67 % of complete aneurysm occlusion), compared to GDC (46 %) or free coils (11 %). Of the 22 patients treated with balloons 16 (76 %) suffered no neurological complications related to treatment. These results are consistent with previous reports. Balloon embolisation of intracranial aneurysms was the first endovascular technique described [10]. Many others have now reported their experience [7, 9, 11–13, 23]. Higashida et al. [7] reported good or excellent angiographic results in 77 % of their 26 cases of posterior circulation aneurysm, and 17 of their 25 patients (67 %) had no immediate neurological complications related to the treatment.

In 5 of our cases, selective aneurysm occlusion was not possible, usually because of a large neck or a fusiform shape to the aneurysm. Parent vessel occlusion at or proximal to the neck was the solution of choice. When tolerated, this technique was safe (no complication was related to the procedure) and provided definitive aneurysm exclusion. Of these patients, 4 had a final GOS of 1 and one died from an unrelated cause. These results are consistent with previous studies [5]. Vertebral artery occlusion is also the only feasible treatment for fusiform aneurysms of the basilar artery [5, 10–12, 24].

All our treatment failures were related to balloon embolisation. Technical problems were mainly related to inability to navigate balloons into the aneurysm because of the characteristics of the feeding arteries (tortuosity, size too small). Other technical failures may be expected in case of aneurysms with a neck too small to allow the introduction of a deflated balloon, or too wide to prevent balloon herniation into the parent vessel [14, 25]. In addition, the small size of aneurysms may make balloon placement difficult or even impossible. Technical failures were not encountered with free coils or GDC because of the technical advances in microcatheters and steerable guide wires. The microcatheter can be directed more easily and enters smaller vessels than the catheter used for balloon embolisation. Thus, most aneurysms of the posterior circulation appear treatable with free coils or GDC. In 2 patients, balloon inflation would have occluded normal vessels arising close to the base of the aneurysms. This did not occur with GDC (although one patient who already had a stroke in the territory of the parent vessel, which was intentionally occluded), probably because GDC are softer and do not modify the shape of the aneurysm, as the balloon can do when inflated.

Free coil embolisation gave the poorest angiographic results (44 % occlusion > 90 %). Neurological complications related to treatment were comparable with those of GDC procedures and fewer than with balloons.

Free coils have been successfully used in the treatment of vein of Galen malformations [26], dural arteriovenous fistulae [27], and indirect caroticocavernous fistulae [28]. Previous reports have evaluated the treatment of intracranial aneurysms with free coils [14–18, 29]. Free coil embolisation has been suggested in selected cases, such as inability to use balloons, too small or too wide an aneurysm neck, very small [14] or ruptured aneurysms [17]. Free coils in an aneurysm may exert less pressure on its walls, than balloons and conform better to its shape. They can be used in small aneurysms in which balloon therapy would be impossible (case 2). However, a potential risk of free coil embolisation is extrusion of the coil into the parent vessel and migration (2 cases in this series). Once the coil is out of the aneurysm, it is difficult to retrieve. In our series, the risk of coil migration was the principal factor which limited the number of coils which could be introduced into the aneurysm. In 5 of the 9 patients treated with free coils, embolisation had to be completed with balloons or GDC. In 2 patients, the first coil introduced into the aneurysm migrated distally into the parent vessel or its main branches (posterior cerebral and basilar arteries respectively). These patients were kept under continuous heparinisation for several weeks, to avoid clotting. One patient (case 2) had transient neurological symptoms, the other no neurological complication. In addition to migration, there is also a potential risk of aneurysm rupture by the catheter, the guide wire, or the coil itself. Thus, the technical difficulties of delivering the coil into the aneurysm often render this technique hazardous and the angiographic results poor.

Detachable coil embolisation is a recent method [30]. The main advantage of GDC is the possibility of with-

drawing the coil back into the microcatheter until a good position is achieved. In this series, GDC gave good or excellent results in 84% of cases. These results are consistent with those reported by Guglielmi et al. [19]. Complete angiographic occlusion was less frequent than with balloon embolisation, however. Intra-aneurysm thrombosis progressed with time in 3 of the 13 patients treated with GDC. Partial recanalisation was observed in one patient, which is less frequent than with the other techniques (4 patients treated with balloons or coils). Thus, the GDC may prevent the aneurysm opening up again, due to trapping of blood components within the network of coils, which enhances clot formation. Progression of thrombosis was generally slight (5–10%, maximum 30%) and seen in patients with dense initial coil packing, in agreement with the observations of Guglielmi et al. [31]. It is thus possible that the final angiographic results could improve with time, to approach those obtained with balloon procedures. Complications related to treatment were less frequent than with balloons. No permanent neurological complications occurred and only one patient suffered transient cerebellar symptoms (secondary to superior cerebellar artery occlusion). One patient died from rebleeding of the aneurysm and a basilar artery infarct territory. Aneurysm occlusion, performed 6 months previously, was incomplete because of coil migration during a prior treatment. Thus, the use of GDC for endovascular treatment of posterior circulation aneurysms was almost as efficient as and safer than balloon procedures. However, the follow-up period was short because this technique has been used in our institution only since September 1992, and the study of a larger series of patients over a longer period is needed for better evaluation.

References

1. McMurtry JG III, Housepian EM, Bowman FO Jr, et al (1979) Surgical treatment of basilar artery aneurysms. Elective circulatory arrest with thoracotomy in 12 cases. *J Neurosurg* 40: 486–494
2. Peerless SJ, Drake CG (1982) Management of aneurysms of posterior circulation. In: Youmans JR (ed) *Neurological surgery*. 2nd edn, vol 3. Saunders, Philadelphia, pp 1715–1763
3. Wilson CB, U HS (1976) Surgical treatment for aneurysms of the upper basilar artery. *J Neurosurg* 44: 537–543
4. Yasargil MG, Antic J, Laciga R, et al (1976) Microsurgical pterional approach to aneurysms of the basilar bifurcation. *Surg Neurol* 6: 83–91
5. Aymard A, Gobin YP, Hodes JE, et al (1991) Endovascular occlusion of vertebral arteries in the treatment of unclippable vertebrobasilar aneurysms. *J Neurosurg* 74: 393–398
6. Hieshima GB, Higashida RT, Wapenski J, et al (1986) Balloon embolization of a large distal basilar artery aneurysm. *J Neurosurg* 65: 413–416
7. Higashida RT, Halbach VV, Cahan LD, et al (1989) Detachable balloon embolization therapy of posterior circulation intracranial aneurysms. *J Neurosurg* 71: 512–519
8. Picard L, Roy D, Bracard S, et al (1993) Aneurysm associated with a fenestrated basilar artery: report of two cases treated by endovascular detachable balloon embolization. *AJNR* 14: 591–594
9. Romodanov AP, Shcheglov VI (1982) Intravascular occlusion of saccular aneurysms of the cerebral arteries by means of a detachable balloon catheter. *Adv Tech Stand Neurosurg* 9: 25–48
10. Serbinenko FA (1974) Balloon catheterization and occlusion of major cerebral vessels. *J Neurosurg* 41: 125–145
11. Berenstein A, Ransohoff J, Kupersmith M, et al (1984) Transvascular treatment of giant aneurysms of the cavernous carotid and vertebral arteries. Functional investigation and embolization. *Surg Neurol* 21: 3–12
12. Debrun G, Fox A, Drake C, et al (1981) Giant unclippable aneurysms: treatment with detachable balloons. *AJNR* 2: 167–173

13. Taki W, Handa H, Yamagata S, et al (1979) Balloon embolization of a giant aneurysm using a newly developed catheter. *Surg Neurol* 12: 363–365
14. Dowd CF, Halbach VV, Higashida RT, et al (1990) Endovascular coil embolization of unusual posterior inferior cerebellar artery aneurysms. *Neurosurgery* 27: 954–961
15. Graves VB, Partington CR, Rufenacht DA, et al (1990) Treatment of carotid artery aneurysms with platinum coils: an experimental study in dogs. *AJNR* 11: 249–252
16. Hodes JE, Aymard A, Gobin YP, et al (1991) Endovascular occlusion of intracranial vessels for curative treatment of unclippable aneurysms: report of 16 cases. *J Neurosurg* 75: 694–701
17. Lane B, Marks MP (1991) Coil embolization of an acutely ruptured saccular aneurysm. *AJNR* 12: 1067–1069
18. Numaguchi Y, Pevsner PH, Rigamonti D, et al (1992) Platinum coil treatment of complex aneurysms of the vertebrobasilar circulation. *Neuroradiology* 34: 252–255
19. Guglielmi G, Viñuela F, Dion J, et al (1991) Electrothrombosis of saccular aneurysms via endovascular approach, part 2. Preliminary clinical experience. *J Neurosurg* 75: 8–14
20. Hunt WE, Hess RM (1968) Surgical risk as related to time of intervention in the repair of intracranial aneurysms. *J Neurosurg* 28: 14–20
21. Jennett B, Bond MR (1977) Assessment of outcome after severe brain damage. A practical scale. *Clin Neurosurg* 24: 176–184
22. Drake CG, Vanderlinden RG (1967) The late consequences of incomplete surgical treatment of cerebral aneurysms. *J Neurosurg* 27: 226–238
23. Halbach VV, Higashida RT, Hieshima GB (1987) Treatment of intracranial aneurysms by balloon embolization therapy. *Semin Intervent Radiol* 4: 221–268
24. Fox AJ, Viñuela F, Pelz DM, et al (1987) Use of detachable balloons for proximal artery occlusion in the treatment of unclippable cerebral aneurysms. *J Neurosurg* 66: 40–46
25. Higashida RT, Halbach VV, Dowd CF, et al (1991) Interventional neurovascular treatment of a giant intracranial aneurysm using platinum microcoils. *Surg Neurol* 35: 64–68
26. Mickle JP, Quisling RG (1986) The transtorcular embolisation of vein of Galen aneurysms. *J Neurosurg* 64: 731–735
27. Halbach VV, Higashida RT, Hieshima GB, et al (1989) Transvenous embolisation of dural fistulas involving the transverse and sigmoid sinuses. *AJNR* 10: 386–392
28. Halbach VV, Higashida RT, Hieshima GB, et al (1989) Transvenous embolisation of dural fistulas involving the cavernous sinus. *AJNR* 10: 377–383
29. Casasco AE, Aymard A, Gobin YP, et al (1993) Selective endovascular treatment of 71 intracranial aneurysms with platinum coils. *J Neurosurg* 79: 3–10
30. Guglielmi G, Viñuela F, Sepetka I, et al (1991) Electrothrombosis of saccular aneurysms via endovascular approach, part 1. Electrochemical basis, technique, and experimental results. *J Neurosurg* 75: 1–7
31. Guglielmi G, Viñuela F, Dion J, et al (1992) Endovascular treatment of aneurysms with coils. *J Neurosurg* 76: 337–339