

16. Dave M. Two cases of risperidone-induced neuroleptic malignant syndrome (letter). *Am J Psychiatry* 1995;152:1233-4.
17. Levin G, Lazowick A, Powell H. *J Clin Psychopharmacol* (in press).
18. Chouinard G, Jones B, Remington G. A Canadian multi-center placebo controlled study of fixed doses of risperidone and haloperidol with treatment of chronic schizophrenic patients. *J Clin Psychopharmacol* 1993; 13:25-40.
19. Joshi PT, Capozzoli JA, Coyle JT. The Johns Hopkins Depression Scale. Narrative data and validation in child psychiatry patient. *J Am Acad Child Adolesc Psychiatry* 1990;29:283-8.
20. Busatto GF, Pilowsky LS, Costa DC, Burrell M. Dopamine D₂ receptor blockade in vivo with the novel antipsychotics risperidone, remoxipride: a 123I-IBMZ single photon emission tomography (SPET) study. *Psychopharmacology* 1995;22:42-6.
21. Cozza SJ, Edison DL. Risperidone in adolescents. *J Am Acad Child Adolesc Psychiatry* 1994;33:8.

NEUROLOGIC COMPLICATIONS FOLLOWING INTRANASAL ADMINISTRATION OF HEROIN IN AN ADOLESCENT

Gary B Zuckerman, Donna C Ruiz, Irwin A Keller, and Jill Brooks

OBJECTIVE: To describe an adolescent patient who developed a stroke following intranasal administration of heroin.

CASE SUMMARY: A 17-year-old adolescent with no prior medical problems "snorted" an unknown quantity of heroin. The patient developed respiratory failure, shock, and seizures. When he regained consciousness, the patient had evidence of hypoxic-toxic encephalopathy on neuropsychologic examination. Magnetic resonance imaging revealed an infarct in the globus pallidus region of the brain.

DISCUSSION: Serious neurologic complications following intranasal administration of heroin have been reported rarely in children. Correlations between findings on neuropsychologic examination and magnetic resonance imaging following drug overdoses have likewise been rarely described. We reviewed literature pertaining to the etiology, pharmacology, and pathophysiology of neurologic complications resulting from heroin intoxication.

CONCLUSIONS: As the use of intranasal heroin is increasing in the pediatric population, healthcare professionals should be aware of the various potentially serious complications that may occur.

Ann Pharmacother 1996;30:778-81.

HEROIN ABUSE IS INCREASING in the US. There also has been a significant shift in the mode of administration of heroin from intravenous injection to intranasal self-admin-

istration ("snorting").^{1,2} To date, neurologic complications from heroin abuse have been described primarily following its intravenous injection. We report a case of a stroke occurring in an adolescent who snorted heroin intranasally. The results of magnetic resonance imaging (MRI), as well as neurologic and neuropsychologic findings, are reported. Literature regarding neurologic complications of heroin abuse is discussed.

CASE REPORT

A previously healthy 17-year-old boy was found unresponsive with shallow respirations when his mother went to awaken him. Ten to twelve hours earlier, the patient had snorted an unknown quantity of heroin and smoked marijuana. He was transported to the hospital by emergency medical services. On arrival he was experiencing tonic-clonic seizures with intermittent periods of agitation alternating with unresponsiveness. The HR was 113 beats/min, RR 18 breaths/min, BP 138/68 mm Hg, and rectal temperature was 36.7 °C. His pupils were equal and reactive to light and there was no evidence of papilledema. The neck was supple, with no nuchal rigidity. Auscultation of the lungs revealed shallow respirations with no wheezing, rales, or rhonchi. Examination of the heart and abdomen was normal. The patient's extremities were cool, with prolonged capillary refill. The neurologic examination revealed an obtunded patient with poor response to painful stimuli. Reflexes were brisk and symmetric, and plantar responses were bilaterally upward. The Glasgow Coma Scale was 3. The patient did not respond to administration of naloxone 4 mg iv. His trachea was intubated and mechanical ventilation was instituted. An arterial blood gas evaluation following intubation revealed pH 7.44, pCO₂ 34 mm Hg, and pO₂ 179 mm Hg. The patient subsequently became hypotensive (60/20 mm Hg). He received 2 L of NaCl 0.9% solution, and an infusion of dopamine 5 µg/kg/min was begun. Activated charcoal 50 g was given through a nasogastric tube. A computed tomography (CT) scan of the brain was negative. The patient was transferred to the pediatric critical care unit where he remained unresponsive. A lumbar puncture revealed 2 neutrophils and 1 red blood cell. Cerebrospinal fluid protein and glucose were 37

Gary B Zuckerman MD, Assistant Professor, Associate Director, Division of Pediatric Critical Care Medicine, Department of Pediatrics, University of Medicine and Dentistry of New Jersey (UMDNJ), Robert Wood Johnson Medical School (RWJMS), One Robert Wood Johnson Place, New Brunswick, NJ 08903, FAX 908/235-7345

Donna C Ruiz MD, Senior Pediatric Resident, Department of Pediatrics, UMDNJ, RWJMS

Irwin A Keller MD, Radiologist, Robert Wood Johnson University Hospital, New Brunswick, NJ

Jill Brooks PhD, Assistant Professor of Clinical Neurology, Department of Neurology, UMDNJ, RWJMS

Reprints: Gary B Zuckerman MD

mg/dL and 102 mg/dL, respectively. The complete blood cell count, serum electrolytes, serum glucose, liver enzymes, and chest X-ray were normal.

A urine drug screen on admission was positive for opiates and cannabis. The serum drug screen for alcohol, salicylates, and hypnotic sedatives was negative.

The patient was successfully extubated, and the dopamine infusion was discontinued within 24 hours of admission. For the next 48 hours he remained agitated and so was treated with intravenous lorazepam. An MRI of the brain revealed globular areas of hyperintense signals on T2-weighted images in the globus pallidus bilaterally, and abnormal patchy mild increased signals in the periventricular white matter, consistent with hypoxic-toxic encephalopathy (Figures 1 and 2).

On day 4 of hospitalization the patient was awake, alert, and oriented to person, place, and time. Neurologic testing was unremarkable except for mildly increased tone in all four extremities.

Neuropsychologic evaluation revealed abnormalities in sustained and divided attention (for auditory and visual stimuli) and verbal and nonverbal memory, with deficits in encoding and retrieval and decreased speed of information processing. These findings were considered consistent with hypoxic encephalopathy (bitemporal findings). There was evidence of bifrontal deficits to a lesser degree including verbal and motor perseveration, and difficulties with motor regulation, verbal fluency, and organizational (executive) skills. There was, however, no evidence of aphasia, dysarthria, apraxia, or any primary visuospatial or perceptual disturbances. The patient was transferred out of intensive care 72 hours after admission and then on day 7 to a drug rehabilitation center where he attended the addiction recovery program and received physical and occupational therapy and psychological counseling.

Discussion

This case highlights the relationship between abnormalities found on neuropsychologic examination with pathology noted on MRI of the brain that were the result of complications following the intranasal self-administration of heroin in an adolescent. To our knowledge these findings have not been previously reported in the literature. This report also emphasizes the value of neuropsychologic testing in determining not only the extent of impairment but also the rehabilitation needs of a patient who has experienced a drug overdose.

An increase in the use of heroin has been noted in many major cities in the US, leading some to speculate there is a new heroin epidemic under way.^{2,3} Coincident with the increase in the use of heroin is an increased popularity of the intranasal route of administration. In the past, the heroin sold on the streets was of low purity and relatively expensive. Heroin abusers often obtained only small amounts of this low purity heroin and had to inject the drug in order to experience its euphoric effects. In addition, the sharing of contaminated needles became a source of HIV transmission among addicts. In 1992, the Drug Enforcement Administration reported an influx of very pure, inexpensive heroin into many major cities in the US from Southeast Asia, Southwest Asia, and Mexico.³ The lower cost and higher purity of this heroin, in conjunction with the fear of acquiring HIV infection from contaminated needles, have been suggested as reasons for the increased popularity of intranasal administration of heroin.^{1,4}

Cone et al.⁴ reported that the pharmacokinetic profile of intranasal heroin was similar to that of the intramuscular route. Peak heroin concentrations were attained in blood within 5 minutes after intranasal and intramuscular administration of heroin, and concentrations declined thereafter in a first-order logarithmic manner. Mean elimination half-life of heroin administered intranasally was 0.09 ± 0.05 hours, which was not significantly different from that of heroin administered intramuscularly. Physiologic, behavioral, and performance effects following intranasal administration were similar to the effects following intramuscular administration even though the relative potency of intranasally administered heroin was estimated to be approximately half that of intramuscularly injected heroin. Both intranasal and intramuscular administration of heroin cause pupillary miosis, decreased respirations, and lower body temperature.

Heroin or diacetylmorphine is an opiate and is made from acetylation of morphine. Heroin, like morphine, be-

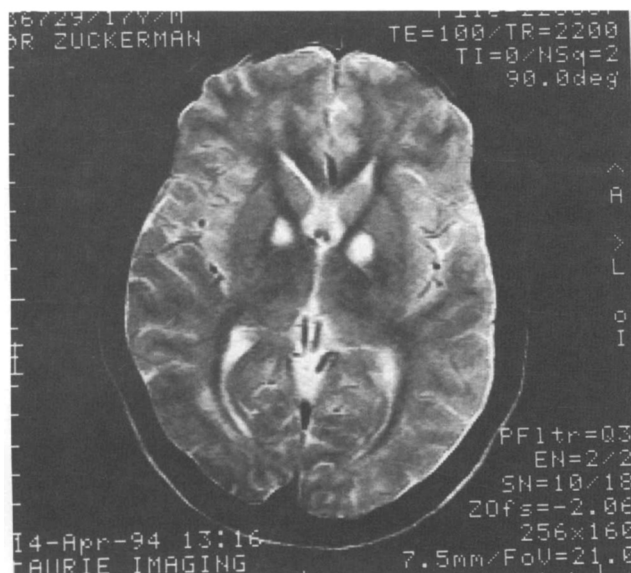


Figure 1. Axial T2-weighted image (TR2200; TE100) at the level of the basal ganglia. Abnormal increased signal from the globus pallidus is present bilaterally somewhat more pronounced on the left. Although this finding is nonspecific, it is usually secondary to a toxic or anoxic injury.

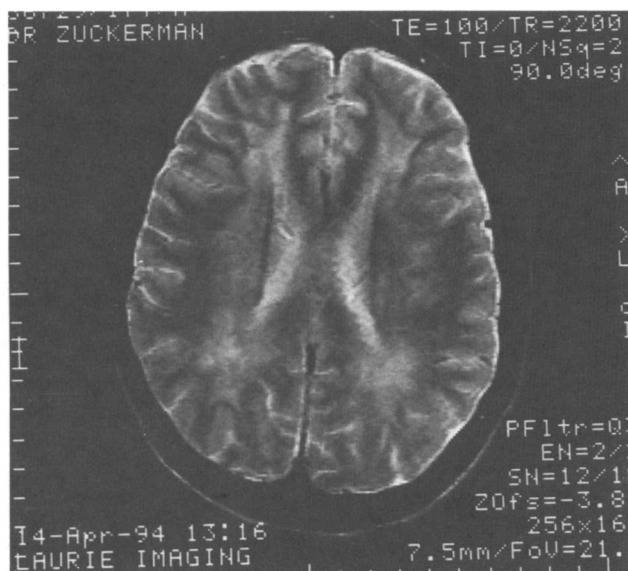


Figure 2. Axial T2-weighted image (TR2200; TE100) shows abnormally increased signal intensity in the parietal white matter adjacent to the occipital horns of the lateral ventricles.

heroin as an agonist and interacts with stereospecific and saturable receptors in the central nervous system and other tissues. Once in the blood, heroin is rapidly hydrolyzed to monoacetylmorphine (MAM), which is then hydrolyzed to morphine. Heroin and MAM are more lipid-soluble than morphine and enter the brain more readily. Morphine and MAM are believed to be responsible for the pharmacologic actions of heroin. Morphine is then detoxified in the liver through conjugation with glucuronic acid. Heroin is excreted in the urine mainly as free and conjugated morphine.⁵ Cone et al.⁴ found that the intranasal administration of heroin resulted in the rapid appearance of heroin, MAM, and morphine in the blood. Morphine was present for a longer time (2–4 h) than heroin or MAM because of its lower clearance rate. Morphine's time course coincided with the observed drug-induced effects of intranasal heroin.

To date, many neurologic complications have been associated with intravenous heroin abuse^{6–18}; however, adverse neurologic events following the intranasal administration of heroin have been reported rarely. Acute transverse myelitis involving thoracic segments of the spinal cord has been reported as a complication following intravenous heroin abuse.^{6–8} Possible causes of transverse myelitis include a hypersensitivity reaction to heroin or one of its adulterants, direct toxic effects of the drug, hypoxic effects resulting from opiate-induced hypotension or respiratory depression, or temporary vascular insufficiency in the thoracic cord circulation.

Cerebral vascular complications following intravenous heroin administration presenting as hemiplegias, aphasias, hemipareses, and hemianopsias have also been reported.^{7,9–16} Possible causes included emboli from bacterial or fungal endocarditis, focal ischemia during a period of shock and hypoventilation, drug allergy, and cerebral arteritis. Autopsy studies performed on heroin addicts following strokes have revealed vascular changes of necrotizing angitis including arterial aneurysms and sacculations that were indistinguishable from polyarteritis nodosa.¹⁴ Cerebral angiographic studies in heroin abusers following cerebral vascular accidents revealed occlusive changes probably due to vasculitis and secondary thrombus formation.^{10,15}

Jensen et al.¹⁶ performed arteriograms, CT scans, and technetium-99 scintigrams on two heroin addicts who developed severe ischemic strokes. The findings included nonocclusive extensive infarctions in the carotid territory, with severe hyperemia of the entire carotid territory including areas where infarction did not develop. Jensen et al. concluded that the strokes were not the result of arterial occlusion, but were more likely due to generalized hypoxia combined with decreased perfusion pressure in the carotid territory because of external compression of the carotid artery during the intoxicated comatose state.

Infectious causes of central nervous system pathology related to heroin abuse include embolization of fungal and bacterial organisms from either infected pulmonary vessels or cardiac valves or from direct extension of infection from cranial sinuses or orbits along veins, meninges, or spinal fluid.¹⁷ Generalized seizures have also been described following intravenous heroin use^{7,18}; however, it is unclear whether the seizures were due to a direct convulsant effect of heroin, an injected contaminant, or cerebral anoxia.

Wolters et al.¹⁹ described 47 adults who developed toxic leukoencephalopathy after inhaling the smoke obtained by

heating heroin. Roulet-Perez et al.²⁰ described the development of toxic leukoencephalopathy in a 2½-year-old child following heroin ingestion.

Our patient developed neurologic complications following the intranasal administration of heroin. He presented with generalized tonic-clonic seizures following a history of what might have been a prolonged period of unresponsiveness, hypoventilation, and shock. Marijuana may have contributed to the respiratory depressant effects of heroin. It is unclear whether his seizures were due to the direct effects of heroin, a contaminant, cerebral hypoxia that may have resulted from respiratory depression, shock, or both respiratory depression and shock. Of interest was that his coma was not reversed by naloxone. His neurologic findings may therefore have been caused primarily by hypoxic-anoxic encephalopathy which was caused by heroin's depressant effects. The findings on the MRI of the brain were suggestive of hypoxic-toxic encephalopathy. Of particular interest were the prominent deficits noted on neuropsychologic testing that were also consistent with hypoxic encephalopathy. The neuropsychologic findings were especially important for determining the kind of rehabilitative therapies required.

Summary

As the use of heroin as a "recreational drug" increases in the pediatric population in the US and as the intranasal route of administration is growing in popularity among heroin abusers, it is important for healthcare providers to be aware of the various neurologic and other systemic complications that may develop from intranasal use of heroin. Just as the pharmacokinetic profile of intranasally administered heroin mimics that of heroin which is injected, the adverse neurologic and systemic effects may be very similar and as potentially dangerous. Neuropsychologic assessment may prove to be a useful and sensitive tool in diagnosing residual neurobehavioral deficits resulting from heroin overdosage and in guiding appropriate rehabilitation. ≡

References

1. French J, Safford J. AIDS and intranasal heroin (letter). *Lancet* 1989;1:1082.
2. A new heroin epidemic? *Pharmchem News* 1992;20(2):1-4.
3. A calendar year 1991 report on the source areas, cost and purity of retail-level heroin. Domestic monitor program. Rockville, MD: Drug Enforcement Administration, Office of Intelligence, 1992:1-17.
4. Cone E, Holicky B, Grant T, Darwin WD, Goldberger B. Pharmacokinetics and pharmacodynamics of intranasal "snorted" heroin. *J Anal Toxicol* 1993;17:327-37.
5. Jaffe J, Martin W. Opioid analgesics and antagonists. In: Gilman A, Goodman L, Rall T, Murad F, eds. *The pharmacological basis of therapeutics*. 7th ed. New York: Macmillan Publishing, 1985:491-531.
6. Richter R, Rosenberg R. Transverse myelitis associated with heroin addiction. *JAMA* 1968;206:1255-7.
7. Richter R, Baden M. Neurological complications of heroin addiction. *Trans Am Neurol Assoc* 1969;94:330-2.
8. Schein P, Yessayan L, Mayman C. Acute transverse myelitis associated with intravenous opium. *Neurology* 1971;21:101-2.
9. Brust J, Richter R. Stroke associated with addiction to heroin. *J Neurol* 1976;39:194-9.
10. King J, Richards M, Tress B. Cerebral arteritis associated with heroin abuse. *Med J Aust* 1978;2:444-5.

11. Woods B, Strewler G. Hemiparesis occurring six hours after intravenous heroin injection. *Neurology* 1972;22:863-6.
12. Caplan L, Hier D, Banks G. Current concepts of cerebrovascular disease—stroke: stroke and drug abuse. *Stroke* 1982;13:869-72.
13. Chenery H, Murdoch B. A case of mixed transcortical aphasia following drug overdose. *Br J Disord Commun* 1986;21:381-92.
14. Citron B, Halpern M, McCarron M, Lundberg G, McCormick R, Pincus I, et al. Necrotizing angitis associated with drug abuse. *N Engl J Med* 1970;283:1003-11.
15. Rumbaugh C, Bergeron T, Fang H, McCormick R. Cerebral angiographic changes in the drug abuse patient. *Radiology* 1971;101:335-44.
16. Jensen R, Olsen T, Winther B. Severe non-occlusive ischemic stroke in young heroin addicts. *Acta Neurol Scand* 1990;81:354-7.
17. Hameroff S, Eckholdt J, Lindenberg R. Cerebral phycomycosis in a heroin addict. *Neurology* 1970;20:261-5.
18. Alldredge B, Lowenstein D, Simon R. Seizures associated with recreational drug abuse. *Neurology* 1989;39:1037-9.
19. Wolters E, Stam F, Lousberg R. Leucoencephalopathy after inhaling "heroin" pyrolysate. *Lancet* 1982;2:1233-7.
20. Roulet-Perez E, Maeder P, Rivier L, Deonna T. Toxic leucoencephalopathy after heroin ingestion in a 2½-year-old child (letter). *Lancet* 1992;340:729.

EXTRACTO

OBJETIVO: Informar el caso de un paciente adolescente que desarrolló un accidente cerebrovascular después de la administración intranasal de heroína.

RESUMEN: Un paciente masculino de 17 años sin historial de problemas médicos inhaló una cantidad no cuantificada de heroína. El paciente desarrolló fallo respiratorio, shock, y convulsiones. Cuando recuperó el conocimiento, el paciente había desarrollado encefalopatía hipóxicatóxica evidenciada a través de un examen neuropsicológico. La imagen obtenida por resonancia magnética demostró un infarto en la región del globo pálido del cerebro.

DISCUSIÓN: En raras ocasiones se han informado las complicaciones neurológicas severas después de la administración intranasal de heroína en niños. Las correlaciones entre los hallazgos en el examen neuropsicológico y las imágenes obtenidas en resonancia magnética después de una sobredosis de drogas han sido descritas también en raras ocasiones. En este artículo se revisa la literatura relacionada con la etiología, farmacología y patofisiología de las complicaciones neurológicas como resultado de la intoxicación con heroína.

CONCLUSIONES: Se informó fallo respiratorio, shock, y convulsiones en un paciente de 17 años que inhaló heroína y desarrolló un accidente cerebrovascular. Se informan los hallazgos de la evaluación

neuropsicológica y la imagen obtenida en resonancia magnética. Estas complicaciones y hallazgos han sido descritos en raras ocasiones en niños que inhalan heroína. Debido a que el uso de heroína intranasal está aumentando en la población pediátrica los profesionales de la salud deben estar conscientes de las complicaciones potencialmente severas que pueden ocurrir. El abuso de heroína está aumentando en los Estados Unidos. Recientemente se ha observado un cambio significativo en la vía de administración de heroína, de la vía intravenosa a la vía intranasal. Las complicaciones neurológicas debidas al abuso de heroína que han sido descritas principalmente están relacionadas a la inyección intravenosa de heroína. Se informa el caso de un adolescente que tuvo un accidente cerebrovascular después del uso intranasal de heroína. Se informan los hallazgos de la imagen obtenida por resonancia magnética, y los hallazgos neurológicos y neuropsicológicos. Además se discute la literatura relacionada con las complicaciones neurológicas debidas al abuso de heroína.

LYDIA GONZÁLES

RÉSUMÉ

OBJECTIF: Rapporter l'histoire d'un adolescent qui a eu un accident cérébro-vasculaire après avoir prisé de l'héroïne.

RÉSUMÉ DU CAS: Un jeune homme de 17 ans, sans antécédant médical, a prisé une quantité inconnue d'héroïne. Le patient a développé de l'insuffisance respiratoire, un choc cardiogénique, et des convulsions. Lors de la prise de conscience du patient, un examen neuro-psychologique a révélé une encéphalopathie de type hypoxique-toxique. L'imagerie par résonance magnétique révèle un infarctus dans la région du globus pallidus.

DISCUSSION: Des complications neurologiques sérieuses suite à l'administration intra-nasale d'héroïne ont été rapportées rarement chez les enfants. Les corrélations des résultats obtenus par résonnance magnétique et les examens neuro-psychologiques ont aussi été rarement décrites. La littérature sur l'étiologie, la pharmacologie, et la pathophysiologie des complications neurologiques résultantes d'une intoxication d'héroïne a été révisée.

CONCLUSIONS: Un jeune homme de 17 ans a eu un accident cérébro-vasculaire, une insuffisance respiratoire, un choc cardiogénique, et des convulsions après avoir prisé de l'héroïne. Les résultats de l'évaluation neuro-psychologique et par résonnance magnétique ont été rapportés. Ces complications et ces résultats ont été rarement décrits chez les enfants qui ont prisé de l'héroïne. Étant donné que l'incidence d'une telle utilisation de l'héroïne augmente dans la population pédiatrique, les professionnels de la santé doivent être conscients des complications potentiellement sérieuses de cette nouvelle tendance.

STÉPHANE BISSONNETTE