

Clinical and radiological evaluation of angiographically occult, calcified intracranial vascular malformation.

Case report

Süleyman Baykal¹, Savaş Ceylan¹, Hasan Dinç², Kayhan Kuzeyli², Eray Soylev¹, Haydar Usul¹, and Fadil Aktürk¹

Departments of ¹Neurosurgery and ²Radiology, KTU Medical Faculty, Trabzon, Turkey

Abstract

In this study, we present an angiographically occult, calcified intracranial vascular malformation. This lesion is rare and has some therapeutic difficulties and different approaches by authors. In this article, we also discuss the clinical, radiological characteristic features of this lesion. We pay attention on the totally calcified malformation.

Keywords: Angiography, calcification, magnetic resonance imaging.

1 Introduction

The term “angiographically occult intracranial vascular malformation” (OVM) is applied to a group of intracranial vascular malformations (arteriovenous, cavernous, venous angiomas or capillary telangiectases) [1, 2, 3, 4, 7, 8, 12, 16, 17]. In the literature, the term thrombosed malformations and occult intracranial vascular malformations have been used interchangeably [7]. Magnetic resonance imaging of these patients can often help to suggest the diagnosis of angiographically occult vascular malformations with increased confidence [10, 11, 14, 15].

In this report, we present a patient with radiologically verified angiographically occult, calcified vascular malformation and discuss her clinical and magnetic resonance imaging (MRI) characteristics.

2 Case report

A 22-year-old woman presented with a 16-year

history of complex partial seizures insufficiently controlled by antiepileptic drugs. The physical and neurological examination on admission was normal.

Plain films show an irregular calcification in the left middle fossa (Figure 1). MRI show a serpentine lesion in the left temporal lobe with mixed isointens region on T2-weighted images (Figure 2a, b). The angiogram was without shunting, blush, or abnormal vessels (Figure 3a, b). The MR-angio was also normal (Figure 4). The diagnosis was totally calcified vascular malformation.

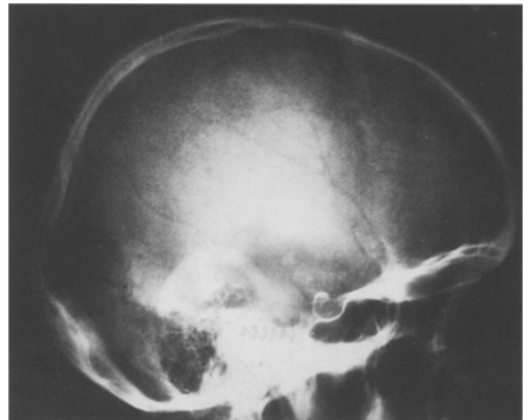


Figure 1. Lateral plain skull film showing a huge calcification in the suprasellar region. Note an irregular and heterogeneous appearance.

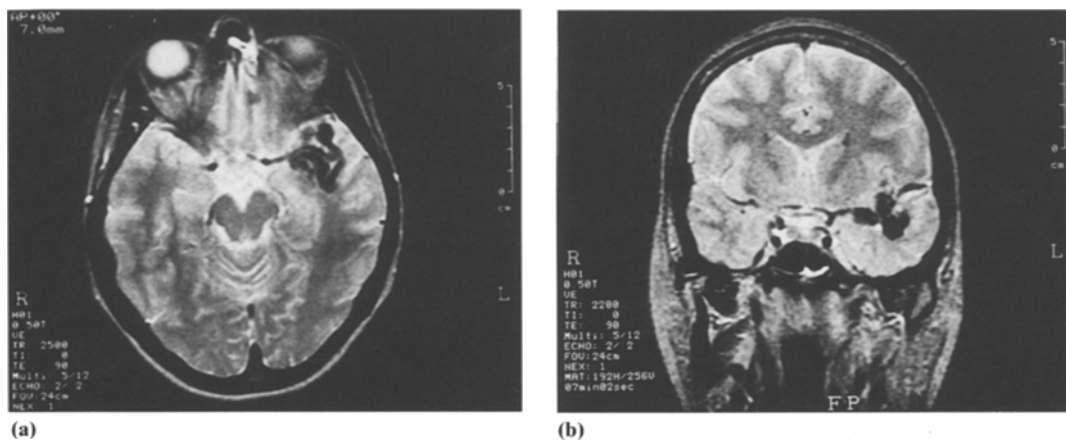


Figure 2. T2-weighted axial (a) and coronal (b) MR images, showing an irregular hypointens lesion located in the left temporal lobe.

The patient and her family did not admit surgical exploration. Her seizures were controlled by carbamazepine and valproic acid and discharged.

3 Discussion

Because of common radiographic findings and a spectrum of common histopathological findings, thrombosed arteriovenous malformations and occult vascular malformations seem to have similar presentations and prognosis and indeed may represent the same disease entity [7, 10, 12]. The responsible mechanisms for the partial or complete thrombosis of angiographically occult intracranial vascular malformations are arteriosclerosis, embolism, hem-

orrhage with secondary vascular compression, slow blood flow, intravascular turbulency due to the tortuosity of the vessels, and hypercoagulability [12, 13].

LOBATO et al. reported some calcification in approximately 10% of patients with OVM's on skull x-ray films [1, 9, 12]. They also demonstrated calcification in 24% of patients on the nonenhanced CT scan [12]. Two cases of dystrophic intracranial calcification due to arteriovenous malformations were reported by YU et al. They explained the probable pathogenetic mechanism for calcification as a result of "cerebral steal" by the arteriovenous malformation [18]. We are not certain whether calcification in our case is explained by the proposed mechanism in our case. In this lesion, OVM was calcified. This huge

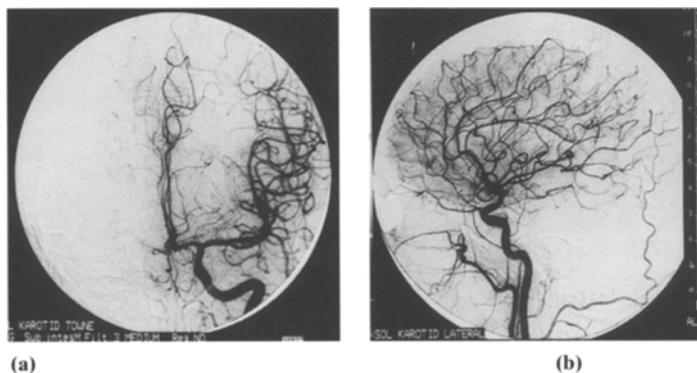


Figure 3. Normal angiograms were shown on the anteroposterior (a) and lateral (b) projection.

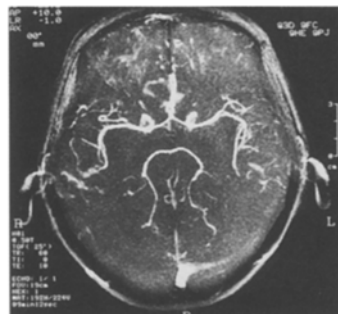


Figure 4. MR-angiogram was normal.

calcification is shown by plain x-ray and MRI. In the literature review, a similar lesion was not demonstrated.

Headache and seizure disorders are the most common clinical presentation of OVM's [5, 6, 15]. In addition, episodic progressive worsening is the second most clinical presentation [15]. These clinical presentations may suggest the presence of a low grade neoplasm but, the duration of the patient's seizures

and MRI findings may differentiate these two lesions.

It was postulated that CT scan and MRI appear to be about equally sensitive in the detection of these lesions, although the MRI is probably slightly more specific [14, 15]. But if calcification is present, CT scan is superior to MRI for the evaluation of calcified lesion. Angiography is essential for its vascular nature of this lesion.

References

- [1] BECKER DH, JJ TOWNSEND, RA KRAMER: Occult cerebrovascular malformations. A series of 18 histologically verified cases with negative angiography. *Brain* 102 (1979) 249-287.
- [2] BELL BA, BE KENDALL, L SYMON: Angiographically occult arteriovenous malformations of the brain. *J Neurol Neurosurg Psychiatry* 41 (1978) 1057-1064.
- [3] BITOH S, H HASEGAWA, M FUJIWARA: Angiographically occult vascular malformations causing intracranial hemorrhage. *Surg Neurol* 17 (1982) 35-42.
- [4] BRITH RH, WS CONNOR, DR ENZMANN: Occult arteriovenous malformation of the brainstem simulating multiple sclerosis. *Neurology* 31 (1981) 901-903.
- [5] COHEN HCM, WS TUCKER, RP HUMPHREYS, et al: Angiographically cryptic histologically verified cerebrovascular malformations. *Neurosurgery* 10 (1982) 704-714.
- [6] EL-GOHARY ME, T TOMITA, FA GUTIERREZ, et al: Angiographically occult vascular malformations in childhood. *Neurosurgery* 20 (1987) 759-766.
- [7] EBELING JD, BI TRANMER, KA DAVIS, GW KINDT, BK DEMASTERS: Thrombosed Arteriovenous Malformations: A Type of Occult Vascular Malformation. *Neurosurgery* 23 (1988) 605-610.
- [8] GOLDEN JB, RA KRAMER: The angiographically occult cerebrovascular malformation. Report of three cases. *J Neurosurg* 48 (1978) 292-296.
- [9] HASHIM ASM, T ASAKURA, U KOICHI et al: Angiographically occult arteriovenous malformations. *Surg Neurol* 23 (1985) 431-439.
- [10] KUCHARCZYK W, L LEMME-PLEGHOS, A USKE et al: Intracranial vascular malformations: MR and CT imaging. *Radiology* 156 (1985) 383-389.
- [11] LEE BLP, L HERZBERG, RD ZIMMERMAN et al: MR imaging of cerebral vascular malformations. *AJNR* 6 (1985) 863-870.
- [12] LOBATO RD, C PEREZ, JJ RIVAS, F CORDOBES: Clinical, radiological, and pathological spectrum of angiographically occult intracranial vascular malformations. *J Neurosurg* 68 (1988) 518-531.
- [13] NEHLS DG, H PITTMAN: Spontaneous regression of arteriovenous malformations. *Neurosurgery* 11 (1982) 776-780.
- [14] NEW PFJ, RG OJEMAN, KR DAVIS et al: MR and CT of occult vascular malformations of the brain. *AJNR* 7 (1986) 771-779.
- [15] OGILVY CS, RC HEROS, RG OJEMAN, PF NEW: Angiographically occult arteriovenous malformations. *J Neurosurg* 69 (1988) 350-355.
- [16] TOMLINSON FH, OW HOUSER, BW SCHEITHAUER, H OKAZAKI, TM SUNDT, JE PARISI: Angiographically occult vascular malformations: A correlative study of features on magnetic resonance imaging and histological examination. *Neurosurgery* 34 (1994) 792-800.
- [17] WAKAI S, Y UEDA, S INOH: Angiographically occult angiomas: a report of thirteen cases with an analysis of the cases documented in the literature. *Neurosurgery* 17 (1985) 549-556.
- [18] YU YL, EK CHIU, E WOO, FL CHAN, WK LM, CY HUANG, PW LEE: Dystrophic intracranial calcification: CT evidence of "cerebral steal" from arteriovenous malformation. *Neuroradiology* 29 (6) (1987) 519-22.

Submitted July 24, 1994. Revised February 10, 1995.
Accepted February 14, 1995.

Dr. Süleyman Baykal
KTÜ Tıp Fakültesi
Nörosirürji Kliniği
61080 Trabzon
Turkey