

Cortical Blindness and Cerebral Infarction Associated With Severe Hypoglycemia

ANN E. GOLD, MD
SALLY M. MARSHALL, MD

OBJECTIVE — To describe a case of cortical blindness and cerebral infarction associated with severe hypoglycemia.

CONCLUSIONS — The possible pathogenesis of the neurological defects is discussed.

Hypoglycemia is a common complication of insulin-treated diabetes. Recurrent severe hypoglycemia is associated with cognitive dysfunction (1,2) or even death (3). Other neurological manifestations of hypoglycemia include hemiplegia, decerebration, ataxia, choreoathetosis, the "locked-in" syndrome, and severe amnesia (4,5). Of reports on neurological manifestations of nonfatal hypoglycemia, 50% are of transient abnormalities (4).

A severe hypoglycemic coma case in a 22-year-old woman, resulting in permanent neurological abnormalities including cortical blindness, is described.

CASE — This 22-year-old woman developed diabetes at the age of 12. Glycemic control had never been particularly tight, but despite this, the patient had had a tendency to hypoglycemia, especially related to sports. Between 1989 and 1991, the patient experienced three episodes of severe hypoglycemia requiring glucagon. In June 1991, she was found by her parents unconscious in bed and profoundly hypoglycemic, and on this admission she required ventilation. Computed tomography (CT) scan showed no abnormality. The patient made an apparent full recovery of neurological function and was discharged home.

Over the next 4 years, the patient's glycemic control remained suboptimal,

with most HbA_{1c} concentrations in the range 8.0–10.2% (normal range <6.0%). She had no further episodes of severe hypoglycemia, and awareness of hypoglycemia appeared satisfactory.

In May 1995, the patient was admitted with mild ketoacidosis, secondary to a urinary tract infection. The most recent HbA_{1c} was 10.2%. On admission, she was taking 100 U/day (1.3 U/kg). Following standard treatment, the patient made a rapid recovery. Marked reductions in insulin doses were required so that at the time of discharge, the patient was taking a total daily dose of 74 U, and further reductions were made over the following few days.

Five days later, the patient was found comatose in the morning by her parents and was admitted to hospital. On the day before admission, she experienced difficulty in avoiding hypoglycemia, despite taking extra carbohydrate and further reducing the insulin doses. There had been no strange behavior, and there appeared to be no suicidal motivation. On admission to the hospital, the patient exhibited decerebrate movements. Blood glucose was <1 mmol/l. Emergency CT scan (Fig. 1A) showed no abnormality, and a lumbar puncture was normal. Cortisol response to tetracosactin was satisfactory. Over the next 4 days, the patient experienced apneic episodes requiring ventilation, and there was evi-

dence of seizure activity for which she received phenytoin. An electroencephalogram (EEG) performed at this time showed almost continuous sharp wave discharges originating from the right parietal region; episodes of facial twitching were accompanied by an increase in this sharp wave activity. In summary, the EEG revealed evidence of severe cerebral insult.

Over the next week, the patient showed some evidence of improvement and no longer required ventilation. There was evidence of spontaneous eye opening and some vocal noises. After 3 weeks, all seizure activity appeared to have resolved. Over the next 4 weeks, there was a further slow improvement in neurological function. The patient moved all limbs spontaneously and made spontaneous sounds. Swallowing returned to normal. The patient would turn to verbal stimuli but did not respond to visual stimuli. Funduscopy and pupillary reflexes were normal. Visual evoked potentials revealed normal electroretinograms, suggesting normal retinal function; however, the cortical responses recorded from either eye after a visual stimulus were grossly abnormal, suggesting severe lesions within both cortical areas of the visual system. A repeat EEG was reported as showing diffuse slow wave activity but no seizure activity.

Two months after admission, the patient was able to walk if guided and eat with assistance but was unable to talk coherently or understand basic verbal commands. Four months after admission, the CT scan was repeated (Fig. 1B). There were marked changes compared with the scan performed on admission, with evidence of gross global cerebral atrophy with areas of attenuation in the posterior parietal regions consistent with possible infarction. EEG activity had not changed.

The patient remained entirely dependent and required constant supervision. The parents wished to manage their daughter at home. However, the availability of financial support for providing appropriate assistance was not forthcoming. The patient's mother has given up her work to care for her daughter.

From the Department of Diabetes, Newcastle General Hospital, Newcastle upon Tyne, U.K.

Address correspondence and reprint requests to A.E. Gold, MD, Ward 3 Office, Newcastle General Hospital, Westgate Rd., Newcastle upon Tyne NE4 6BE, U.K.

Received for publication 22 January 1996 and accepted in revised form 2 May 1996.

CT, computed tomography; EEG, electroencephalogram; MRI, magnetic resonance imaging.

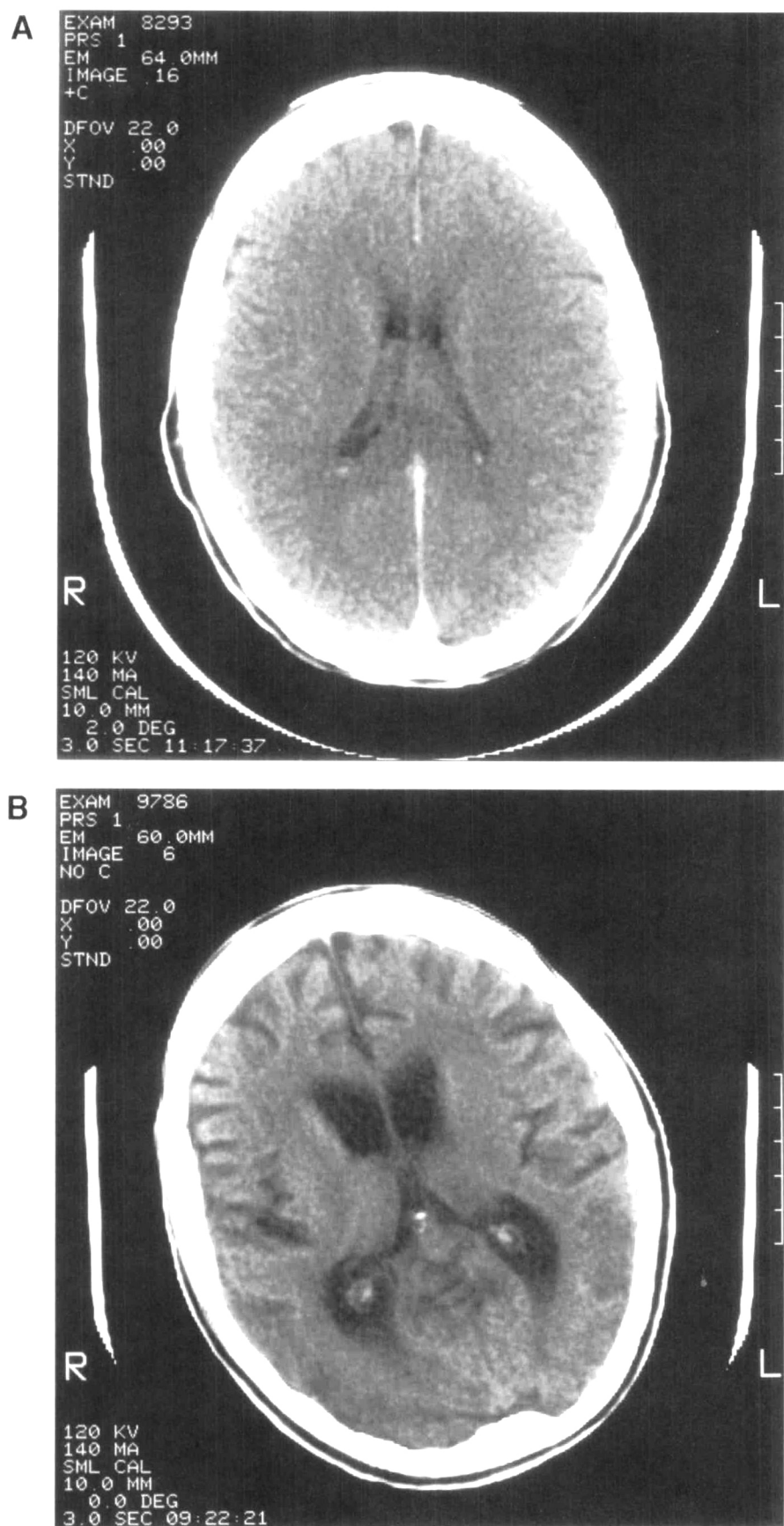


Figure 1—A: CT scan without contrast 12 h after admission with severe hypoglycemia B: CT scan taken 4 months after admission with severe hypoglycemia.

CONCLUSIONS— This case history illustrates the devastating effect that a single episode of severe hypoglycemia may have on a patient and his or her family. The cerebral damage sustained included gross cerebral atrophy and probable cerebral infarction, which were manifest as severe cognitive changes and as cortical blindness, which was confirmed clinically and on evoked potential recordings. Cortical blindness is defined as the loss of vision in the presence of normal pupillary reflexes and in the absence of ophthalmological disease. Transient cortical blindness has previously been documented as a result of hypoglycemia in a child with a glycogen storage disease (6), but to our knowledge, permanent cortical blindness as a result of hypoglycemia has not been described in a patient with insulin-treated diabetes.

Postictal cortical blindness has been described both in adults and in children (7–10). In almost all of these cases, the defect was transient. It has been suggested that, particularly in children, there is an increased susceptibility of the occipital cortex to paroxysmal EEG abnormalities, which appear to migrate towards the temporal regions as children grow older (9). Other cerebral insults have also been associated with cortical blindness: hypoxia, cardiac arrest, trauma, intracranial hemorrhage, X-ray contrast media, and hyponatremia (11–15). The occipital cortex receives its blood supply from both middle and posterior cerebral arteries. If one vessel is occluded, this dual blood supply protects the area from ischemic damage, but if there is general hypoxia, for example during prolonged hypotension, this protection does not occur (15). A recent pilot study examined the effects of the postanoxic syndrome on cerebral glucose metabolism in patients who had suffered a cardiac arrest (16). Using positron emission tomography, regional decreases in cerebral glucose metabolism were demonstrated, particularly in the parietal and occipital cortices, and were associated with cortical blindness. The authors suggest that cerebral hypoxia induces hypometabolism, which preferentially affects regions in arterial border zones (16).

Acute hypoglycemia induces changes in homeostasis and coagulation defects (17). Increases in von Willebrand factor during acute hypoglycemia may promote platelet adhesion, and changes

in fibrinolysis may result in a hypercoagulable state (17). An imbalance between coagulation and fibrinolysis, with coagulation predominant, has been demonstrated during acute hypoglycemia (18). Such changes may predispose to thrombosis and precipitate cerebral infarction, as was suggested by the CT scan in the patient described. Although no specific changes were demonstrated on CT or EEG in the occipital regions, which may have been anticipated in cortical blindness, it is possible that the gross atrophic changes may have masked more subtle areas of infarction in this region. Transient cortical blindness in association with other neurological conditions and potentially hypercoagulable states in nondiabetic patients has been demonstrated to be associated with abnormalities on magnetic resonance imaging (MRI) and CT scans, which may have been secondary to small cortical venous thromboses (19). In addition, MRI may identify some occipital lesions that are not visible on CT scanning (19). It is possible that the apneic and convulsive episodes experienced by the patient contributed to the cerebral changes; however, these episodes occurred while the patient was being ventilated, and no significant prolonged deteriorations in oxygen saturation were permitted.

This case also illustrates the difficulty faced by caregivers of patients with cerebral dysfunction (20) and the lack of facilities and resources to meet their needs.

The cause of the hypoglycemia in this patient remains unknown. It is possible that the ability of the patient to counterregulate was impaired because of the frequent episodes of hypoglycemia experienced the previous day (21,22), thereby predisposing the patient to severe hypoglycemia. In conclusion, cerebral infarction and cortical blindness are rare complications of severe hypoglycemia but have a profound effect on rehabilitation and quality of life.

References

1. Wredling R, Levander S, Adamson U, Lins PE: Permanent neuropsychological impairment after recurrent episodes of severe hypoglycaemia in man. *Diabetologia* 33:152-157, 1990
2. Langan SJ, Deary IJ, Hepburn DA, Frier BM: Cumulative cognitive impairment following recurrent severe hypoglycaemia in adult patients with insulin-treated diabetes mellitus. *Diabetologia* 34:337-344, 1991
3. Kalimo H, Olsson Y: Effects of severe hypoglycaemia on the human brain: neuropathological case reports. *Acta Neurol Scand* 62:345-356, 1980
4. Lins P-E, Adamson U: Neurological manifestations of hypoglycaemia. In *Hypoglycaemia and Diabetes: Clinical and Physiological Aspects*. Frier BM, Fisher BM, Eds. London, Edward Arnold, 1993, p. 347-354
5. Chalmers J, Risk MTA, Kean DM, Grant R, Ashworth B, Campbell IW: Severe amnesia after hypoglycemia. *Diabetes Care* 14:922-925, 1991
6. Mukamel M, Weitz R, Nissenkorn I, Yasur I, Varsano I: Acute cortical blindness associated with hypoglycemia. *J Pediatr* 98:583-584, 1981
7. Barnet AB, Manson JI, Wilner E: Acute cerebral blindness in childhood. *Neurology* 20:1147-1152, 1970
8. Kosnik E, Paulson GW, Laguna JF: Postictal blindness. *Neurology* 26:248-250, 1976
9. Zung A, Margalith D: Ictal cortical blindness: a case report and review of the literature. *Dev Med Child Neurol* 35:917-926, 1993
10. Joseph JM, Louis S: Transient ictal cortical blindness during middle age: a case report and review of the literature. *J Neuro Ophthalmol* 15:39-42, 1995
11. Wong VC: Cortical blindness in children: a study of etiology and prognosis. *Pediatr Neurol* 7:178-185, 1991
12. Kermodé AG, Chakera T, Mastaglia FL: Low osmolar and non-ionic X-ray contrast media and cortical blindness. *Clin Exp Neurol* 29:272-276, 1992.
13. Hagerty C, Licho R, Recht L: Cortical blindness after correction of symptomatic hyponatremia: dynamic cerebral dysfunction visualised using serial SPECT scanning. *J Nucl Med* 36:1272-1274, 1995
14. Weinberger HA, van der Woude R, Maier HC: Prognosis of cortical blindness following cardiac arrest in children. *JAMA* 179:126-129, 1962
15. Sabah AH: Blindness after cardiac arrest. *Postgraduate Med J* 44:513-516, 1968
16. De Volder AG, Michel C, Guerit JM, Bol A, Georges B, de Barsey T, Laterre C: Brain glucose metabolism in postanoxic syndrome due to cardiac arrest. *Acta Neurol Belgica* 94:183-189, 1994
17. Fisher BM, Quin JD, Rumley A, Lennie SE, Small M, MacCuish AC, Lowe GDO: Effects of acute insulin-induced hypoglycaemia on haemostasis, fibrinolysis, and haemorheology in insulin-dependent diabetic patients and control subjects. *Clin Sci* 80:525-531, 1991
18. Wieczorek I, Pell ACH, Melver B, MacGregor IR, Ludlam CA, Frier BM: Coagulation and fibrinolytic systems in type 1 diabetes: effects of venous occlusion and insulin-induced hypoglycaemia. *Clin Sci* 84:79-86, 1993
19. Patronas NJ, Argyropoulou M: Intravascular thrombosis as a possible cause of transient cortical brain lesions: CT and MRI. *J Computer Assisted Tomography* 16:849-855, 1992
20. Gold AE, Deary IJ, Jones RW, O'Hare JP, Reckless JPD, Frier BM: Severe deterioration in cognitive function and personality in five patients with long-standing diabetes: a complication of diabetes or a consequence of treatment? *Diabetic Med* 11:499-505, 1994
21. Heller SR, Cryer PE: Reduced neuroendocrine and symptomatic responses to subsequent hypoglycemia after one episode of hypoglycemia in nondiabetic humans. *Diabetes* 40:223-226, 1991
22. Dagogo-Jack SE, Craft S, Cryer PE: Hypoglycemia-associated autonomic failure in insulin-dependent diabetes mellitus: recent antecedent hypoglycemia reduces autonomic responses to, symptoms of, and defense against subsequent hypoglycemia. *J Clin Invest* 91:819-828, 1993