

*W. John Martin*Center for Complex Infectious Diseases,
Rosemead, Calif., USA

Stealth Viral Encephalopathy: Report of a Fatal Case Complicated by Cerebral Vasculitis

Key Words

Encephalopathy
Encephalitis
Chronic fatigue
Stealth
Vasculitis

Abstract

A patient presenting with a severe subacute encephalopathy was shown to be infected with a stealth virus. Although the patient partially recovered, he remained lethargic with cognitive impairment and worsening headaches. Ten months after the onset of his illness, his clinical condition further deteriorated with seizures, coma and death. A brain biopsy revealed vacuolated degenerate neural cells consistent with a stealth viral encephalopathy. Focal perivascular lymphocytic inflammation was present within the leptomeninges and to a lesser extent within the parenchyma of the brain. Vasculitis may occasionally contribute to the complex symptomatology of stealth viral encephalopathy.

Introduction

Specialized viral cultures and sensitive molecular probe-based assays have identified stealth viral infections in patients with a wide range of neuropsychiatric dysfunctional brain disorders (information available at URL <http://www.ccid.org>). The spectrum of diseases seen in stealth viral-infected patients probably reflects the intensity and predominant localization of infection occurring within the brain. It may also be affected by secondary autoimmune responses directed against neural antigens, and by indirect effects on blood supply resulting from involvement of the brain's blood vessels. This paper describes the clinical and histological findings seen in a patient in whom a stealth viral infection was complicated by cerebral vasculitis.

Case Report

The 33-year-old Hispanic male was an outgoing, energetic individual working as a laborer. He had no prior significant medical history. Over a 2-week period in July 1993, he lost his appetite, complained of headaches and became depressed, irritable and reclusive. The day before hospital admission, he refused to eat, barely spoke and, what was said, was incoherent to his family. He became noncooperative and only reluctantly was persuaded to come to the emergency room of the Los Angeles County Hospital. He was considered to have a psychiatric illness but was admitted, under restraints, to a medical ward to 'rule out organic disease'. Although he was fully conscious when admitted, he became more somnolent over the next several days and progressed into coma. There were no localizing neurological signs. The patient was treated empirically with amphotericin B, flucytosine and acyclovir. Initial and subsequent CSF examinations were traumatic but indicative of a significant pleocytosis. The CSF white blood cell (WBC) counts per cubic millimeter were 128 on the day of admission, and 169, 60 and 17 on days 7, 12 and 19 post-admission. Polymorphonuclear (PMN) cells were seen on the samples collected on the day of admission and at day 7, constituting 29 and 7%, respectively, of the total WBC. At the time of admission, his

KARGER

E-Mail karger@karger.ch
Fax + 41 61 306 12 34
<http://www.karger.ch>© 1996 S. Karger AG, Basel
1015–2008/96/0642–0059\$10.00/0Dr. W. John Martin
Center for Complex Infectious Diseases
3328 Stevens Ave.
Rosemead, CA 91770 (USA)Received:
March 11, 1996
Accepted:
April 1, 1996

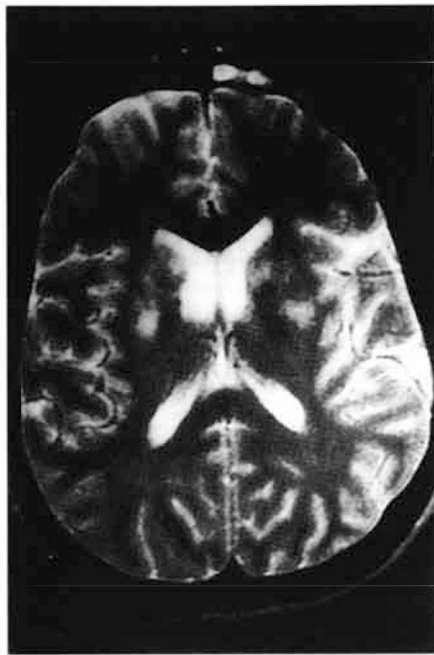

Fig. 1. T2-weighted MRI obtained during the first hospital admission of the patient. Multiple foci of abnormal high signal intensity can be seen within the basal ganglia. The T1-weighted MRI was essentially normal.

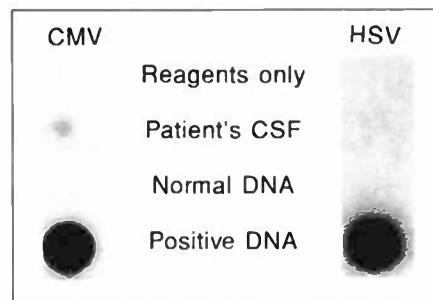


Fig. 2. The left-side panel shows the weak positive dot blot hybridization obtained on the patient's CSF using CMV-reactive primers and probe in a low stringency PCR assay. The right side panel shows the negative result using HSV-reactive primers. The positive controls were 1:100 dilutions of cultures infected with CMV and HSV, respectively. Uninfected cells were used as a source of negative DNA. The HSV primers and low stringency PCR conditions are as described [4].

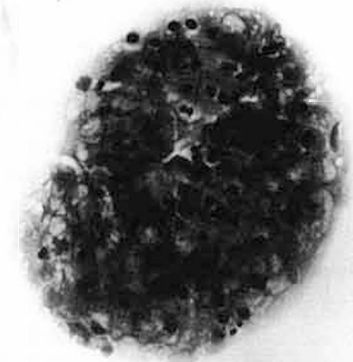


Fig. 3. CSF cytology showing a clump of cells with vacuolated cytoplasmic changes. $\times 400$.

peripheral blood WBC count was 11,900 with 77% PMN. The CSF protein level was 61 mg/dl on the day of admission (normal upper limit 50 mg/dl) and within normal limits at the other times of collection. His CSF IgG level was measured on the sample collected on day 19 postadmission and was slightly elevated (36 mg/dl). Moreover, electrophoresis showed weak but discernible oligoclonal banding [data not shown]. CSF glucose levels were normal at each time point. He had an elevated erythrocyte sedimentation rate of 28 mm (normal upper limit 20 mm) and a 1:40 antinuclear antibody titer showing a speckled pattern. The patient was HIV-negative. CSF cultures for fungal organisms, acid fast bacilli and conventional viruses gave negative results. Magnetic resonance imaging (MRI) was performed at 5 and at 19 days postadmission. Both studies showed multiple areas of abnormal high signal intensity within basal ganglia (fig. 1). These changes were seen in the T2-weighted, but not in the T1-weighted images. There was no meningeal enhancement. An EEG was interpreted as indicative of a mild encephalopathy consistent with a toxic, metabolic or infectious etiology. Specifically, it showed diffuse slow wave activity in the background plus intermittent polymorphic delta activity and occasional sharp waves over both temporal regions, mostly on the right side.

Polymerase Chain Reaction Studies

As shown in figure 2, a weak positive reaction was seen in a polymerase chain reaction (PCR) assay performed on the patient's CSF using a human cytomegalovirus (CMV) primer set and probe. The primers used were originally designed to amplify a region of the

CMV UL 83 gene (pp65 protein coding gene) between nucleotides 119,422 and 119,560 of the AD169 strain of CMV [1]. Under low stringency PCR conditions, these primers yield weak positive responses with other herpesviruses, including herpes simplex virus (HSV), human herpesvirus-6, varicella zoster virus and Epstein-Barr virus [2]. The primers have been used to detect a subset of stealth viruses [2, 3, unpubl. data]. The CSF sample gave a negative result using PCR primers reactive with the immediate early (I-E) gene of CMV [1] and with a primer set reactive with HSV (fig. 2).

Specialized blood cultures [4] were undertaken to test for the presence of a stealth virus. A vacuolating syncytial cytopathic effect, typical of that induced with other stealth viral isolates [4], developed on MRC-5 human fibroblasts, rhesus monkey kidney cells and Sf9 insect cells. The infected cells did not stain with antisera specific for human CMV I-E antigen [4]. Anomalous PCR products were, however, generated from the infected cultures using the broadly reactive CMV primers in a low stringency PCR assay [data not shown]. A CSF cytology sample, obtained on admission, was reexamined. Small clumps of atypical cells with foamy, vacuolated cytoplasmic changes were identified (fig. 3).

The patient's mental and physical condition gradually improved over the 3 weeks he spent within the County Hospital. He was transferred to a convalescent hospital where he continued to slowly improve over a 10-week period. He was discharged to the care of his family and instructed to report for outpatient rehabilitation therapy. The rehabilitation service, however, considered that he was mentally too disabled to benefit from therapy and advised him to wait for a

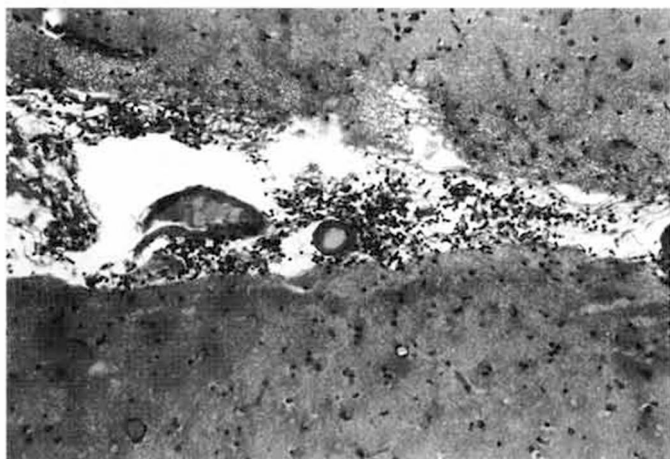


Fig. 4. A region of localized perivascular lymphocytic inflammation present within the leptomeninges of the brain biopsy. $\times 100$.

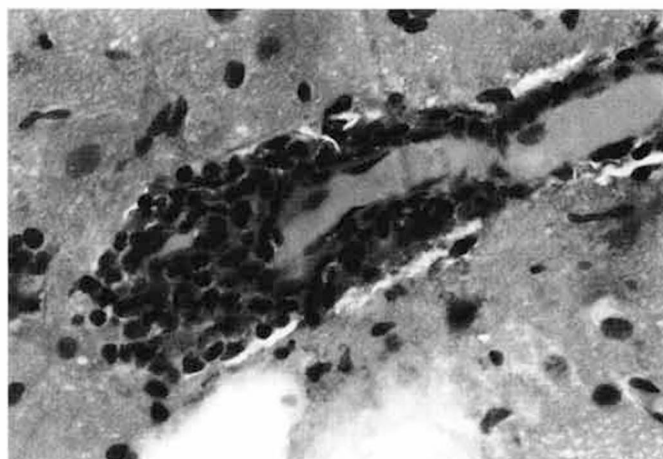


Fig. 5. Focal lymphocytic vasculitis involving a proportion of a cerebral blood vessel. $\times 400$.

more complete recovery. There was little or no improvement over the ensuing months. The patient showed little interest in outside activities and complained of severe fatigue, nervousness, increasing headaches and more generalized aches and pains. He slept for several hours each day and his major activity was to watch television without much comprehension. His memory of the days' events was impaired and he communicated poorly with his family. Ten months from the onset of his initial illness, his clinical condition acutely deteriorated. He no longer spoke to family members and one day became extremely listless and in apparent pain. The next morning he developed a generalized tonic-clonic seizure lasting 10 min which was controlled by Valium administered by paramedics. He was transported unconscious to a community hospital. The patient was comatose with residual contractions involving both eyelids. His CSF contained 17 erythrocytes, 21 WBC (76% lymphocytes, 13% polymorphs and 11% monocytes), protein 68 mg/dl and glucose 61 mg/dl. Two subsequent CSF taps showed no abnormalities. An MRI examination was reported as normal while a second MRI showed minimal evidence of cerebral atrophy and unremarkable minor aberrations in periventricular regions. No localizing signs were found on neurological examination. The patient awoke the next day but was aphasic and nonresponsive to attempted communications. His muscle tone was increased and although there was no voluntary movement, he would move in response to pain. His pupils responded sluggishly to light and his gag reflex was intact. Because of the prior history of probable encephalitis, a right temporal lobe brain biopsy was performed. The patient never regained consciousness and died in asystole 2 weeks after admission. An autopsy was not performed.

The brain biopsy showed a moderate, but patchy, perivascular lymphocytic inflammation affecting several of the blood vessels within the leptomeninges (fig. 4). The vasculitis was nongranulomatous and not associated with fibrinoid degeneration or hemorrhage. A small number of the blood vessels within the brain were also infiltrated with mononuclear cells (fig. 5). The larger blood vessels were generally only focally affected with nearby blood vessels remaining uninvolved (fig. 6). There was essentially no inflammation extending from the focal vasculitis into the parenchyma of the brain. Many of

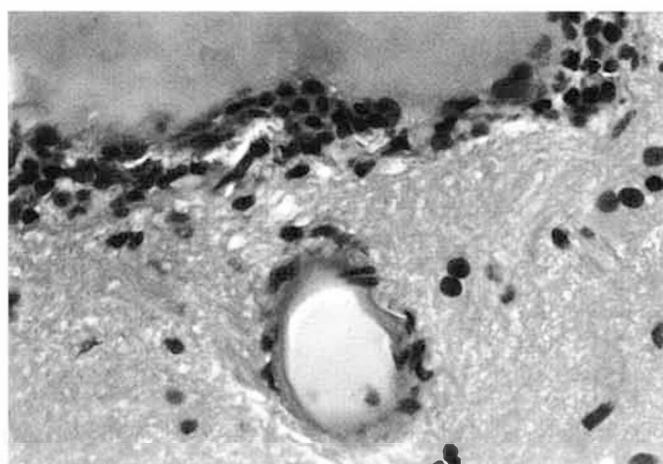


Fig. 6. Vascular inflammation affecting a cerebral blood vessel. An adjacent blood vessel remains relatively uninvolved in the inflammatory process. $\times 400$.

the neuronal cells showed evidence of a cytopathic effect with distorted nuclei and fine vacuolating cytoplasmic changes (fig. 7, 8). Electron microscopy was not performed.

Discussion

Viruses which can induce vacuolated foamy cell changes in fibroblast and kidney cell cultures have been cultured from patients with a wide spectrum of neurological and neuropsychiatric disorders [3–6]. Support for an etiological role in these diseases has been provided by the

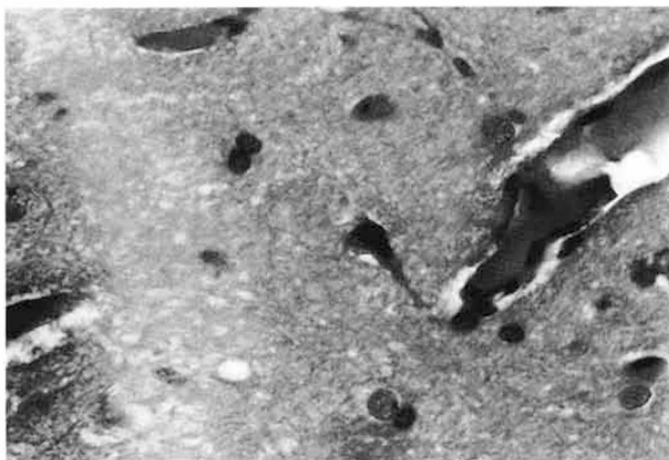


Fig. 7. A normal blood vessel in the vicinity of a cell with a degenerate nucleus and finely vacuolated cytoplasm. $\times 400$.

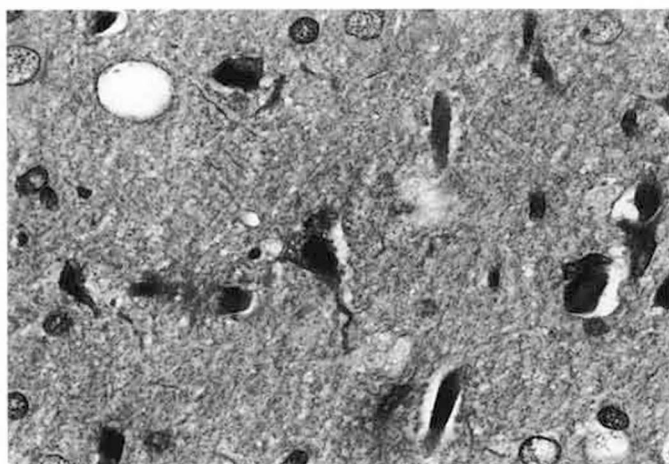


Fig. 8. A cell showing vacuolated cytoplasmic changes and a distorted degenerate nucleus seen within the brain biopsy. Nuclear changes are present in several additional cells seen in the section. $\times 400$.

demonstration of similar cellular changes in the brain of virus inoculated cats [7] and in the brains of severely ill, viral culture-positive patients [6]. These *in vivo* changes occurred in the absence of the marked inflammatory changes that normally accompany herpesviral encephalitis. Indeed, the paucity of inflammation led to the suggestion that the atypical viruses lacked the major immunogenic components required for effective T cell immunity. These viruses were provisionally termed 'stealth' because of their apparent ability to avoid effective immunity *in vivo*, and because they were not being recognized using

conventional viral culture procedures. Molecular studies have shown that some of the stealth viruses are derivatives of herpesviruses, most notably African green monkey CMV [8]. Sequencing studies have not been performed on the virus isolated from the patient described in this paper.

This patient is reported primarily because of the histologic evidence of an appreciable vasculitis, especially affecting leptomeningeal blood vessels. This finding was in addition to the characteristic distorted nuclear and vacuolated cytoplasmic changes seen in many of the neural cells. The vasculitis was not suspected clinically nor indicated by the MRI examinations conducted during the final hospital admission [9].

Cerebral vasculitis can occur in association with many types of viral infection [10] and may be explained by several mechanisms, including: (1) egress of cells from the vasculature into the tissues in response to immunogenic viral or modified self antigens expressed on viral-infected parenchymal cells; (2) response to antigen-antibody complexes formed between circulating antibodies and the viral antigens diffusing from the infected tissues, and (3) direct viral infection of the blood vessel causing a disruption of the endothelial barrier function preventing lymphocyte adhesion and invasion. The patchy nature of the vasculitis and the involvement of varying-sized blood vessels tend to argue against major roles for the first two mechanisms. CMV has a propensity to infect blood vessels [11] and certain stealth viruses might be expected to show the same potential.

Cerebral vasculitis is commonly diagnosed, with or without angiographic confirmation, on the basis of recurrent seizure activity, headaches and transient neurological deficits [9]. Clinically, it often responds to steroid and/or antimetabolite therapy such as cytoxan or methotrexate [12]. Although a vasculitis is not a necessary component of stealth viral infection, it does help explain the seizure which led to the patient's final hospitalization. Earlier vascular changes may also explain the rather striking basal ganglia MRI findings seen on the initial hospitalization. The potential contribution of an accompanying vasculitis to severe stealth viral infections is currently being addressed in other patients.

Acknowledgements

I wish to thank Dr. P. Colletti and Dr. S. Martin for the MRI and CSF cytology photographs.

References

- 1 Shibata D, Martin WJ, Appleman MD, et al: Detection of cytomegaloviral DNA in peripheral blood of patients infected with human immunodeficiency virus. *J Infect Dis* 1988; 158:1185-1192.
- 2 Martin WJ: Detection of viral related sequences in CFS patients using the polymerase chain reaction; in Hyde B (ed): *The Clinical and Scientific Basis of Myalgic Encephalomyelitis/Chronic Fatigue Syndrome*. Ottawa, Nightingale Res Found, 1992, pp 278-282.
- 3 Gollard RP, Mayr A, Rice DA, Martin WJ: Herpesvirus-related sequences in salivary gland tumors. *J Exp Clin Cancer Res* 1996;15: 1-4.
- 4 Martin WJ, Zeng LC, Ahmed K, Roy M: Cytomegalovirus-related sequences in an atypical cytopathic virus repeatedly isolated from a patient with the chronic fatigue syndrome. *Am J Pathol* 1994;145:440-451.
- 5 Martin WJ: Stealth virus isolated from an autistic child. *J Autism Dev Disord* 1995;25:223-224.
- 6 Martin WJ: Severe stealth virus encephalopathy following chronic fatigue syndrome-like illness: Clinical and histopathological features. *Pathobiology* 1996;64:1-8.
- 7 Martin WJ, Glass RT: Acute encephalopathy induced in cats with a stealth virus isolated from a patient with chronic fatigue syndrome. *Pathobiology* 1995;63:115-118.
- 8 Martin WJ, Ahmed KN, Zeng LC, Olsen JC, Seward JG, Seehrai JS: African green monkey origin of the atypical cytopathic 'stealth virus' isolated from a patient with chronic fatigue syndrome. *Clin Diagn Virol* 1995;4:93-103.
- 9 Harris KG, Tran DD, Sickels WJ, Cornell SH, Yuh WTC: Diagnosing intracranial vasculitis. The roles of MR and angiography. *Am J Neuroradiol* 1994;15:317-330.
- 10 Jennette JC, Falk RJ: Update on the pathobiology of vasculitis. *Monogr Pathol* 1995;37: 156-172.
- 11 Golden MP, Hammer SM, Wanke CA, Albrecht MA: Cytomegalovirus vasculitis. Case reports and review of the literature. *Medicine* 1994;73:246-255.
- 12 Calabrese LH, Duna GF: Evaluation and treatment of central nervous system vasculitis. *Curr Opin Rheumatol* 1995;7:37-44.