

The physiological response to hypothermia is controlled by the hypothalamus, involving peripheral vasoconstriction and shivering. In hypothalamic hypothermia these systems fail with loss of reactive peripheral vasoconstriction to reduce heat loss and loss of the shivering response to produce heat. It is the failure of these systems that contributes to the hypothermia and also produces diagnostic difficulty, with the patient feeling warm to the touch and not shivering. The ECG showing the pathognomonic J waves, with absence of shiver waves mirrored the hypothalamic cause of the hypothermia.

This is the first description of hypothermia in a patient with multiple sclerosis with a proved hypothalamic plaque and no other identifiable cause for hypothermia.

We thank David Hughes for the preparation of the histopathological photographs.

S EDWARDS  
G LENNOX  
K ROBSON  
A WHITELEY  
Department of Neurology,  
Queen's Medical Centre, Nottingham

Correspondence to: Dr S Edwards, Department of Academic Neurology, Queen's Medical Centre, Nottingham, NG7 2UH, UK.

- 1 Benarroch EE. The central autonomic network: functional organisation, dysfunction, and perspective. *Mayo Clin Proc* 1993;68:988-1001.
- 2 Geny C, Pradat PF, Yulis J, Walter S, Cesaro D, Degos JD. Hypothermia, Wernicke's encephalopathy and multiple sclerosis. *Acta Neurol Scand* 1992;86:632-4.
- 3 Sullivan F, Hutchinson M, Bahandeka S, Moore RE. Chronic hypothermia in multiple sclerosis. *J Neurol Neurosurg Psychiatry* 1987;50:813-5.
- 4 Lammens M, Lissioir F, Carton H. Hypothermia in three patients with multiple sclerosis. *Clin Neurol Neurosurg* 1992;91:117-21.
- 5 Ghawche F, Destee A. Hypothermie et sclérose en plaques. Un cas avec trois épisodes d'hypothermie transitoire. *Rev Neurol Paris* 1990;146:767-9.

### Lyme neuroborreliosis presenting with propriospinal myoclonus

A 60 year old white woman presented with an erythema migrans after a tick bite on the right thigh on 11 July 1995. On 2 October 1995, she complained of a lumbar pain which radiated to the right thigh. She received dextropropoxyphene, paracetamol, thiocholchicoside, and tetrazepam and then was additionally treated with codeine, chlormezanone, and tenoxicam. Despite this, the pains, which prevented sleep, rapidly radiated bilaterally to the low back and the abdomen. On 11 October 1995 she presented with flexor non-rhythmic symmetric jerks of the trunk, the abdomen, both hips, and knees evident both sitting and standing, increasing when lying, without suppression by an effort of will or during voluntary movements. Although the pains and jerks were atypical, the patient was diagnosed as having a herniated disc; an epidural infiltration of dexamethasone (10 mg) gave a transient relief of the pains and jerks. A second infiltration was not effective. On 13 October the patient was admitted to hospital. The myoclonic jerks had reinforced, occurring sometimes in bursts, occasionally involving the neck and the shoulders but never the face. The patient was agitated and exhausted, and cried on account of the continuous distressing pains. She was free of

headache and fever. Walking was difficult, although she felt better when standing. She had a mild motor deficit in the proximal part of the lower limbs, patellar tendon reflexes abolished on the right, diminished on the left, normal ankle reflexes, plantar reflexes flexor, and axial muscles and neck were not rigid. Results from routine laboratory investigations were normal. Ketoprofene, haloperidol, clorazepate, and then tiaprid, paracetamol, and buprenorphine were tried with negligible relief. On 19 October, she was transferred to the intensive care unit. The painful jerks were flexor, simultaneous in all the muscles, and spontaneous or induced consistently by flexion of the neck, without involvement of the face and superior limbs. The intervals between the jerks became so short that the paroxysms gave the impression of being attacks of sustained truncal flexion. An EEG during jerking was unremarkable. Finally, the patient was anaesthetised and ventilated artificially. The treatment was propofol, fentanyl, and muscle relaxant pancuronium. Ceftriaxone (2 g intravenously daily) was given for 14 days. The CSF contained 398 mononuclear cells/ $\mu$ l, numerous atypical cytological features, normal glucose and chloride ratios, increased protein content (1.2 g/l), intrathecal synthesis of IgG and IgM, and three oligoclonal bands were detected. The titre of antibodies to *Borrelia burgdorferi* was raised in the CSF (1/64: normal < 1/4) by indirect immunofluorescence, both for IgM (1/16) and IgG (1/16), 1.352 (normal < 0.16) by enzyme linked immunosorbent assay (ELISA) (Immunowell borrelia Lyme—BMD); their detection in serum was negative three weeks later. On 22 October the patient was extubated. The jerks had totally disappeared and the pains dramatically improved. At this time, EMG failed to detect any myoclonic jerks. Recording of peroneal nerve somatosensory evoked potentials and MRI of the spine were unremarkable. On 24 October, the patient was free of pain and then recovered full strength and normal tendon reflexes.

The clinical features of pain resistant to analgesic agents,<sup>1</sup> meningoradiculitis with a history of tick bite, and erythema migrans strongly evokes a Lyme neuroborreliosis confirmed by the CSF findings and detection of antibodies to *Borrelia burgdorferi*.<sup>2</sup> However, the most dramatic feature was the myoclonic jerks which support the clinical diagnosis of propriospinal myoclonus characterised by repetitive, non-rhythmic jerks of the neck, trunk, both hips, and knees.<sup>3</sup> Sometimes attacks of sustained truncal flexion are generated by paroxysmal bouts of axial jerks.<sup>4</sup> In this type of myoclonus, the discharge arises from a limited segment of the spinal cord and then spreads slowly up and down by the involvement of the long propriospinal pathways.<sup>3</sup> The jerks had disappeared at the time of the EMG investigation in our patient. Accordingly, we could not ascertain the possible origin in the thoracic segment of the spinal cord, corresponding to the abdominal and lumbar muscles, which were painful throughout the course of the disease and constantly affected by the jerks. To our knowledge, no case of Lyme neuroborreliosis has been associated with a propriospinal myoclonus. Another patient had stiffness, painful cramps, and spasmodic jerks confined to the left leg,<sup>5</sup> which suggest a localised myelitis of the spinal interneurons. Our own strongly evokes the involvement of many spinal seg-

ments. Apart from the myoclonus, no other evidence of spinal cord disease was apparent. The treatment of the *Borrelia* rapidly relieved the pain and dramatically suppressed the myoclonus.

V DE LA SAYETTE  
S SCHAEFFER  
C QUERUEL  
F BERTRAN  
G DEFER  
Service de Neurologie  
P HAZERA  
E GALLET  
Service de Réanimation médicale et maladies  
infectieuses, CHU Caen, France

Correspondence to: Dr V de la Sayette, Service de neurologie, CHU Côte de Nacre F 14033 Caen cedex, France.

- 1 Viader F, Poncet AM, Chapon F, et al. Les formes neurologiques de la maladie de Lyme. *Rev Neurol* 1989;145:362-8.
- 2 Stiernstedt GT, Granstöm M, Hedrstedt B, Sköldenberg B. Diagnosis of spirochetal meningitis by enzyme-linked immunosorbent assay and indirect immunofluorescence assay in serum and cerebrospinal fluid. *J Clin Microbiol* 1985;21:819-25.
- 3 Brown P, Thompson PD, Rothwell JC, Day BL, Marsden CD. Axial myoclonus of propriospinal origin. *Brain* 1991;114:197-214.
- 4 Brown P, Thompson PD, Rothwell JC, Day BL, Marsden CD. Paroxysmal axial spasms of spinal origin. *Mov Dis* 1991;6:43-8.
- 5 Martin R, Meinck HM, Schulte-Mattler W, Ricker K, Mertens HG. *Borrelia burgdorferi* myelitis presenting as a partial stiff man syndrome. *J Neurol* 1990;237:51-4.

### Metamorphopsia and visual hallucinations restricted to the right visual hemifield after a left putaminal haemorrhage

Metamorphopsia is a rare neurological phenomenon in which objects appear distorted in form. Many reports have attributed the responsible lesion to the occipitoparietal cortex and its related structures.<sup>1-4</sup> We report a case of left putaminal haemorrhage followed by metamorphopsia and visual hallucinations restricted to the right visual hemifield. The origin of this patient's symptoms was considered to be the left optic radiation.

A 63 year old right handed man with a previous history of hypertension was admitted to the hospital with acute right hemiparesis. On admission, his visual field examination showed a right homonymous hemianopia. There was also a right inferior facial palsy and a right hemiparesis without sensory involvement. The right homonymous hemianopsia disappeared on the third day. On the fourth day, he complained that the doctor's left cheek seemed to have been scraped, that the doctor's left hand seemed tortuous, and that some of the fingers of the hand seemed to be missing. He drew a picture of what he saw (fig 1A). Visual field examination by confrontation was immediately performed but no abnormalities were found, later confirmed by using Goldmann's perimeter. On the next day, he complained, "The right half of the curtain in front of me suddenly transforms into an animal's face. It rotates there for a while and finally flows to the right, and then disappears. At the next moment, another face springs up at the very portion and . . ." He then drew a picture to illustrate his experience (fig 1B). These phenomena lasted three to four days and then disappeared. One month later, he was able to walk without assistance and was discharged from hospital.

The laboratory analysis of blood and urine was within the normal range. Cranial CT on admission showed a left putaminal haemorrhage without ventricular extension

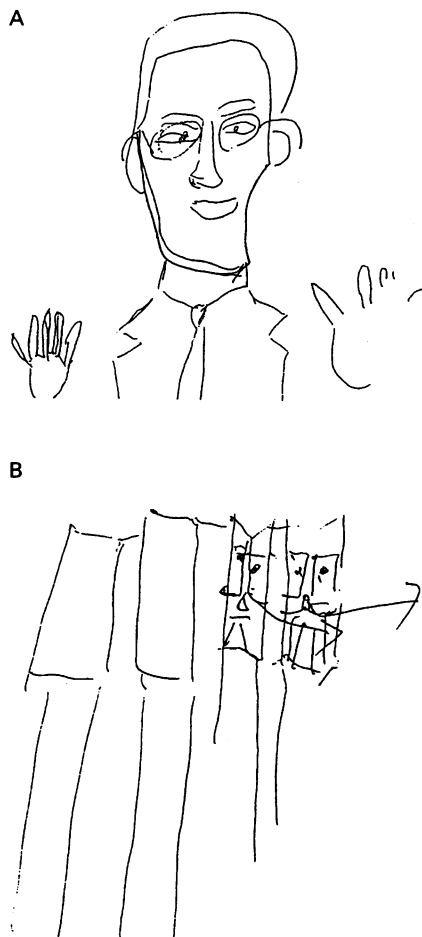


Figure 1 (A) Drawing of the referring doctor's face. His left cheek seemed to have been scraped and some of his left fingers were missing. (B) A drawing of the curtain lace. A fold of the lace seemed to have been transformed into an animal's face and it seemed to flow to the right.

or mass effect in either the occipital or parietal lobes (fig 2). In the pattern shift visual evoked potential (VEP), the latency of the P100 during right visual hemifield stimulation was 112.4 ms, which was moderately delayed compared with 98.0 ms, the latency recorded during stimulation of the left visual hemifield, indicating the involvement of the left visual pathway posterior to the optic chiasm.

Many reports have attributed the lesion of metamorphopsia to the occipitoparietal cor-

tex and its related structures.<sup>2,4,8</sup> However, others have reported that chiasmatic<sup>5</sup> or retrosplenial lesions<sup>6,7</sup> could elicit this symptom. This patient had a common putaminal haemorrhage without involvement of the parietal and occipital lobes, as confirmed by cranial CT. The results of the VEPs disclosed a lesion in the left visual pathway posterior to the optic chiasm. Thus the lesion responsible for his visual symptoms is in the left optic radiation. This is the first report that such a lesion could cause metamorphopsia. Based on the above mentioned reports and our own patient, we propose that any lesion along the visual pathway, from the retina to the occipitoparietal cortex, can cause metamorphopsia. Retinal lesions elicit ipsilateral monocular metamorphopsia, chiasmatic lesions give rise to bitemporal metamorphopsia,<sup>5</sup> and occipitoparietal lesions cause contralateral homonymous metamorphopsia.<sup>2,8</sup> This patient with injury in the left optic radiation complained of contralateral homonymous metamorphopsia. The distributional pattern of metamorphopsia seems to correspond to the part of the visual pathway affected.

K SHIGA  
M MAKINO  
Y UEDA  
K NAKAJIMA

Department of Neurology, Kyoto Prefectural University of Medicine, Kyoto, Japan

Correspondence to: Dr Kensuke Shiga, Department of Neurology, Kyoto Prefectural University of Medicine, 465 Kajicho Hirokoji-Kawaramachi, Kamigyo-ku, Kyoto, Japan.

- 1 Miller NR, Walsh and Hoyt's clinical neuro-ophthalmology, 4th ed. Vol I. Baltimore: Williams and Wilkins, 1982, 166-7.
- 2 Mooney AJ, Carey P, Ryan M, et al. Parasagittal parieto-occipital meningioma with visual hallucinations. *Am J Ophthalmol* 1965; 59:197-205.
- 3 Nass R, Sinha S, Solomon G. Epileptic focal metamorphopsia. *Brain Dev* 1985;7:50-2.
- 4 Young WB, Heros DO, Ehrenberg BL, et al. Metamorphopsia and palinopsia. *Arch Neurol* 1989;46:820-2.
- 5 Bender M, Savitsky N. Micropsia and teleopsia limited to the temporal fields of vision. *Arch Ophthalmol* 1943;29:904-8.
- 6 Ebata S, Ogawa M, Tanaka Y, et al. Apparent reduction in the size of one side of the face associated with a small retrosplenial haemorrhage. *J Neuro Neurosurg Psychiatry* 1991;54: 68-70.
- 7 Imai N, Nohira O, Miyata K, et al. A case of metamorphopsia caused by a very localized spotty infarct. *Clin Neurol* 1995;35:302-5.
- 8 Cohen L, Gray F, Meyrignac C, et al. Selective deficit of visual size perception. *J Neurol Neurosurg Psychiatry* 1994;57:73-8.

#### Cardiac autonomic regulation during sleep in panic disorder

Panic disorder is thought to be associated with a dysfunction of the autonomic nervous system. Power spectrum analysis has been used recently to quantify spontaneous variability in heart rate in humans. Some authors have detected patterns of cardiovascular responsivity in panic disorder that can be interpreted in favour of sympathetic overactivity<sup>1</sup> or cholinergic underactivity.<sup>2,3</sup> These studies were performed during wakefulness and the result may reflect states of increased anxiety. During sleep there are repetitive modifications of the autonomic nervous system that are constant and not influenced by cognitive factors. In the present study, we used power spectrum analysis of the heart rate variation during sleep in patients with panic disorder to verify a possible intrinsic defect in the autonomic regulation in this disorder.

We studied 10 patients with panic disorder (mean age 29.5 (range 23-35) years) and 10 age matched healthy controls (mean age 27.5 (range 24-34) years). Controls were recruited from the sleep laboratory technicians. Patients satisfied criteria for a diagnosis of panic disorder according to DSM-IV. Protocol exclusion criteria included: (a) a history of major medical or neurological illness; (b) a history of sleep panic attacks; (c) current or past evidence of affective disorders; (d) use of psychotropic drugs in the two weeks before the study. All subjects underwent a 48 hour ambulatory polysomnography (Oxford Medilog 9200). The ECG signal was played back from the tape and digitised at 128 Hz with 8 bit resolution using a specific option of the Medilog system. The R-R intervals were detected by means of a derivative-threshold algorithm; the accuracy of the R wave detection on ECG tracing was improved by fitting each QRS complex by a second order polynomial function. The fiducial point on the ECG was taken as the maximum of the fitting parabola to reduce the error due to the low sampling rate.<sup>4</sup> The heart rate variability signal was processed using an autoregressive algorithm.<sup>5</sup> All the spectral calculations were performed on all the successive 300 second segments of ECG recordings of the second night. The analysed time intervals were chosen from: (a) awake state at the beginning of the night; (b) stage 2 non-REM sleep; (c) stages 3-4 non-REM sleep; (d) REM sleep. We focused on two regions of interest in the spectrum: (1) the low frequency (LF) component 0.05 to 0.15 Hz: an increase of the power in this band is commonly associated with sympathetic activation; (2) the high frequency (HF) component 0.2 to 0.4 Hz, mainly expression of parasympathetic control. The following variables were evaluated: the R-R mean and variance, the power of LF and HF components, and the sympathovagal balance (LF/HF ratio). We analysed the normalised spectral component (ratio between the power density of each spectral component and the total spectral density minus the power in the band 0-0.05 Hz) as better measures of the autonomic activity in respect to the absolute numbers; in this way it is possible to remove the effects of the large variability in the total power measures among the several subjects.<sup>5</sup> We applied ANOVA to determine the changes within each group through the different conditions. Differences between the two groups were evaluated by unpaired two tailed Student's *t* test.

Concerning sleep architecture, no difference was found in the percentages of all sleep stages between patients with panic disorder and controls (values are mean (SD)): stage 1 non-REM sleep 4.5 (2) v 3.9 (2.7); stage 2 non-REM sleep 49.8 (6.2) v 51.7 (7.4); stages 3-4 non-REM sleep 20.6 (8) v 18.8 (6.7); REM sleep 25.1 (6.8) v 25.5 (3.6). No difference was found in the number of analysed segments in each sleep stage between the two groups.

Mean R-R showed, both in patients with panic disorder and controls, a trend towards an increase in all sleep stages compared with wakefulness before sleep. No difference was found in R-R mean and variance between patients and controls in the various conditions. The LF component (sympathetic activity) decreased during sleep with minimal values during stages 3-4 non-REM sleep, whereas the HF component (parasympathetic activity) displayed a reciprocal

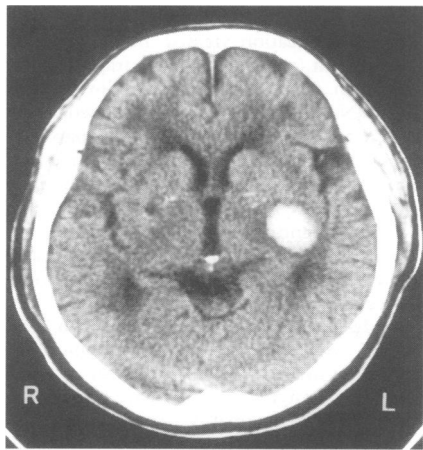


Figure 2 Cranial CT on admission, showing a high density area in the left putamen.