

J. Ghika
J. Bogousslavsky
F. Ghika-Schmid
F. Regli

“Echoing approval”: a new speech disorder

Received: 26 January 1996
Received in revised form: 17 May 1996
Accepted: 18 June 1996

Abstract We report the cases of two patients presenting a peculiar speech disorder, which we have named “echoing approval”, in which the patients echo, in replying to questions in a dialogue with short phrases, the positive or negative syntactical construction of a question, or its positive or negative intonation, but without any repetition of whole or part of sentences. When asked about their symptoms, the patients replied 80% of the time with “yes, yes”, “that’s right”, or “exactly” to positive questions and “no, no” or “absolutely not” to negative questions, regardless of their actual symptoms and oblivious to self-contradiction. In addition, when the examining doctor was speaking to a medical colleague in the patient’s presence and using medical terminology that the patient did not understand, he/she agreed or disagreed with any sentence and technical word uttered in a way entirely dependent on the syntax or intonation used. To distinguish this speech disorder from echolalia or verbal perseverations, with which it may be superficially confused, we suggest that it be called “echoing approval”, as it may be part one of the manifestations of the environment-

dependency syndrome. This clinical picture was found to be associated with features of transcortical motor aphasia and frontal lobe signs. One patient had a bilateral callosal frontal malignant glioma and the other a probable multiple system atrophy with global deterioration, pre-eminent frontal release signs, diffuse leukoencephalopathy and multiple lacunes. On the basis of these clinical deficits and neuroimaging features, we are unable to delineate the common, or minimal, lesioned network required for this symptomatology to occur, especially in the absence of a series of patients, and with such a difference in both the location and causes of the lesions. However, bilateral frontosubcortical dysfunction was pre-eminent in the clinical picture in both patients, even though more diffuse brain pathology was seen in one, and it might be speculated that dysfunction of the bilateral orbitofrontal and frontomesial motor frontosubcortical circuits might be involved in the aetiology of this peculiar speech disorder.

Key words Echoing · Speech · Fronto-subcortical circuit · Environment dependency

J. Ghika (✉) · J. Bogousslavsky
F. Ghika-Schmid · F. Regli
Department of Neurology, CHUV,
CH 1011 Lausanne, Switzerland
Fax: 41 21 3145520

Introduction

Echolalia is generally found as part of the clinical picture of transcortical aphasia and may be due to a lesion in the posteromedian frontal lobe including the supplementary motor area (SMA) [1, 2]. In the general concept of echolalia, sentences, or fragments of sentences, are echoed, and it is hardly, if at all, possible to evaluate verbal understanding. Associated signs are forced grasping and other compulsory phenomena, like utilization behaviour, echopraxia, and frontal release reflexes. We report two patients with different lesions and clinical presentations, who employed an echoing technique in dialogue with the examiner. The patients were examined by experienced neuropsychologists, who mentioned "perseverations" and "difficulty in understanding" in their description of both patients' speech. Echoing, as a concept, has been approached in studies of speech in autistic children [3-7], but has never been reported per se in adults with aphasia, probably because insufficient attention is paid to this form of speech, which may superficially be mistaken as a problem of understanding, perseveration or echolalia.

Case reports

Patient 1 was a 62-year-old right-handed secretary, with the psychological profile of an obsessively efficient and polite person, with broad general knowledge, who was referred to a doctor because of recent changes in her personality and work efficiency.

At the beginning of April 1992, her coworkers noticed that she was sometimes inefficient at work, making errors, missing out words and having difficulty in understanding orders. She was unaware of any change in either her personality or behaviour, but complained of headaches and forgetfulness.

On neurological examination, the cranial nerves and fundi were normal, with no facial asymmetry, orolinguofacial apraxia and no abnormal cranial reflexes. The rest of the neurological examination was normal, except for an indifferent Babinski sign on the left, and intermittent extension on the right.

A neuropsychological examination was performed using a standard battery of tests, and the patient's scores compared with those for our own population matched for age, gender, level of education and first language [8]. The patient was alert, oriented and with normal attention scores, as assessed by a normal digit span. Spontaneous expression was extremely poor, and she would not talk unless prompted. When speaking, she experienced great difficulty in finding words, but was otherwise fluent; a severe naming impairment was found on a shortened translation of the Boston Naming test [8]. There was no agrammatism, no paraphasias, normal prosodia, good articulation, and no jargonaphasia, but she stuttered at times. She could understand three-step orders and positive, negative and passive sentences without difficulty. Repetition was well preserved. She could read fluently; although her recall of the text was poor, there was no confabulation. Her spelling was unimpaired in a forwards direction but severely impaired in a backwards direction. Her writing was normal and she understood words, logatomes, and sentences without difficulty. She had no constructional or ideomotor apraxia of the right hand, but some degree of apraxia of the left hand on verbal command, suggestive of callosal disconnection. Gnosias and visuoperceptive skills (Poppeleuter's embedded figures, mute map, and recognition of famous faces) were intact. The Rey Auditory Verbal learning test

was impaired for recognition, with delayed evocation with scores in the lower range of the norm. She had massive frontal signs, such as bilateral grasp, utilization behaviour of any object presented to her (a purse, a wallet, a telephone, a pen, a glass...), echomimia, echopraxia, and massive failure of the Stroop test, deficient inhibition of inappropriate responses on a go-no go task, failure to sustain Luria's alternating tasks for both graphic and hand gestures, and decreased verbal fluency, both in the "M" and "animal" categories.

When asked about her symptoms, the examiner (J.G.) was surprised to receive echoing replies to his questions. For example, the dialogue would go as follows (it should be explained that translation into English places an apparent contradiction between the syntax of the question and the reinforcing "do you" or "don't you", which does not exist in French):

"You don't have any trouble speaking, do you?"

"No, no".

"You don't have trouble finding words, do you?"

"No, no. I can find them easily...sometimes, at night, Mr er... you know, sometimes at night, it gets mixed up..."

"Have you noticed any change in your speech?" (purposeful negative intonation)

"No, no".

"But you have noticed that your speech has changed, haven't you?"

"Yes, yes, oh... yes".

"You do have headaches, don't you?"

"Yes, yes, headaches, very bad headaches..., yes, yes".

"But you just told me you don't have any headaches".

"No, no... no headaches".

"You do know what headaches mean, don't you?"

"Yes, yes headaches, pain in the head, yes, yes.... I have very, very bad headaches since... er, since..."

"Do you know what I mean when I say: Kto Ia gavaril (positive intonation)?"

"Yes, kagayavari, yes yes..., yes. I understand very well what it means, yes, yes".

"Do you know what it means (negative intonation)?"

"No, no, I've no idea what it means, but I can repeat it".

The examiner then turned to another physician and they discussed her case, while she was sitting between them. One of the physician says: "We were impressed by the peculiar type of aphasia...".

She says "Yes, yes...yes, exactly, yes, yes".

"... and we thought she had some kind of transcortical, predominantly motor aphasia..."

"Yes, yes, exactly, that's it..."

"...with no phonemic or semantic paraphasia..."

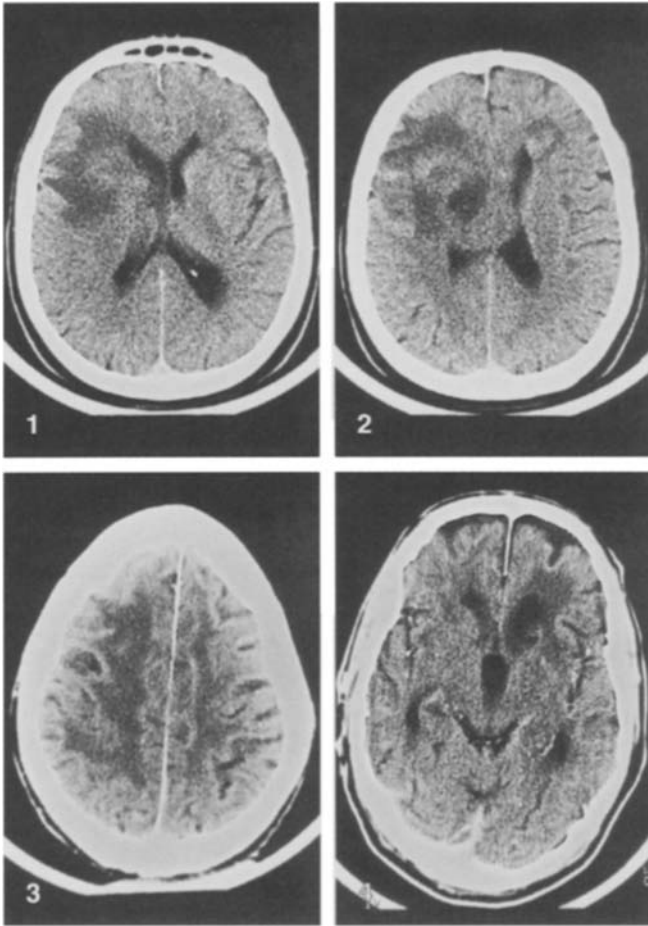
"No, no, absolutely not..."

"...the only abnormal physical signs were bilateral grasping, echopraxia, and a right Babinski..."

"Yes, yes, that's right..., exactly..."

CT showed a multilobate bilateral frontal expanding process in the right paramedian subcortical frontal region and caudate nucleus, involving the anterior part of the corpus callosum, the subcortical white matter of the left frontal lobe and the caudate nucleus on the right side, which was diagnosed as glioblastoma after stereotaxic biopsy.

Patient 2 was a 71-year-old right-handed, retired highly qualified worker with obsessional politeness and much self-control, who was referred to our movement disorder unit because of intellectual deterioration and trouble with balance and gait. The patient was



Figs. 1, 2 Patient 1. CT scan: infiltrative lesion of the right frontal lobe, striatum, and corpus callosum (glioblastoma)

Figs. 3, 4 Patient 2. CT scan: diffuse leukoencephalopathy with small infarcts in the basal ganglia, especially in the left striatum (Binswanger's disease?)

unaware of the severity of his condition, except for some forgetfulness and trouble with balance. In his past history there was left pulmonary lobectomy for a carcinoid tumour in 1972, parathyroidectomy for benign adenoma in 1988, diabetes and hypertension, but he was not diagnosed as having multiple endocrine neoplasia syndrome.

He was seen by a neurologist in 1990 for generalized tremor of both hands, head and legs, clumsiness of the hands and loss of balance with multiple falls, freezing, and difficulty in changing direction and apraxia in all axial movements, such as rolling over in bed and getting up from a chair. Handwriting was reduced to his signature, and the fastening of buttons, cutting of meat, shaving and brushing teeth were extremely slow and difficult. He had noticed memory problems and had given up driving and let his wife handle the finances and help him in his daily life. He also complained of autonomic dysfunction with xerostomia and profuse sweating at night. He was depressed, with a feeling of a loss of energy, but there was no sleep disorder or change in appetite. He was taking levodopa-benserazide 725 mg q.i.d. without improvement, but he was never confused or hallucinated. On physical examination, he was alert, with no fluctuation in vigilance, disoriented in time and space and anosognosic of most of his condition. There was upgaze

limitation and fractionated pursuit, but no nystagmus or saccadic oscillation. There was no amimia, hypophonia, or corticobulbar signs. The blinking rate was normal and there was no facial hyperkinesia. Abnormal nasopalpebral and snout reflexes were elicited. Both upper and lower extremities showed increased tone, with cogwheeling, but no brady- or hypo-kinesia. Stereotypia, with compulsive hand-rubbing, was present. Reflexes were all brisk, with bilateral Hoffmann and Babinski signs; there were no cerebellar ataxic features except an important postural tremor, and no signs of peripheral motoneuron involvement. On walking, after hesitating for a long time (up to 20 s), he took very short steps, with an intermalleolar distance of 30 cm, feet glued to the floor, without armswing, and with major instability, retropulsion, 4+ en bloc turning, freezing and festination of the feet. Some athetosis and dystonia was visible on both sides.

On neuropsychological examination, this right-handed retired man was found to have fluctuations in attention, with digit and verbal spans within the lower range of the norm. He had a severe lack of speech initiation, had to be prompted to say short, mainly stereotyped sentences, with occasional phonemic and semantic paraphasia. He had no agrammatism, no dysarthria, and no jargonaphasia. Repetition was well preserved. Spelling was impaired, both forwards and backwards. His performance on the Boston Naming test was within the lower limits (Lim-C20). Automatic series were possible in their normal order but only partially in the reverse order. He had some difficulty in repeating logatomes (2/5 for trisyllabic, and 1/5 for polysyllabic), but no problem in understanding even complex three-step oral or written orders, but his comprehension of passive and negative sentences was impaired. He could write (with micrography), with some letters missing or added and dysorthographia. He had occasional paralexia when reading. He could perform simple oral calculations, but no complex written procedures. He had constructional apraxia, difficulty in reproducing gestures of no special significance and mild ideomotor and bucolingual apraxia. His discrimination of embedded figures (Poppelreuter) was poor, as was his orientation on the mute map. Colour matching, naming and designation were normal. He had difficulty in recognizing famous faces, and left/right confusion when looking at the examiner. The auditory verbal learning test was below the normal range for learning, recognition, and delayed evocation. He had severe impairment of executive functions with decreased verbal fluency (1/min), failure to sustain Luria's alternating tasks (hand gesture and graphic pattern), impaired go-no go task, and operatory reasoning. When an object was presented, he would rush towards it, and manipulate it, even if asked not to do so. Such utilization behaviours would be seen when he was put in front of a telephone, a pen, a glass of water or a toothbrush, for example. He also had echomimia, echopraxia, visual grasping of mirror, TV sets and patients passing by and "verbal perseveration". On detailed examination, however, the patient would echo the questions of the examiner to a point where it was almost impossible to take a valid history. An example of a dialogue with the patient would go as follows:

"Mr X..., do you have any headaches?"

"No, no".

"But you did tell me you had headaches, didn't you?"

"Yes, yes, that's right".

"Do you know what headache means?"

"Oh yes, yes... pain in the head, yes, yes".

"Do you have any pain anywhere in your body?"

"No, no pain...never".

"Do you sometimes have cramps?"

"Exactly...".

"Real cramps, such that your muscle gets hard and hurts a lot?"

"Yes, cramps, I have cramps".

"Where?"

"In the calf, cramps, yes".
 "But you don't have cramps, do you?"
 "No,...no".
 "You know what cramps are, do you?"
 "Yes, yes, cramps, like a big pain in your calf, yes, I have cramps".
 "But you just told me that you don't?"
 "No, not even...".
 "Your main problem right now is balance, isn't it?"
 "Exactly...".
 "Balance and gait, you understand what I am saying, don't you?"
 "Yes, yes, walking, running...".
 "And you said that you don't have problems walking, do you?"
 "Exactly...".
 "Balance and gait, you understand what I am saying, don't you?"
 "Yes, yes, walking, running...".
 "And you said that you don't have problems walking, running?"
 (purposeful positive intonation).
 "Yes, yes, exactly".
 "But running or walking are not a problem for you, are they?"
 (negative intonation).
 "No, no...".

CT scan was performed, which showed diffuse cortical and subcortical atrophy, with secondary ventricular dilatation, diffuse leukoencephalopathy and multiple lacunar strokes in the basal ganglia, which may possibly be compatible with Binswanger's disease. CSF examination was normal, except for a protein level of 1.140 mg/l.

Discussion

Our patients presented a peculiar type of speech disorder, which has not previously been reported. They both gave "echoing approval" to a suprasegmental aspect of communication including either the positive or negative syntactic construction of the questions they had been asked, or to dialogues between two medical colleagues held in their presence, and also sometimes gave echoing approval to the positive or negative intonation used to question them, even when this was deliberately used to produce conflicting statements. The replies bore no relationship to their actual complaints or to their own opinion or understanding. They would even contradict themselves within the space of a few seconds, without any insight or self-correction, even when confronted with their own contradictions. Because of the conflicting syntax of the way questions are asked in English, this speech behaviour may be less obvious in English, but in languages like French, German, Spanish, Portuguese or Italian, and maybe many other languages, in which the affirmative or negative reinforcement at the end of the questions is not so frequently used, it may be more obvious.

Both patients had a variant form of transcortical motor aphasia with loss of spontaneity of speech, low fluency and stuttering, and preserved repetition. Echolalia is often found in association with transcortical aphasia. One of the generally accepted explanations for echolalia is a disinhibition, or disconnection, of the acousticomotor reflex

from the SMA, and this is commonly reported in childhood during the development of speech. The absence of frontal inputs to the speech areas, which account for the loss of intentionality and voluntary initiation of speech ("asplontaneity" of speech of the transcortical motor aphasia), may disinhibit compulsory speech production induced by sensory inputs from the parietal lobes [2, 11, 12]. The integrity of the posteromedial part of the frontal lobe seems to be a prerequisite for normal reaction to speech stimuli received from the Wernicke area [2]. The most anterior part of the medial subcallosal fasciculus, at the lateral angle of the frontal horn of the lateral ventricles, deep to Broca's area, contains the projections from both the cingulate gyrus area 24 and the SMA to the caudate nucleus [14–17], and therefore the afferent loop of the circuit to the cortical speech areas. A similar mechanism of disinhibition or disconnection, at another level of speech processing, could be accepted for echoing approval, but in contrast to echolalia patients do not repeat words or sentences in echoing approval [1, 2].

Echoing approval also differs from perseverations because of the absence of repetitive non-inhibited words, or parts of sentences, in response to different questions [10]. However, in oroverbal perseverations, San Pietro and Rigrodsky [10] distinguished between patterns including semantic selection, programme of action and phonemic carry-over, none of which can be used for anterior or posterior localization in the frontal lobe. A semantic selection deficit would only partly account for the speech disorder described here, because prosodic selection would, at times, predominate over semantic echoing. Verbal iterations and perseverations with ideation and semantic incoherences have also been described in patients with lesions of the left putaminocaudate nuclei [17, 18].

Deficits in understanding can definitively not explain the answers of the patients, as understanding was not significantly impaired and the answers were not random. Although some similarity with the "feeling tone" often seen in aphasic patients can be mentioned, the understanding of even complex speech was preserved in both patients.

A major attention deficit could also be ruled out, as the attention tests were normal in the first patient and only mildly impaired in the second. Confabulation can also be ruled out as an explanation for echoing approval, as it was absent in both patients.

Our patients' speech disorder shares striking similarities with echoing motor behaviours described by Lhermitte in the the environmental-dependency syndrome [11]. Echopraxia, echomimia, and environment-driven behaviours [11–13] were in fact found in both patients, and our speech disorder may be considered as a form of an echoing behaviour of speech, different from echolalia, with echoing to both the semantic and prosodic aspects of speech. An interesting finding is that of real dissociation between the patients' echoing responses to prosody of sentences and their ignorance of the semantics, especially

since comprehension was largely intact, which is consistent with the significant anosognosia found in both patients. In echopraxia, echomimia, and environmental dependency syndrome, a dysfunction of the frontosubcortical orbitofrontal and dorsolateral circuits has been postulated [13]. In our first patient, the head of the caudate nucleus was involved, but on the right side, together with the anterior part of the corpus callosum, and subcortical frontal white matter, including the subcortical connection to the SMA. The second patient had clinical dysfunction of both striata, accounted for by his pre-eminent levodopa-resistant parkinsonism and multiple lacunes in the striatum, but also a more diffuse leukoencephalopathy and lacunar infarcts in the thalami, which accounted for a more generalized pathology, making it difficult to delineate the strategic defective network at the origin of our speech disorder. In patient 1, however, no lesion was found outside the frontal, striatal and callosal regions. These findings are compatible with a bilateral fronto-subcortical dysfunction in several of the loops described by

Alexander et al. [13], including some disconnection in the orbitofrontal, dorsolateral and frontomesial motor loop that is possibly responsible for the environmental dependency syndrome described by Lhermitte [11, 19].

In conclusion, we describe a new pattern of speech disorder, which belongs to the broad group of "echo" phenomena. Without pathological studies on our two patients, it is not possible to define more precisely the network of lesions needed for the occurrence of "echoing approval", but frontal deficits were the outstanding features in the clinical picture, together with transcortical motor aphasia. Both patients also showed clinical and/or radiological evidence of bilateral frontostriatal involvement, which could indicate that the dysfunction of the frontosubcortical circuits described by Alexander, including the orbitofrontal, dorsolateral and frontomesial circuits, might play a role in this clinical picture, as in other forms of environment-dependency syndromes [11–13] and the transcortical motor aphasia found in both patients.

References

- Liebaldt GP, Scheller H, Schleip I (1975) Anatomic localization of echolalic phenomena in the CNS. Pathology of spontaneity in human speech. *Nervenarzt* 46:422–433
- Környey E (1975) Aphasie transcorticale et echolalie: le problème de l'initiation de la parole. *Rev Neurol (Paris)* 131:347–363
- Benassi V (1972) Imitation and functional speech in autistic children: a reply to Hartung. *J Speech Hear Disord* 37:421–422
- Scherer NJ, Olswang LB (1989) Using structured discourse as a language intervention technique with autistic children. *J Speech Hear Disord* 54:383–394
- Garber NB, David LE (1975) Semantic considerations in the treatment of echolalia. *Ment Retard* 13:8–11
- Shapiro T, Lucy P (1978) Echoing in autistic children: a chronometric study of semantic processing. *J Child Psychol Psychiatry* 19:373–378
- Paccia JM, Curcio F (1982) Language processing and forms of immediate echolalia in autistic children. *J Speech Hear Res* 25:42–47
- Assal G (1985) Batterie des examens neuropsychologiques du CHUV
- Buttet J, Assal G (1980) Etude du conflit entre la prosodie et la syntaxe dans la parole comprimée. *Rev Neurol (Paris)* 10:665–667
- Santo Pietro MJ, Rigrinsky S (1986) Patterns of oral-verbal perseveration in adult aphasics. *Brain Lang* 29:1–17
- Lhermitte F (1986) Human anatomy and the frontal lobes. II. Patient behavior in complex and social situations: the "environmental dependency syndrome". *Ann Neurol* 19:335–343
- Ghika J, Tennis M, Hoffmann E, Johnson K, Ghika J (1995) Environment-driven behaviors in progressive supranuclear palsy. *J Neurol Sci* 130:104–111
- Alexander GE, Crutcher MD, deLong MR (1990) Basal ganglia-thalamo-cortical circuits: parallel substrates for motor, oculomotor, "prefrontal" and "limbic" functions. *Prog Brain Res* 85:119–146
- Sass KJ, Novelly RA, Spencer DD, Spencer SS (1990) Postcallosotomy language impairments in patients with crossed cerebral dominance. *J Neurosurg* 72:85–90
- Naeser MA, Palumbo CL, Helm-Estabrooks N, Stiassny-Eder D, Albert ML (1989) Severe nonfluency in aphasia. Role of the medial subcallosal fasciculus and other white matter pathways in recovery of spontaneous speech. *Brain* 112:1–38
- Alexander MP, Warren RL (1988) Localization of callosal auditory pathways: a CT case study. *Neurology* 38:802–804
- Cambier J, Elghozi D, Khouri M, Struke A (1980) Répétition écholalique et troubles sévères de la compréhension: syndrome de déactivation de l'hémisphère gauche? *Rev Neurol (Paris)* 136:89–98
- Barat M, Mazaux JM, Bioulac B, Giroire JM, Vital C, Arné L (1981) Troubles du langage de type aphasique dans les lésions putamino-caudées. Observation anatomo-clinique. *Rev Neurol (Paris)* 137:343–356
- Milner B, Petrides M (1984) Behavioural effects of frontal-lobe lesions in man. *Trends Neurosci* 7:403–407