

Masud Husain  
Christopher Kennard

## Visual neglect associated with frontal lobe infarction

Received: 2 January 1996  
Received in revised form: 28 May 1996  
Accepted: 1 June 1996

M. Husain (✉) · C. Kennard  
Department of Clinical Neuroscience,  
Charing Cross Hospital,  
Fulham Palace Road, London W6 8RF, UK  
Tel.: 0181 846 7501  
Fax: 0181 846 7715  
E-mail: mhusain@cxwms.ac.uk

**Abstract** Five patients with left-sided visual neglect following focal infarction of the right frontal lobe are presented. Lesion location was assessed using computed tomography or magnetic resonance imaging. The common area of lesion overlap was small, being confined to the dorsal aspect of the inferior frontal gyrus (Brodmann's area 44) and the immediate underlying white matter. This

cortical region is part of the homologue of Broca's area in the right hemisphere and is considered to be part of human premotor cortex. The association of neglect with injury to this area suggests it may play an important role in directing attention in visual space.

**Key words** Visual neglect · Frontal lobe · Cortex

### Introduction

Unilateral visual neglect appears to be most severe and most frequent following injury to the right cerebral hemisphere of man [9]. In recent years, computed tomography (CT) correlation studies have demonstrated that within the right hemisphere the inferior parietal lobule is the region most frequently damaged in patients with severe neglect [16, 33]. Although neglect may also follow injury to the frontal lobe, basal ganglia and thalamus, reports are few, and current understanding of lesions outside the parietal lobe associated with neglect is imprecise [17, 32].

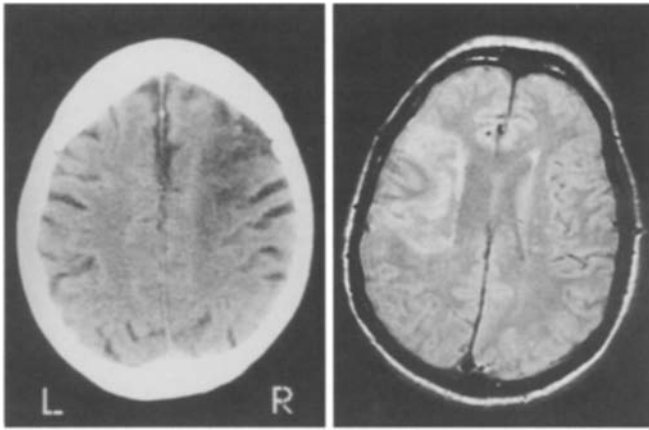
Nevertheless, some broad themes have emerged. First, injury to at least two regions of frontal cortex may be associated with contralateral neglect. One appears to be located on its lateral aspect, whilst the other lies on the medial side and involves the cingulate cortex [15, 17]. Second, injury to either the thalamus or basal ganglia is sufficient to cause neglect, but this may be due to deafferentation of overlying parietal and frontal cortices [4, 32]. Third, lesions confined to the white matter alone appear rarely to be associated with neglect [33], although there are reports of the syndrome occurring after infarction of the posterior limb of the internal capsule [4, 32].

These findings have been incorporated into models of how various brain regions normally direct visual attention. For example, the hypothesis has been advanced that whilst the inferior parietal lobule is responsible for representing space, and the cingulate cortex may have a role in assigning motivational relevance to sensory events, dorso-lateral frontal areas may be important in generating the exploratory motor components of attentive behaviour [23]. Furthermore, it has been suggested that the frontal eye fields or regions near them may be the critical areas associated with neglect following dorsolateral frontal lesions [23, 24].

Validation or improvement of this proposal requires a more precise understanding of both the location and function of the frontal regions implicated in neglect. Here, we report on the location of lesions in five cases of left-sided visual neglect associated with right lateral frontal lobe infarction.

### Materials and methods

The patients reported here were seen by the authors at two centres over a period of 20 months. The first three subjects were assessed by one of us from the day of admission; the last two were seen 1 week after entry to hospital. Visual fields were full to confrontation in all subjects. All the patients were considered to have visual



**Fig. 1** CT scan of case 4 and MRI of case 5, demonstrating focal infarcts in the right frontal lobe. Note that in case 5 the lesion extends to the anterior parietal cortex

neglect and none showed visual extinction. Eye movements were tested at the bedside. Although all the patients spontaneously directed their gaze toward the right, they were able to make saccades towards an examiner's hand moving in the left visual hemifield. None of the patients were found to have somatosensory deficits except case 5, who suffered from left-sided extinction to light touch.

Visual neglect was quantified using a number of standard assessments. All patients were tested on the Mesulam shape cancellation task [25]: 60 target shapes are embedded amongst 312 distractor items on an A4 sheet of paper and subjects are asked to cancel all the targets they can see. No time limit is imposed. Normal subjects find between 54 and 60 targets ( $n = 40$ , unpublished observations in subjects aged 65–85 years). All patients were also tested on line bisection: they were asked to mark the midpoint of a 180-mm horizontal line placed in the centre of an A4 sheet of paper. The range of normal bisection is between 4.3 mm to the right and 9.4 mm to the left of the true midpoint [12, 21]. Cases 4 and 5 were also tested using the conventional subtests of the Behavioural Inattention Test (BIT), where the cut-off score is 129 out of a total of 146 [34]. CT was performed on all the patients within 3–5 days after the onset of neurological symptoms except for case 5, in whom it was performed 8 h after symptom onset. This patient gave informed consent for magnetic resonance imaging 10 weeks later. No focal lesion other than a single infarct was seen on any of the scans. CT of case 2 revealed mild cerebral atrophy. Examples of imaging are shown in Fig. 1. All the patients had been functionally independent prior to their strokes. None were considered to show signs of dementia.

## Case reports

### Case 1

A 68-year-old right-handed woman presented to hospital because of a sudden-onset disturbance of speech. The patient was able to comprehend three-stage commands and point to named objects, but her speech was non-fluent and telegraphic. She was also noted to direct her gaze to the right and neglect objects on her left. On the Mesulam shape cancellation task she cancelled a mean of 6 targets out of a total of 60 (range = 2–8;  $n = 4$ ). All the targets she found were on the extreme right edge of the array. When bisecting 180-mm lines she deviated to the right of centre by a mean of 20 mm (SD = 2.0,  $n = 10$ ) and, although she drew objects correctly, she always placed them on the right side of the sheet.

Visual fields were full to confrontation. Eye movements tested at the bedside appeared normal except for prolonged latencies to targets presented on the left. There was a mild left-sided pyramidal weakness of the limbs which improved to normal power within 5 days. Sensation of pinprick, light touch, vibration and joint position was normal. On the Mini-Mental Test [10] she scored 28/30. When she was reviewed 6 weeks later, the patient's neglect had resolved: she scored a mean of 59/60 on the shape cancellation task (range = 58–60;  $n = 4$ ) and deviated to the left of centre by a mean of 1 mm (SD = 1.7;  $n = 10$ ). However, she continued to experience difficulties with her speech.

Three months later, the patient's speech had improved and her only difficulty was word-finding. Testing on the Edinburgh handedness inventory [27] demonstrated that she was strongly right-handed (laterality quotient of +100, where extreme right-handedness is +100). Dysphasia following right cerebral hemisphere damage in right-handers – so-called crossed dominance – is very rare [e.g. 35] and suggests there may be unusual lateralisation of language in this patient.

### Case 2

An 80-year-old right-handed woman presented following a collapse at home. She was initially found to be drowsy, in atrial fibrillation, with a mild left-sided hemiparesis and profound left-sided neglect. Her speech was normal. Three days after admission more detailed testing was possible. She scored 26/30 on the Mini-Mental Test. Visual fields were full to confrontation. Eye movements appeared normal except for delayed saccades to the left and broken pursuit movements when following a target to the left. Sensation of light touch, pinprick, vibration and joint position was normal. Assessment of visual search using the shape cancellation task demonstrated profound left-sided neglect: the patient marked a mean of only 4/60 targets, all on the right side of the array (range = 2–7;  $n = 6$ ). When bisecting 180-mm-long lines, she deviated to the right of centre by a mean of 35 mm (SD = 21.6;  $n = 10$ ) and when asked to draw a clock she placed all the numbers on the right. Three weeks after admission her neglect appeared unchanged. The patient died shortly afterwards.

### Case 3

A 71-year-old right-handed woman known to have ischaemic heart disease presented with unstable angina. She was admitted to the coronary care unit and treated with intravenous heparin and glyceryl trinitrate. Her pain improved and the infusions were stopped. Six days after admission, her behaviour appeared altered. Examination revealed she was orientated in time, place and person; on the Mini-Mental Test she scored 29/30. Her speech was normal. There was no limb weakness or sensory deficit of light touch, pinprick, vibration or joint position. However, she ignored objects and people to her left. Visual fields were full to confrontation. Eye movements appeared normal except for delayed saccades to the left.

Visual search appeared markedly impaired: on the shape cancellation task she marked a mean of 9/60 targets (range = 5–13;  $n = 4$ ) and all the targets she cancelled were on the right edge of the array. However, line bisection was normal: she deviated to the right of centre by a mean of only 1 mm (SD = 2.8;  $n = 10$ ). The patient's neglect did not improve over the next 3 weeks in hospital. She was lost to follow-up.

### Case 4

An 87-year-old right-handed woman presented following a collapse at home. She was alert and orientated in time, place and per-

son; she scored 27/30 on the Mini-Mental Test. Her speech was normal. She had a moderately severe left-sided hemiparesis but no disturbance of sensation of light touch, pinprick or joint position. There was bilateral loss of vibration sense below the knees consistent with the patient's age. Visual fields were full to confrontation but she was noted to have mild left-sided neglect. Eye movements were normal except for prolonged latencies to visual targets on the left.

The patient's neglect was assessed using the BIT [34]. She scored 105/146 on the conventional sub-tests. She cancelled 36/54 targets on the BIT star cancellation test ( $n = 1$ ) and a mean of 40/60 targets on the Mesulam shape cancellation task (range = 25–46;  $n = 9$ ). All the targets which were omitted were on the left side of the array. Interestingly, however, when given a cancellation task with only target items (and no distractors), such as the BIT line cancellation task, she was able to find 33/36 targets ( $n = 1$ ). The patient marked a mean of 20 mm to the right of centre when bisecting 180 mm lines (range = 11–28;  $n = 3$ ). The patient's neglect resolved within 6 weeks of admission.

#### Case 5

A 67-year-old right-handed man presented with collapse following right-sided headache. Initially, he was drowsy and found to have a severe left-sided hemiparesis. Sensation of light touch, pinprick, vibration and joint position was normal. Visual fields were full to confrontation. Urgent CT revealed an ill-defined low attenuation area in the right frontal lobe. Over subsequent days the patient became more alert. On the Mini-Mental Test he scored 28/30. At this stage it became clear that he also suffered from left-sided visual neglect. Eye movements were normal except for delayed saccades to visual targets on the left.

On the conventional sub-tests of the BIT battery, the patient scored 68/146. He cancelled a mean of 13/60 targets (range = 5–18;  $n = 20$ ) on the Mesulam shape cancellation task. On the BIT star cancellation test he marked a mean of 15/54 star targets (range = 14–17;  $n = 4$ ). All the targets he cancelled were on the right side of

the array. However, on the BIT line cancellation test, which has only line targets and no distractors, he performed very well, finding a mean of 35.5/36 targets (range = 35–36;  $n = 4$ ). When bisecting 180-mm lines he deviated to the right of centre by a mean of only 3 mm (range = 3–4;  $n = 3$ ). Further aspects of this patient's distractor-dependent neglect are discussed elsewhere (Husain and Kennard, in preparation). The patient's neglect resolved within 8 weeks of admission.

## Results

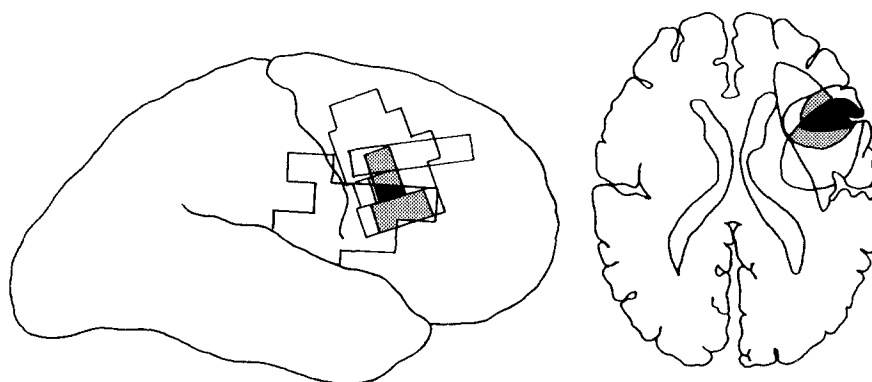A summary of the presenting symptoms and signs of the five cases is given in Table 1. Their lesions were plotted on templates according to the method described by Damasio and Damasio [7] and the subcortical extent of injury was further assessed using the atlas of Matsui and Hirano [22]. The region of overlap of four of the cases (1–3 and 5) is extremely small (see Fig. 2). It involves only the dorsal aspect of the inferior frontal gyrus (corresponding to part of the pars opercularis or Brodmann's area 44) and the immediate underlying white matter. The region of overlap of three of five cases is larger: although small portions of dorsal area 45 and anterior area 6 are involved, it consists largely of dorsal area 44 together with the underlying white matter.

The deep nuclei were spared in all cases except patient 5, in whom the putamen appeared to be involved (Table 2). In this subject the infarct also extended into the anterior part of the parietal lobe and this may account for his somatosensory extinction. None of the lesions encroached upon the inferior parietal lobe, which is the area most

**Table 1** Summary of findings. A *plus sign* denotes the presence of an abnormality and a *minus sign* denotes its absence. *Parentheses* indicate resolution of an abnormality

	Left hemiplegia	Dysphasia	Left somatosensory extinction	Left visual extinction	Left visual field loss to confrontation	Mean Mesulam shape cancellation score	Mean deviation to right on 180-mm line bisection
Case 1	(+)	+	–	–	–	6/60	20 mm
Case 2	+	–	–	–	–	4/60	35 mm
Case 3	–	–	–	–	–	9/60	1 mm
Case 4	+	–	–	–	–	40/60	20 mm
Case 5	+	–	+	–	–	13/60	3 mm

**Fig. 2** Reconstruction of lesion sites on a lateral view of the brain and a sagittal section through the area of greatest overlap. The black area represents the region of overlap in four of five cases. The grey area shows the extent of overlap in three of five cases



**Table 2** Extent of lesions

	Inferior frontal gyrus	Middle frontal gyrus	Pre-central gyrus	Post-central gyrus	White matter	Putamen	Thalamus
Case 1	+	–	–	–	+	–	–
Case 2	+	–	+	–	+	–	–
Case 3	+	+	–	–	+	–	–
Case 4	–	+	–	–	+	–	–
Case 5	+	–	+	+	+	+	–

commonly associated with neglect in previous studies [16, 33].

## Discussion

In this study we report five patients with left-sided neglect associated with infarcts confined largely to the right frontal lobe. The region of lesion overlap consists of the dorsal aspect of the inferior frontal gyrus (part of Brodmann's area 44) and the immediate underlying white matter. This cortical region is part of the homologue of Broca's area in the right hemisphere. Cytoarchitectonic studies suggest that it is part of "premotor" cortex, but its exact function is poorly understood [24]. Our results suggest that it may normally play an important role in directing attention in visual space. An alternative interpretation is that neglect in our patients resulted from damage to white matter tracts which pass through this region, possibly disconnecting posterior parietal from prefrontal cortex. Whichever view is correct, a review of the literature on frontal neglect shows that the lesion sites of previous cases with lateral injury [2, 5, 6, 8, 18–20, 31] appear to include the region associated with neglect in this study.

Our finding confirms the general hypothesis that in man lesions on the lateral surface of the frontal lobe may be associated with neglect. In monkey, lesions of the frontal eye field (the anterior bank of the arcuate sulcus) results in neglect of far visual space, whereas injury to the premotor cortex (area 6) leads to neglect of peripersonal visual space [30]. In man, the frontal eye field is considered to be situated dorsal to area 44, the region of greatest overlap demonstrated in this study [1, 29].

Galaburda and Pandya [11] have presented evidence to suggest that area 44 of man has a cytoarchitectonic homologue in the posterior bank of the arcuate sulcus in monkey, i.e. in a region lying immediately posterior to the frontal eye field. In the human left hemisphere, area 44 appears to have a role in speech production [28]. In the right hemisphere, our data suggest it may have a role in directing attention or planning movements to search contralateral space. Case 1 appears to be an interesting example of "crossed dominance" (cf. [35]), since her speech (as well as visuospatial attention) was affected by a right frontal lesion.

Is there a difference between neglect following lesions of the parietal and frontal lobes? Some authors have previously suggested that "premotor" factors may be associated with neglect following frontal injury [14]. Directional hypokinesia or a failure to use the limbs to explore contralateral space has been reported to be more common in patients with lesions which involve both the frontal and parietal lobes [3]. At the time we assessed the patients reported here we were unable to examine this issue. However, others have presented evidence to suggest that frontal neglect may not always be associated with a deficit in programming the amplitude of contralesional movements [16].

Two recent investigations have demonstrated another association. Whereas neglect patients with predominantly frontal injury perform poorly on cancellation tasks, their ability to bisect lines is well preserved [2, 20]. Patients with parietal injury appear to be poor on both [2]. Our observations, using Mesulam's shape cancellation task [25], are in broad agreement with the findings in frontal patients: the deficits in line bisection in the patients we have described were usually mild when compared with their cancellation performance. This pattern of results suggests that visual search may be significantly more impaired than the processes mediating judgement of line length. Further support for this comes from the observation that decreasing attentional demands (by using cancellation tasks without distractors) substantially improved the degree of neglect in cases 4 and 5. However, there is at least one published example of a patient with a temporoparietal lesion who performed poorly on cancellation but normally on bisection [12]. Furthermore, poorer performance on the BIT star cancellation test (which has distractors) compared to line cancellation (where there are no distractors) has previously been reported in a large cohort of neglect patients which probably included patients with only posterior lesions [13].

Some investigators have remarked upon the rarity of neglect associated with frontal lesions. For example, Valdar and Perani [33] reported only one case in their series of 110 right hemisphere patients with stroke. Our impression is that neglect is most commonly associated with large lesions involving both frontal and parietal lobes. The paucity of cases associated with only frontal injury may reflect two factors. First, regardless of the presence of neglect, the number of patients who present with only

frontal infarction is small; and second, our results are consistent with the view that a critical site needs to be damaged for neglect to occur.

Of the 110 patients presented by Vallar and Perani [33], 11 had only frontal lesions. Of these, only two appear to have suffered lesions which would compromise the region of overlap demonstrated in the present study, and one of these had neglect. Interestingly, the region of maximal lesion overlap in patients with severe neglect and strokes involving both the frontal and parietal lobe appears to include the inferior parietal lobule *and* the in-

ferior frontal gyrus [33]. Thus, two critical areas may have been damaged in these individuals.

Clearly, our understanding of visual neglect following dorsolateral frontal infarction, with or without concomitant parietal damage, is in its infancy. The results presented here suggest further insight into the function of Brodmann's area 44 in the right cerebral hemisphere may assist in improving this situation.

**Acknowledgements** We thank Robin Walker and two anonymous referees for their helpful comments. This work is supported by a Wellcome Trust Advanced Training Fellowship grant to M.H.

## References

1. Anderson TJ, Jenkins IH, Brooks DJ, Hawken MB, Frackowiak RSJ, Kennard C (1994) Cortical control of saccades and fixation in man. A PET study. *Brain* 117:1073–1084
2. Binder J, Marshall R, Lazar R, Benjamin J, Mohr JP (1992) Distinct syndromes of hemineglect. *Arch Neurol* 49:1187–1194
3. Bisiach E, Geminiani G, Berti A, Rusconi M (1990) Perceptual and premotor factors of unilateral neglect. *Neurology* 40:1278–1281
4. Bogousslavsky J, Miklossy J, Regli F, Deuraz JP, Assal G, Delaloye B (1988) Subcortical neglect: neuropsychological, SPECT, and neuropathological correlations with anterior choroidal artery territory infarction. *Ann Neurol* 23:448–452
5. Bottini G, Sterzi R, Vallar G (1992) Directional hypokinesia in spatial hemineglect: case study. *J Neurol Neurosurg Psychiatry* 55:562–565
6. Daffner KB, Ahern GL, Weintraub S, Mesulam M-M (1990) Dissociated neglect behaviour following sequential strokes in the right hemisphere. *Ann Neurol* 28:97–101
7. Damasio H, Damasio AR (1989) *Lesion analysis in neuropsychology*. Oxford University Press, New York
8. Damasio AR, Damasio H, Chang Chui H (1980) Neglect following damage to frontal lobe or basal ganglia. *Neuropsychologia* 18:123–132
9. De Renzi E (1982) *Disorders of space exploration and cognition*. Wiley, New York
10. Folstein MF, Folstein SE, McHugh PR (1975) "Mini-mental state". A practical method for grading the cognitive state of patients for the clinician. *J Psychiatr Res* 12:189–198
11. Galaburda AM, Pandya DN (1982) Role of architectonics and connections in the study of primate brain evolution. In: Armstrong E, Falk D (eds) *Primate brain evolution. Methods and concepts*. Plenum Press, New York, pp 203–216
12. Halligan PW, Marshall JC (1992) Left visuo-spatial neglect: a meaningless entity? *Cortex* 28:525–535
13. Halligan PW, Marshall JC, Wade DT (1989) Visuospatial neglect: underlying factors and test sensitivity. *Lancet* II:908–911
14. Heilman KM (1979) Neglect and related disorders. In: Heilman KM, Valenstein E (eds) *Clinical neuropsychology*. Oxford University Press, New York, pp 268–307
15. Heilman KM, Valenstein E (1972) Frontal lobe neglect in man. *Neurology* 22:660–664
16. Heilman KM, Valenstein E, Watson RT (1983) Localization of neglect. In: Kertesz A (ed) *Localization in neuropsychology*. Academic Press, New York, pp 471–492
17. Heilman KM, Watson RT, Valenstein E (1994) Localization of lesions in neglect and related disorders. In: Kertesz A (ed) *Localization and neuroimaging in neuropsychology*. Academic Press, San Diego, pp 495–524
18. Ishiai S, Watabiki S, Lee E, Kanouchi T, Odajima N (1994) Preserved leftward spatial movement in left unilateral spatial neglect due to frontal lesions. *J Neurol Neurosurg Psychiatry* 57:1085–1090
19. Liu GT, Bolton AK, Price BH, Weintraub S (1992) Dissociated perceptual-sensory and exploratory-motor neglect. *J Neurol Neurosurg Psychiatry* 55:701–706
20. Maeshima S, Terada T, Nakai K, Nishibayashi H, Ozaki F, Itakura T, Norihiko K (1995) Unilateral spatial neglect due to haemorrhagic contusion in the right frontal lobe. *J Neurol* 242:613–617
21. Manning L, Halligan PW, Marshall JC (1990) Individual variation in line bisection: a study of normal subjects with application to the interpretation of visual neglect. *Neuropsychologia* 28:647–655
22. Matsui T, Hirano A (1978) *An atlas of human brain for computerized tomography*. Thieme, Stuttgart
23. Mesulam M-M (1981) A cortical network for directed attention and unilateral neglect. *Ann Neurol* 10:309–325
24. Mesulam M-M (1985) Patterns of behavioural neuroanatomy: association areas, the limbic system, and hemispheric specialization. In: Mesulam M-M (ed) *Principles of behavioural neurology*. Davis, Philadelphia, pp 1–70
25. Mesulam M-M (1985) *Principles of behavioural neurology. Tests of directed attention and memory*. Davis, Philadelphia
26. Mesulam M-M (1990) Large-scale neurocognitive networks and distributed processing for attention, language and memory. *Ann Neurol* 28:597–613
27. Oldfield RC (1981) The assessment and analysis of handedness: the Edinburgh Inventory. *Neuropsychologia* 9:97–113
28. Passingham R (1993) *The frontal lobes and voluntary action*. Oxford University Press, Oxford
29. Paus T (1996) Location and function of the human frontal eye field: a selective review. *Neuropsychologia* 34:475–483
30. Rizzolatti G, Matelli M, Pavesi G (1983) Deficits in attention and movement following the removal of postarcuate (area 6) and prearcuate (area 8) cortex in macaque monkeys. *Brain* 106:655–673
31. Stein S, Volpe BT (1983) Classical "parietal" neglect syndrome after subcortical right frontal lobe infarction. *Neurology* 33:797–799

- 
32. Vallar G (1993) The anatomical basis of spatial hemineglect in humans. In: Robertson IH, Marshall JC (eds) *Unilateral neglect: clinical and experimental studies*. Erlbaum, Hove, pp 27–59
33. Vallar G, Perani D (1986) The anatomy of unilateral neglect after right hemisphere stroke lesions: a clinical CT correlation study in man. *Neuropsychologia* 24: 609–622
34. Wilson B, Cockburn J, Halligan P (1987) *Behavioural inattention test*. Thames Valley, Bury St. Edmunds
35. Zangwill OL (1979) Two cases of crossed aphasia in dextrals. *Neuropsychologia* 17: 167–173