



Case report

# Moyamoya disease with a marked collateral supply through the artery of Bernasconi-Cassinari

Ignacio Pascual-Castroviejo <sup>a,\*</sup>, Juan Viaño <sup>b</sup>, Samuel-Ignacio Pascual-Pascual <sup>a</sup>,  
Antonio Perez-Higueras <sup>c</sup>, Vicente Martínez <sup>b</sup>

<sup>a</sup> Service of Pediatric Neurology and Autonomic University, Hospital Infantil 'La Paz', Paseo de la Castellana 261, 28046 Madrid, Spain

<sup>b</sup> Service of Imaging, Sanatorio Nuestra Señora del Rosario, Madrid, Spain

<sup>c</sup> Service of Neuroradiology, Hospital 'Fundación Jiménez Díaz', Madrid, Spain

Received 9 May 1995; accepted 1 August 1995

A case of moyamoya disease is presented. The patient is a 15-year-old white Spanish girl who had the onset of the neurological symptoms at 8 months of age with seizures, transient ischemic attacks and residual left hemiparesis. Cerebral arteriography performed at the age of 1 year revealed all the features of moyamoya disease in the territory of both carotids and in the vertebrobasilar arteries. The presence of an embryonic tentorial artery, the Bernasconi-Cassinari artery, originating from the right internal carotid artery, was disclosed at 1 year of age but did not appear in an arteriogram performed at 6 years of age and it was revisualized by magnetic resonance arteriography (MRA) performed at the age of 15 years. This finding seems to indicate a very early intrauterine onset of the disease in this case and demonstrates the superiority of MRA over conventional arteriography to discover anomalies of intracranial vessels. Administration of nicardipine, a calcium channel blocker, added to conventional antiepileptic drugs that the patient had previously taken, improved the epileptic and the neurological disease.

**Keywords:** Moyamoya disease; Seizure; Calcium channel blocker; Bernasconi-Cassinari artery

## 1. INTRODUCTION

The so-called moyamoya disease consists of idiopathic progressive occlusive disease of the circle of Willis. Clinical symptoms and signs are manifested by motor, sensory and intellectual deficiencies. Diagnosis, however, depends upon the presence of the typical stenosis or/and occlusions of the main cerebral arteries, mostly bilaterally, of the brain and an unusual arterial network at the central zone of the brain.

Shimizu and Takeuchi possibly described the first case of moyamoya, a 29-year-old male, in 1955 [1] in an article entitled 'Hypoplasia of bilateral internal carotid arteries', showing the stenosis of the bilateral internal carotid arteries at the point of ramification, but no intracranial contrasted images were obtained. Takeuchi [2] presented the first images of the abnormal intracranial vessels in 1961. Almost at the same time an adult Spanish patient who had presented the first signs of neurological disease

at 7 years of age was described as the first European case [3]. The disease was structured by the Japanese [4,5] who, at that time, believed that the disease affected only Japanese people. The name 'moyamoya' has been applied since 1969 [6]. The etiology of this disorder is unknown though both congenital and acquired pathologies have been suggested. In this paper, we present an infant who showed persistence of the Bernasconi-Cassinari artery, an embryonic tentorial artery which has usually been associated with tentorial meningioma [7], and the persistence of abnormal prenatal vascularization.

## 2. CASE REPORT

A 15-year-old white Spanish girl had been referred at 1 year of age because of partial seizures. The patient was born after an uneventful pregnancy with a birth weight of 3000 g. There was no parental consanguinity. Psychomotor developmental milestones were normal until the age of 8 months when she began to have partial seizures of the left hemibody with transitory left hemiparesis. During the following months, the patient experi-

\* Corresponding author. Fax: (34) (1) 3582545.

enced partial seizures alternatively on both sides and did not show progression in language development. Physical examination disclosed a head circumference of 45 cm (25 centile), moderate left hemiparesis, normal osteotendinous reflexes and no Babinski response; she was unable to either stand or walk without assistance and did not speak.

The results of routine hematological and chemical studies of blood, urine and cerebrospinal fluid (CSF) were all within normal limits. Interictal electroencephalograms (EEG) showed a desynchronization pattern without paroxysmal activity. Computed to-

mographic (CT) brain scan revealed bilateral corticosubcortical atrophy, more severe in the right hemisphere. Conventional arteriography of both carotid and vertebral arteries (Fig. 1A-C) revealed kinking in the upper extracranial portion of both internal carotid arteries; stenosis of the supraclinoid portion of the internal carotid artery on both sides with extension of the stenosis into the proximal portion of the anterior and middle cerebral arteries; dilatation of both ophthalmic and basilar arteries; well developed fine vascular networks at the base of the brain bilaterally and at the end of the basilar artery; development of numerous bilateral

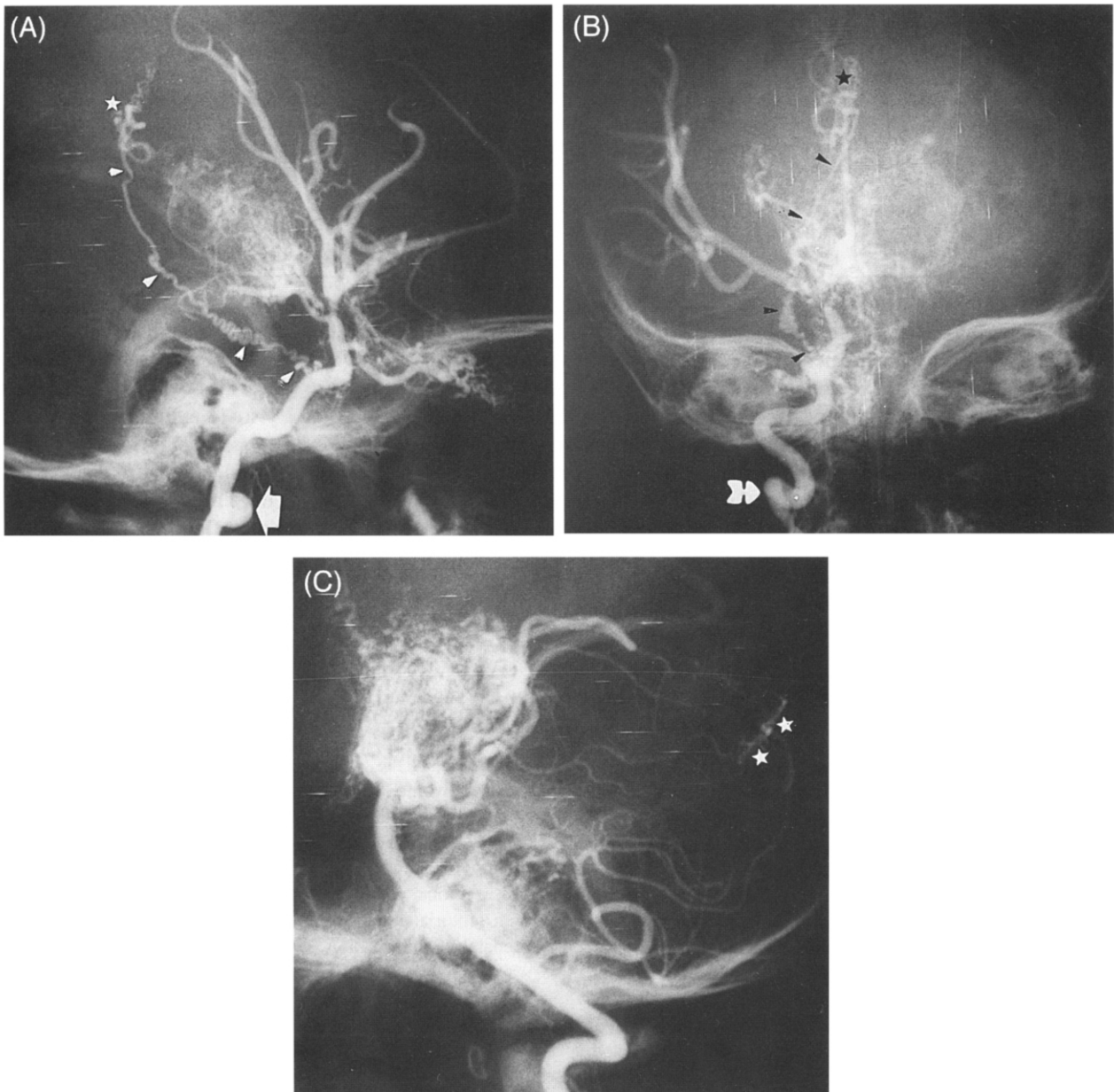


Fig. 1. A, B: Conventional right carotid arteriogram at 1 year of age. Sagittal (A) and coronal (B) views reveal kinking in the extracranial zone of the internal carotid artery (arrow), stenosis of the internal carotid artery in the supraclinoid region, dilatation of the ophthalmic artery, the moyamoya phenomenon in the central zone of the brain, and the presence of the artery of Bernasconi-Cassinari which appears very tortuous (arrowheads) and ends in the midline connecting with the pericallosal arteries (star). C: Vertebrobasilar arteriography at 1 year of age shows a dense network originating from the rostral portion of the basilar artery and its branches. Connections between the most peripheral branches of the posterior inferior cerebellar and the superior cerebellar arteries are also seen (stars).

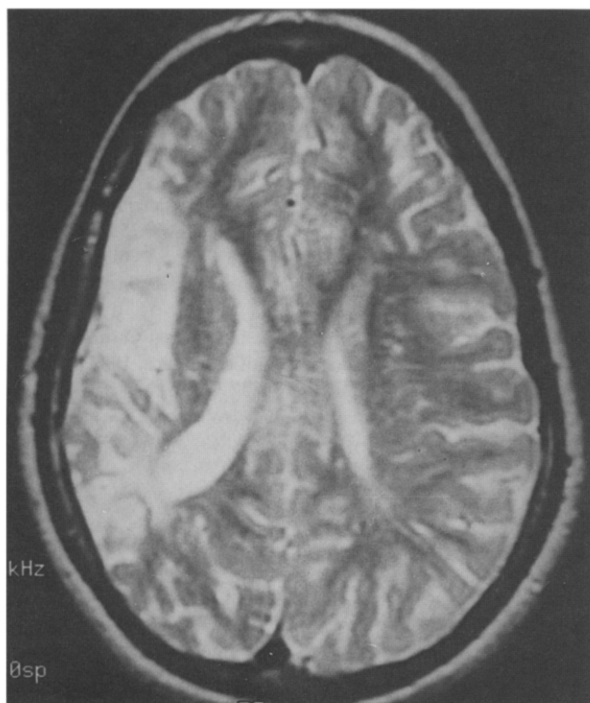


Fig. 2. Axial T2-weighted image shows cortico-subcortical region of the right cerebral hemisphere and a hypoxic-ischemic zone in the territory irrigated by the middle cerebral artery.

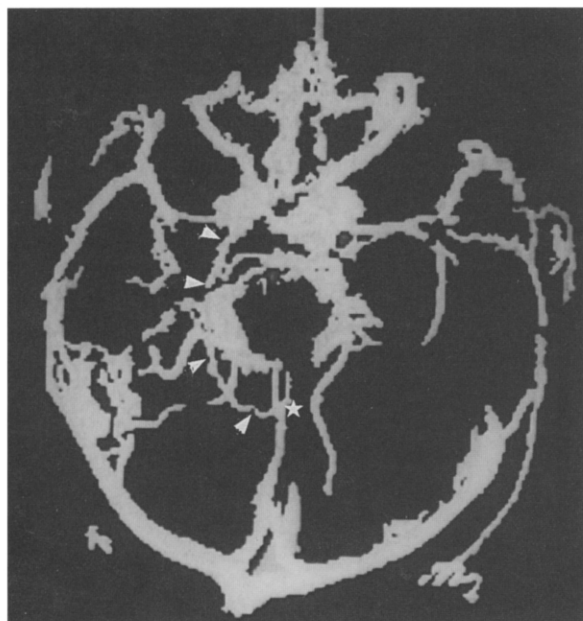


Fig. 3. Three-dimensional MRA in axial view reveals the presence of the pathological vascularization anywhere in the brain, being especially dense in the anterior midline, in the trajectory of both posterior cerebral arteries, and in the right parietal region. Both ophthalmic arteries appear enlarged. Transdural connections are observed. The Bernasconi-Cassinari artery is visualized in the right hemisphere, originating in the intracavernous part of the internal carotid artery, surrounding the midbrain (arrowheads) and arriving at the midline of the posterior callosal zone (star).

collateral extra- and especially intracranial transdural circulation with vessels arising from the branches of the external artery (occipital, meningeal media, internal maxillary, and superficial temporal) and/or from internal artery (ophthalmic); persistence of an embryonic tentorial artery arising from the intracavernous region of the right internal carotid artery, of thin caliber and tortuous trajectory to the posterior zone of the tentorium and midline of the supratentorial region where the phenomenon of moyamoya appeared (Fig. 1A,B). In the posterior fossa connections between branches of the posterior inferior cerebral artery (PICA) and the superior cerebellar artery were distinguished (Fig. 1C). At that time, the patient was taking a daily dose of 5 mg/kg of phenytoin, despite which she presented partial seizures almost weekly. We added nicardipine, a calcium channel blocker, in a dose of 2 mg/kg/day to the above regimen, and then her seizures were controlled. The patient improved in psychomotor and language skills and she was able to walk by the age of 20 months and to speak since 18 months. Cerebral arteriography was repeated at 7 years of age; vascular changes were similar to those observed 6 years earlier, but the Bernasconi-Cassinari artery was not visualized. She had menarche at 13 years and menstrual cycles every 28 days were regular. A cerebral magnetic resonance (MR) study was performed at the age of 12 years, disclosing an ischemic area in the region irrigated by the right middle cerebral artery (Fig. 2). The patient's school performance is normal in accordance with her age. Psychological testing (WISC), performed at 15 years of age, shows a verbal intellectual quotient (IQ) of 87; performance IQ of 60; and combined IQ of 71. MR angiography, in normal planes and tridimensionally performed at age 15, revealed the same findings as the conventional arteriography performed at 1 year of age, including the presence of the Bernasconi-Cassinari artery (Fig. 3).

### 3. DISCUSSION

Moyamoya disease is diagnosed by its cerebral angiographic features. Although most of the cases published in the first descriptions were adults reported by neurosurgeons, this disease is perhaps most frequent in children. The age of onset may be within the first months of life [8]. The vascular disease gives origin to pure transient ischemic attacks (TIA) and/or infarcts, often associated with seizures and mainly partial in type. In most reported cases and also in our patient, the onset of the neurological disease is abrupt and symptoms of the TIA type are recurrent unilaterally or alternative hemiparesis may persist for a variable time. Infarcts usually are circumscribed to the vascular territory of intracranial arteries, the right middle cerebral artery in our patient. The angiographic features of the moyamoya disease can be divided into six [6] or eight [8] stages in terms of the progression of the carotid fork occlusion. With progression of the disease, compensatory dilatation of the main intracranial arteries and the abnormal vessels, which constitute the moyamoya phenomenon and transdural connections, are observed. The presence of persistent embryonic arteries associated with moyamoya disease has been previously reported [9-12]. The trigeminal artery was observed in all four reports. The artery of Bernasconi-Cassinari, however, has not been described in association with moyamoya disease so far.

Histological studies show that leptomenigeal vessels of moyamoya disease are not newly formed but merely dilated preexist-

ing vessels. The structural alteration of the vascular walls suggests their adaptability to participate in the collateral circulation at the cerebral surface [13].

The artery of Bernasconi-Cassinari, an embryonic tentorial vessel, was first described as a typical sign of tentorial meningioma. It can be seen in children at 1 year of age [7] and in elderly patients with tentorial meningioma, but also in other diseases such as cerebral hemangioblastoma. Its presence as collateral vascularization in a very young girl with moyamoya disease as well as the persistent primitive trigeminal artery may suggest a very early onset of this disease, whose onset can occur during the first weeks of gestation. The lack of visualization of this artery in a second arteriogram and its presence by MRA many years later may indicate some type of reaction of the arterial walls caused by the contrast substance and the superiority of MRA over conventional arteriography to visualize the intracranial vessels, perhaps because no contrast media are required. With MRA, it is possible that new arteriographic findings will be described in the future in moyamoya disease.

Nicardipine, a calcium antagonist, was successfully used in our patient. She showed a rapid and continuous response. Another calcium channel blocker, verapamil, has been used in moyamoya disease with positive responses to perfusion through transbasal anastomosis [14]. Nicardipine had previously demonstrated a significant effectiveness on other epileptic diseases with possible vascular origin [15].

**ACKNOWLEDGEMENTS** We are grateful to Dr. Harvey B. Sarnat (Seattle) for his great help to prepare this paper in understandable English.

## REFERENCES

1. Shimizu K, Takeuchi K. Hypoplasia of bilateral internal carotid arteries (in Japanese). *Abstracts of the 14th annual meeting of the Japanese Society of Neurosurgery*, Wakayama, 1955.
2. Takeuchi K. Occlusive diseases of the carotid artery: especially on their surgical treatment (in Japanese). *Shinkei Kenkyu No Shimpō (Tokyo)* 1961; **5**: 511-43.
3. Subirana A, Subirana M. Malformations vasculaires du type de l'angiome artériel récémieux. *Rev Neurol (Paris)* 1962; **107**: 545-50.
4. Nishimoto A, Sugiu R. Hemangiomas malformation of bilateral internal carotid at the base of the brain. Preliminary report. *Proc Ann Mtg Neuro-Radiol Ass Japan. Tokyo.* 1964; **5**: 2-9.
5. Nishimoto A, Takeuchi S. Abnormal cerebrovascular network related to internal carotid arteries. *J Neurosurg* 1968; **29**: 255-60.
6. Suzuki J, Takaku A. Cerebrovascular 'moyamoya' disease: Disease showing abnormal net-like vessels in base of brain. *Arch Neurol* 1969; **20**: 288-99.
7. Pascual-Castroviejo I. Meningiomas. In: Pascual-Castroviejo I, ed. *Pediatric neurology*. Barcelona: Científico-Médica, 1983: 1144-7.
8. Fukuyama Y, Umezu R. Clinical and cerebral angiographic evolutions of idiopathic progressive occlusive disease of the circle of Willis ('Moyamoya' disease) in children. *Brain Dev (Tokyo)* 1985; **7**: 21-37.
9. Otsuki T, Fukawa O, Aihara T. A case of embryonic persistent trigeminal artery associated with moyamoya-like abnormal vascular network (in Japanese). *Rinsho Hoshasen (Tokyo)* 1982; **27**: 1453-6.
10. Kwak R, Kadoya S. Moyamoya disease associated with persistent primitive trigeminal artery. Report of two cases. *J Neurosurg* 1983; **59**: 166-71.
11. Nakao S, Fukumitsu T. Persistent primitive trigeminal artery in childhood moyamoya disease. Case report (in Japanese). *Shoni No Noshinkei (Kobe)* 1985; **10**: 205-9.
12. Kinjo T, Mukawa J, Takara E, et al. Moyamoya disease associated with persistent primitive trigeminal artery. A case report and review of the literature (in Japanese). *Noshinkei Geka (Tokyo)* 1988; **16**: 1107-12.
13. Kono S, Oka K, Sueishi K. Histopathologic and morphometric studies of leptomeningeal vessels in moyamoya disease. *Stroke* 1990; **21**: 1044-50.
14. McLean MJ, Gebarski SS, Van der Spek AFL, Goldstein GW. Response of moyamoya disease to verapamil. *Lancet* 1985; **i**: 163-4.
15. Pascual-Castroviejo I, Lopez Martín V, Martínez-Bermejo A, et al. Is cerebral arteritis the cause of the Landau-Kleffner syndrome? Four cases in childhood with angiographic study. *Can J Neurol Sci* 1992; **19**: 46-52.