

CASE REPORT

Kenji Ikeda · Haruhiko Akiyama
Shuji Iritani · Koichi Kase · Tetsuaki Arai
Kazuhiro Niizato · Noriomi Kuroki · Kenji Kosaka

Corticobasal degeneration with primary progressive aphasia and accentuated cortical lesion in superior temporal gyrus: case report and review

Received: 5 February 1996 / Revised, accepted: 13 May 1996

Abstract A 57-year-old woman showed progressive sensory aphasia as an initial symptom, and then developed total aphasia within 6 years and, finally, severe dementia. Neuropathologically, the cerebral cortex was most severely affected in the superior and transverse temporal gyri, and subsequently in the inferior frontal gyrus, especially in the pars opercularis. The degeneration in the subcortical grey matter was most severe in the substantia nigra, and it was moderate to mild in the ventral part of thalamus, globus pallidus and striatum. Cytopathologically, in addition to achromatic ballooned neurons, massive tau-positive types of cytoskeletal abnormalities were observed both in neurons and glia, mainly in the degenerating region. This cytoskeletal pathology coincided with that reported in corticobasal degeneration (CBD). On Bodian staining, only a few neurofibrillary tangles were found in the entorhinal pre-alpha layer and substantia nigra. Pick's bodies and senile plaques could not be found. This case is thought to represent a type of CBD, but with its cortical lesion focus located in the speech area instead of the frontoparietal region. A survey of 28 pathologically evaluated cases of CBD revealed two similar cases, both of which began with progressive aphasia and presented cortical degeneration in the superior temporal gyrus. An overview of CBD cases clarified the features in another group of cases, in which the cerebral accentuated focus was shifted forward from the central region, clinically resembling Pick's disease. The clinical manifestations in

CBD seem to be the expression of these diverse cortical lesions. Primary progressive aphasia may include cases of CBD with involvement of the language center.

Key words Corticobasal degeneration · Primary progressive aphasia · Tau · Cytoskeletal abnormality

Introduction

Since the first report of "corticodentatonigral degeneration" by Rebeitz et al. [20], many reports of cases of this disease entity have accumulated. In most of these cases of corticobasal degeneration (CBD), cortical degeneration is frequently found in the frontoparietal region, especially around the central fissure, and this degeneration seems to correspond to the clinical motor and/or apraxia symptoms characteristic of this disease. Recent advances in silver and immunohistochemical staining methods have brought to light previously unrecognized cytopathological evidence of widespread argyrophilic and tau-positive abnormalities in both neurons and glia [5, 6, 8, 17, 18, 23, 24]. We report a case of CBD in a patient who exhibited primary progressive aphasia and CBD pathology. Together with a survey of CBD cases focusing on the cortical lesions, the diversity of cortical foci of degenerating areas and clinical expression of this disease are discussed.

Case report

The patient was a right-handed female with an unremarkable family history. At the age of 58 years, she became hard of hearing and could not speak clearly. Her ability to understand words deteriorated progressively. At the age of 61 years, she consulted a medical university hospital, where the disturbance of both auditory sensation and language function was pointed out. Thereafter, although she could perform household activities and her daily habits and personality did not change, her language ability gradually deteriorated. She could not understand spoken or written language at all, nor could she write a letter, but she spoke meaningless phrases, and finally she showed sensory aphasia. At 64 years of age, she was admitted to a mental hospital because of a 1-year history of psychomotor excitement and problematic behavior. At the time of

K. Ikeda (✉) · H. Akiyama · S. Iritani · K. Kase · T. Arai
K. Niizato · N. Kuroki · K. Kosaka
Department of Neuropathology, Tokyo Institute of Psychiatry,
2-1-8 Kamikitazawa, Setagaya-ku, Tokyo 156, Japan
Tel.: +81-3-3304-5701 (Ext. 345); Fax: +81-3-3329-8035

K. Ikeda · S. Iritani · K. Kase · T. Arai · K. Niizato · N. Kuroki
Tokyo Metropolitan Matsuzawa Hospital,
2-1-1 Kamikitazawa, Setagayaku, Tokyo 156, Japan

K. Kosaka
Department of Psychiatry,
Yokohama City University School of Medicine, 3-9 Fukuura,
Kanazawa-ku, Yokohama 236, Japan

her admission, although she retained her ability to engage in daily living activities and could manage household affairs somehow, she could only say “chott-chott” and could not understand spoken language at all, later showing total aphasia. On neurological examination, she had muscle rigidity and nuchal dystonia, and had a small-stepped gait. Later, she became apathetic and indifferent to her environment and presented dementia. She was confined to her bed due to pneumonia 8 months after her admission. She had severe neck rigidity, with her neck bent posteriorly and muscle rigidity of the limbs. Disturbance of eye movement was not shown clearly. Eventually she became completely mute and apathetic, and she died at the age of 67 years, 10 years after the onset of symptoms. The clinical diagnosis was atypical Pick’s disease.

Materials and methods

The brain was fixed in 10% neutral formalin. Tissue blocks were embedded in paraffin, and sections were stained with hematoxylin and eosin, Kluever-Barrera, Bodian, modified Gallyas-Braak (G-B) [23], and Holzer methods. For immunohistochemical evaluation, paraffin sections were incubated with primary antibodies for 3 days and then incubated with the biotinylated secondary antibodies for 2 h at room temperature. Sections were then incubated with avidin-biotinylated horseradish peroxidase complex (ABC, Vector), followed by reaction with diaminobenzidine containing nickel ammonium sulfate. The primary antibodies employed in this study were: human-tau (pool 2) (1:50 000, rabbit polyclonal, recognizes the amino acid sequence of 299–385 in the longest isoform of human tau [7]); C5 (1:1000, mouse monoclonal, recognizes phosphorylated epitope of tau at Ser-396); and SMI-31 (1:15 000, mouse monoclonal, Sternberger, recognizes phosphorylated neurofilaments).

Results

Gross findings

The brain weight was 1115 g. External gross examination disclosed atrophy in the frontal and temporal lobes. No laterality of atrophy was noticed. The most severe atrophy was found on both sides of the superior temporal gyri, especially in their posterior two-thirds (Fig. 1, asterisk). The atrophy was markedly diminished in the rest of the temporal lobe. In the frontal lobe, the posterior part of the inferior frontal gyrus, especially the pars opercularis, was most conspicuously atrophic. The parietal and occipital lobes showed externally normal convolutions. The lateral ventricle was dilated markedly with slight flattening of the caudate nuclei and moderate dilatation was noticed in the third ventricle. The substantia nigra was pale.

Microscopic findings

The most pronounced degeneration, consisting of neuronal loss, spongy state and gliosis, was seen in the superior and transverse temporal gyri, where all layers were affected by extreme thinning (Fig. 2). The same type of degeneration was seen in the upper cortical layers of the insular cortex and the basal part of the inferior frontal gyrus. Degeneration, but of a milder degree, extended extensively in the posterior frontal lobe, precentral gyrus, postcentral gyrus,

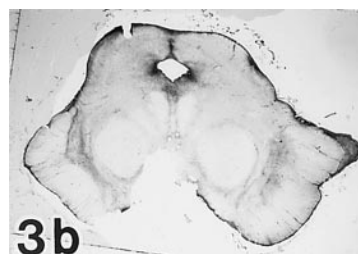
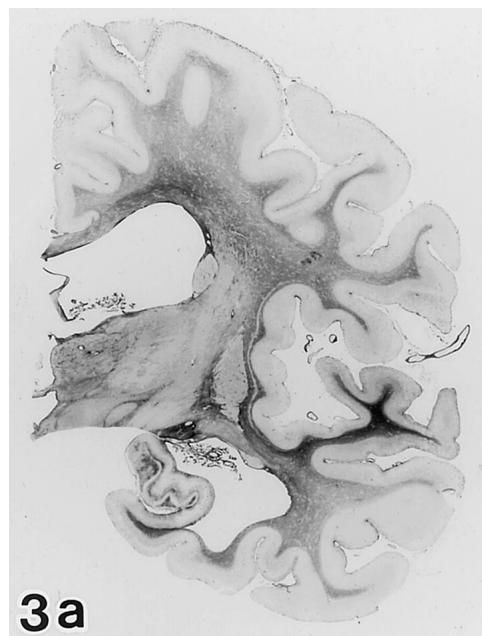
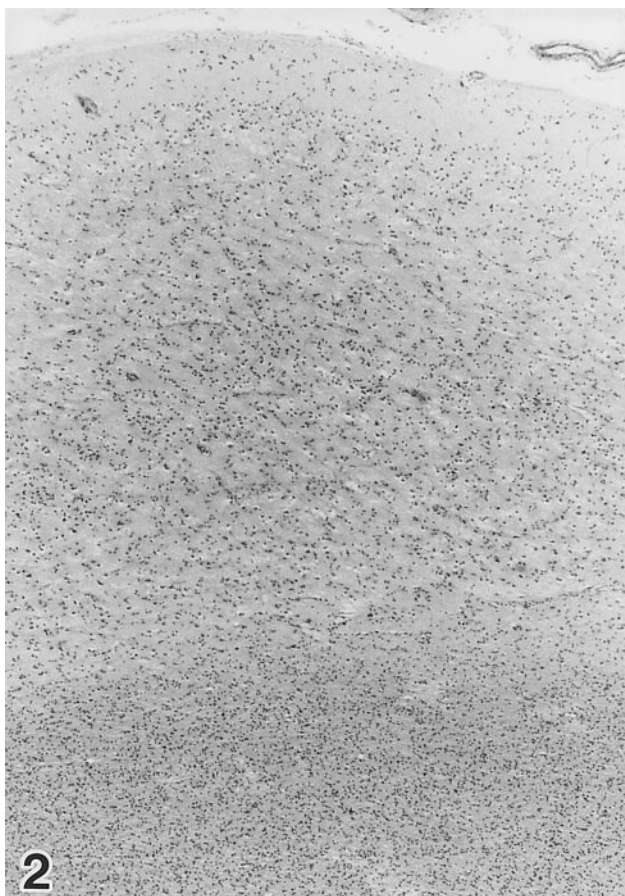
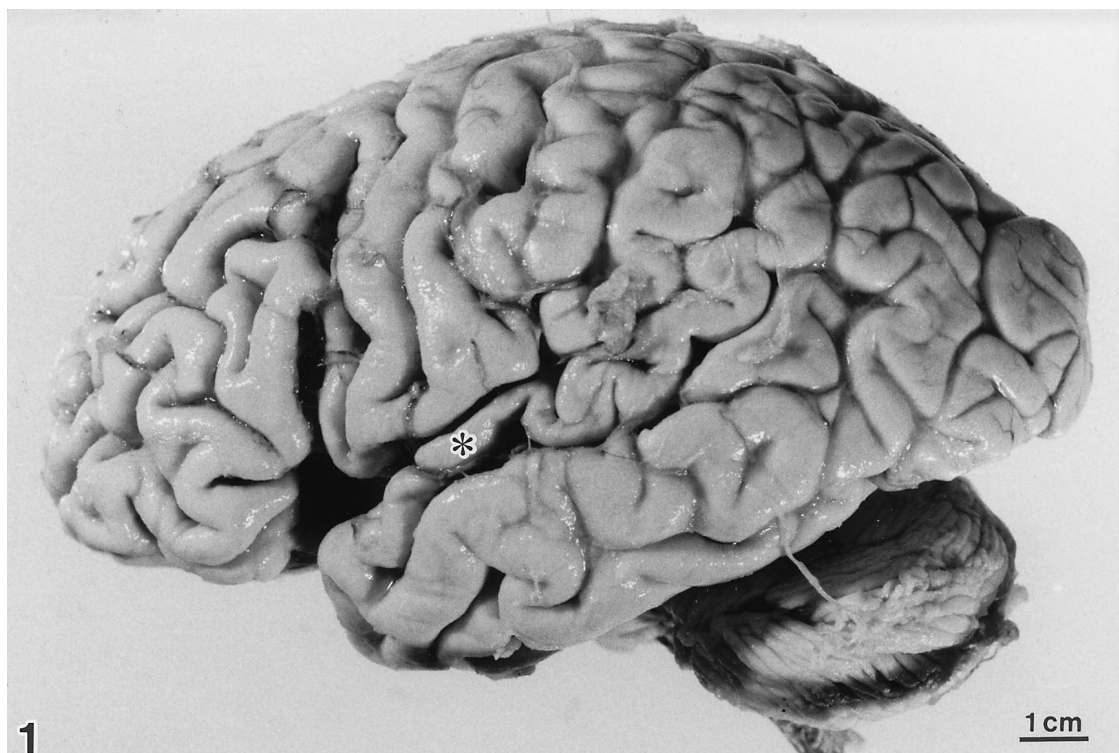
supraparietal lobulus, infraparietal lobulus, and the remainder of the temporal lobe. Diffuse fibrillary gliosis was observed in the white matter with a distribution corresponding to the cortical degeneration (Fig. 3a). The subcortical grey matter presented neuronal loss and gliosis that was severe in the substantia nigra (Fig. 3b), and moderate to slight in the ventral part of the thalamus, globus pallidus, striate body, the lateral part of the amygdaloid nucleus, and the locus ceruleus. Only slight glial proliferation without apparent neuronal depletion was observed in the subthalamic nucleus, red nucleus, dentate nucleus, tectal region of the brain stem, and inferior olivary nucleus.


Accompanying cerebrovascular involvement was not observed. Cytopathologically, achromatic ballooned neurons that reacted with SMI-31 antibody were scattered in the affected cerebral cortex (Fig. 4a, b). On Bodian staining, Pick’s bodies and senile plaques could not be found. Only a few neurofibrillary tangles were found in the entorhinal pre-alpha layer and substantia nigra, where no Lewy bodies were seen. In contrast to the paucity of argyrophilic abnormalities detected by Bodian silver impregnation, the modified G-B method and anti-tau immunostaining revealed various types of cytoskeletal abnormalities, which coincide with those reported in CBD, in both neurons and glia. The most conspicuous finding was the massive argyrophilic and tau-positive fibrillar or granular structures, which we designate argyrophilic threads in this report. Argyrophilic threads were most prominent in the affected cortical and subcortical regions, but they were also observed in the relatively well preserved cortex (Fig. 5). In the subcortical regions, they were distributed preferentially in the thalamus, striatum, pallidum, substantia nigra, tectal area of the brain stem, and inferior olivary nucleus. This distribution pattern of argyrophilic threads was almost equivalent to that of the degenerating area. However, the threads covered a broader area, extending beyond the region of neuronal degeneration. Among the argyrophilic threads, scattered coiled bodies, previously reported to be oligodendroglial [8, 26], were found. Astrocytic plaques (Fig. 6), which are known to be of astrocyte origin [5, 16], were also distributed in the upper cortical layer. Diffusely or granularly argyrophilic and tau-immunolabeled neurons (pre-tangles) were also widely distributed in the degenerating cerebral cortex (Fig. 4 arrows, Fig. 7).

Fig. 1 On the left side, the brain exhibits severe atrophy in the superior temporal gyrus (*asterisk*) and the posterior part of the inferior frontal gyrus. A small defect in the angular region is an artifact at autopsy

Fig. 2 In the superior temporal gyrus, all of the layers show marked degeneration, which consists of neuronal loss, spongy state and glial proliferation. Hematoxylin and eosin, $\times 50$

Fig. 3 Holzer staining reveals fibrillary gliosis most prominently in the atrophied superior temporal gyrus (**a**). The substantia nigra (**b**), globus pallidus (**a**) and a part of the thalamus (**a**) are also sites of degeneration with fibrillary gliosis





Discussion

Although, she ultimately developed severe dementia, our patient showed progressive aphasia without decline of her ability to manage her household in the first several years of illness. Neuropathologically, cerebral involvement was accentuated in the superior temporal gyrus and subsequently in the frontal operculum. The degeneration of subcortical grey matter was most prominent in the substantia nigra, but a lesser degree of degeneration was also seen in the thalamus, globus pallidus and striatum. This regional predilection of degeneration observed in the subcortical grey is analogous to that described in previous reports of CBD [6, 22]. The clinical diagnosis of this case was atypical Pick's disease and it was at first discussed within the context of Pick's disease [14], though crucial contradictions were noticed. Specifically, in Pick's disease, the superior temporal and transverse gyri are usually better preserved than the other temporal gyri [13] and, moreover, the substantia nigra, though its degeneration has been pointed out in some cases [11], is never affected to the severe degree seen in this case. No Pick's body was found in the hippocampal region and the cerebral cortex. The behavioral and personality changes did not occur in this patient until late stages of her clinical course. Pathological findings, particularly the appearance of massive tau-positive structures, differ from the concept of frontotemporal dementia proposed by the Lund and Manchester groups [3]. In recently reported cases of CBD prominent cytoskeletal abnormalities occurring in both neuron and glia are pointed out [5, 8, 9, 17, 18, 23, 24], which had previously not been noticed. Several types of G-B-positive and tau-positive structures are reported to predominate in the degenerating regions. Among them, massive collections of argyrophilic threads, a considerable part of which are thought to occupy the inner and outer loops of myelin [9], are the most prominent finding [23]. Oligodendroglial coiled bodies [2, 10, 26] are also found scattered among these argyrophilic threads. In contrast to the rare occurrence of neurofibrillary tangles, cortical neurons are often diffusely argyrophilic and tau-immunoreactive

Fig. 4 Hematoxylin and eosin staining reveals achromatic ballooned neurons (a), which exhibit a positive reaction to SMI-31 antibody (b). They are scattered throughout the degenerating cerebral cortex. $\times 825$

Fig. 5 Massive tau-positive structures are distributed in a broader area extending beyond the severely degenerated regions. "Argyrophilic threads" form bundles or meshwork. Among them, tau-positive cellular components including pre-tangles (arrows) are also scattered. The precentral gyrus is stained by phosphorylated tau antibody (C5). $\times 170$

Fig. 6 Astrocytic plaques, which originate from protoplasmic astrocytes, are observed mainly in the upper layer of the cerebral cortex. C5 immunostaining. $\times 330$

Fig. 7 Diffusely or granularly tau-immunolabeled neurons (pre-tangles) are commonly found throughout the cerebral cortex but the neurofibrillary tangles cannot be seen. C5 immunostaining. $\times 825$

Table 1 Survey of the initial cerebral symptom and cortical focus in 28 cases of corticobasal degeneration

Author	Age/ sex	Most affected cortical region	Main initial cerebral symptom
Rebeiz et al. (1968)	68/F	Posterior frontal and parietal regions ($r > l$)	Motor and sensory disturbance ($l > r$)
	67/M	Superior frontoparietal region ($r > l$)	Motor and sensory disturbance ($l > r$)
	72/F	Narrowing of frontal convolutions	Walking difficulty
Clark et al. (1986)	63/M	Frontal lobe	Personality change
	72/F	Frontal lobe and superior temporal gyrus	Cognitive decline and dysphasia
Gibb et al. (1989)	71/M	Superior parietal region ($l > r$)	Clumsiness hand ($r > l$)
	65/F	Precentral and postcentral gyri	Speech and gait disturbance
	70/F	Parietal lobe	Clumsiness and alien hand ($l > r$)
Riley et al. (1990)	62/F	Mild gyral atrophy of both cerebral hemispheres	Bradykinesia
	68/M	Central frontoparietal cortex	Clumsiness and apraxia of left hand
Lippa et al. (1990)	78/M	Parasylvian region ($l > r$)	Bradykinesia and nonfluent aphasia
	74/M	Frontal cortical atrophy	Cognitive decline
Paulus and Selim (1990)	58/M	Frontal lobe	Behavioral change and gait disturbance
Nukina et al. (1992)	65/F	Parietal lobe	Clumsiness of left extremities
Mori et al. (1994)	77/F	Precentral gyrus ($l > r$)	Gait and writing difficulty ($r > l$)
	72/F	Precentral gyrus	Clumsiness of right extremities
Uchihara et al. (1994)	68/M	Around central sulcus ($r > l$)	Clumsiness of left hand
Horoupian and Chu (1994)	74/F	Frontal lobe	Clumsiness and weakness of right hand
Rinne et al. (1994)	52/M	Superior parietal cortex ($l > r$)	Walking difficulty
	78/F	Parietal cortex ($l > r$)	Sensory disturbance ($r > l$)
	73/M	Frontal and parietal cortices	Walking difficulty and behavioral disorder
Wakabayashi et al. (1994)	73/M	Frontal and parietal lobes	Language dysfunction
	77/F	Superior frontal gyrus, hippocampus	Cortical dementia
	71/M	Frontal lobe	Not mentioned
Oda et al. (1995)	69/F	Superior frontal gyrus	Personality change and behavioral disorder
Arima et al. (1994)	73/M	Superior temporal gyrus and frontal operculum ($r > l$)	Hearing loss and aphasia
Yoshimura et al. (1995)	49/M	Superior temporal gyrus ($l > r$)	Sensory aphasia
Present case	67/F	Superior temporal gyrus	Hearing loss and sensory aphasia

[23, 24]. In the same cortical area concentric clusters of stubby fibers, which resemble senile plaques, are noted. They were confirmed to be formed in astrocytes and were designated astrocytic plaques; they are one of the characteristic findings of CBD [5] but are also observed in an atypical case of progressive supranuclear palsy [16]. In the present case, all of these abnormal structures were present in the same form as in other reports of cases of CBD describing these structures [5, 23].

Among neuropathologically evaluated cases of CBD (Table 1), some similar cases representing progressive aphasia and accentuated focus in superior temporal gyrus are noticed. Arima et al. [1] described a case of corticonigral degeneration involving Broca's, Wernicke's and supplemental motor areas, which presented primary progressive aphasia and hearing loss as initial symptoms. This case showed accompanying achromatic neurons and argyrophilic, tau-positive inclusions in neurons and later massive collections of argyrophilic threads and coiled bodies were demonstrated [9]. Yoshimura et al. [27] regard a case to be CBD in which slowly progressive aphasia and severe neuronal loss and gliosis with neuronal achromasia in superior temporal gyrus are described. These two cases exhibited serious degeneration in the substantia nigra and degeneration in a part of the thalamus, globus pallidus and striatum. Including our case, these cases form a subgroup of CBD.

The authors's overview of CBD cases also revealed another type, in which the focus of the cerebral lesion is sit-

uated in the frontal region (Table 1). Recently, Oda et al. [18] reported a case of CBD with severe atrophy in the frontal lobe, especially in the superior frontal gyrus, accompanying severe degeneration in the substantia nigra. Though this case was clinically diagnosed as frontal Pick's disease, histological examinations revealed ballooned neurons and massive tau-positive cytoskeletal abnormalities in neurons and glial cells. Rinne et al. [22] mentioned one distinctive case presenting prominent personality and behavioral changes, which resembled Pick's disease. However, this case was pathologically diagnosed as CBD based on the distribution of swollen ballooned neurons in the frontal and parietal lobes in addition to basophilic inclusions in the substantia nigra and other subcortical nuclei. Rinne et al. referred to three similar cases reported by Clark et al. [4], Lippa et al. [12] and Paulus and Selim [19] and discussed the possibility of clinicopathological overlapping of Pick's disease and CBD. Our preliminary survey of 25 cases of clinicopathologically confirmed Pick's disease using the G-B method, however, revealed that none of the Pick's cases showed accompanying massive G-B-positive abnormality except for Pick's bodies and occasional neurofibrillary tangles, coiled bodies or argyrophilic threads (unpublished data).

In summary, CBD has fairly consistent subcortical involvement, which is observed most prominently in the substantia nigra and to a lesser degree in the thalamus, pallidum and striatum, while in almost all cases, the sub-

thalamic nucleus and dentato-rubral system are relatively well preserved. In contrast, the cerebral lesions are rather diverse. In addition to the main group of CBD, in which the main cortical lesion is located around the central fissure, there are some variations of cortical focus, which explains the clinical diversity observed in CBD. This phenomenon bears some resemblance to the features seen in Pick's disease, which includes cortical subtypes other than the common frontotemporal form. The clinical spectrum of primary progressive aphasia is wide-ranging and is presently regarded to be a symptom-complex [25]. Some cases of primary progressive aphasia may be CBD with the prominent cortical lesion in the language center.

Acknowledgements We are very grateful to Drs. H. Mori and Y. Ihara for their generous gift of antibodies. This work was supported by a grant from the Public Health Bureau of Tokyo Metropolitan Government.

References

1. Arima K, Uesugi H, Fujita I, Sakurai Y, Oyanagi S, Andoh S, Izumiya Y, Inose T (1994) Corticonigral degeneration with neuronal achromasia presenting with primary progressive aphasia: ultrastructural and immunocytochemical studies. *J Neurol Sci* 127: 186–197
2. Braak H, Braak E (1989) Cortical and subcortical argyrophilic grains characterize a disease associated with adult onset dementia. *Neuropathol Appl Neurobiol* 15: 13–26
3. Brun A, Englund B, Gustafson L, Passant U, Mann DMA, Neary D, Snowden JS (1994) Clinical and neuropathological criteria for frontotemporal dementia. *J Neurol Neurosurg Psychiatry* 57: 416–418
4. Clark AW, Manz HJ, White CL III, Lehmann J, Miller D, Coyle JT (1986) Cortical degeneration with swollen chromatolytic neurons: its relationship to Pick's disease. *J Neuropathol Exp Neurol* 45: 268–284
5. Feany MB, Dickson DW (1995) Widespread cytoskeletal pathology characterizes corticobasal degeneration. *Am J Pathol* 146: 1388–1396
6. Gibb WRG, Luthert PJ, Marsden CD (1989) Corticobasal degeneration. *Brain* 112: 1171–1192
7. Goedert M, Spillantini MG, Jakes R, Rutherford D, Crowther RA (1989) Multiple isoforms of human microtubule-associated protein tau: sequences and localization in neurofibrillary tangles of Alzheimer's disease. *Neuron* 3: 519–526
8. Horoupian DS, Chu PL (1994) Unusual case of corticobasal degeneration with tau/Gallyas-positive neuronal and glial tangles. *Acta Neuropathol* 88: 592–598
9. Ikeda K, Akiyama H, Haga C, Kondo H, Arima K, Oda T (1994) Argyrophilic thread-like structure in corticobasal degeneration and supranuclear palsy. *Neurosci Lett* 174: 157–159
10. Ikeda K, Akiyama H, Kondo H, Haga C, Tanno E, Tokuda T, Ikeda S (1995) Thorn-shaped astrocytes: possibly secondarily induced tau-positive glial fibrillary tangles. *Acta Neuropathol* 90: 620–625
11. Kosaka K, Ikeda K, Kobayashi K, Mehraein P (1991) Striopallidoligral degeneration in Pick's disease: a clinicopathological study of 41 cases. *J Neurol* 238: 151–160
12. Lippa CF, Smith TW, Fontneau N (1990) Corticonigral degeneration with neuronal achromasia. A clinicopathologic study of two cases. *J Neurol Sci* 98: 301–310
13. Lüers T, Spatz H (1957) Pick'sche Krankheit. In: Scholz W (eds) *Handbuch der speziellen Pathologischen Anatomie und Histologie*, vol XIII/1A, Springer, Berlin Göttingen Heidelberg, pp 614–715
14. Mizukami K, Makino Y, Kobayashi K, Ikeda K, Kosaka K (1990) An autopsy case of atypical Pick's disease with sensory aphasia as an initial symptom (in Japanese) *Jpn J Clin Psychiatry* 32: 899–905
15. Mori H, Nishimura M, Namba Y, Oda M (1994) Corticobasal degeneration: a disease with widespread appearance of abnormal tau and neurofibrillary tangles, and its relation to progressive supranuclear palsy. *Acta Neuropathol* 88: 133–121
16. Nishimura T, Ikeda K, Akiyama H, Kondo H, Kato M, Li F, Iseki E, Kosaka K (1995) Immunohistochemical investigation of tau-positive structures in the cerebral cortex of patients with progressive supranuclear palsy. *Neurosci Lett* 201: 123–126
17. Nukina N, Quan Y, Nakano I, Otomo E (1992) Widespread tau abnormality in a case of corticobasal degeneration (in Japanese). *Clin Neurol* 32: 1093–1101
18. Oda T, Ikeda K, Akamatsu W, Iwabuchi K, Akiyama H, Kondo H, Seta K, Kato Y, Kogure T, Hori K, Tominaga I, Onaya M (1995) An autopsy case of corticobasal degeneration clinically misdiagnosed as Pick's disease (in Japanese). *Psychiatr Neurol Jpn* 97: 757–769
19. Paulus W, Selim M (1990) Corticonigral degeneration with neuronal achromasia and basal neurofibrillary tangles (review). *Acta Neuropathol* 81: 89–94
20. Rebeiz JJ, Kolodny EH, Richardson EP Jr (1968) Corticodentatonigral degeneration with neuronal achromasia. *Arch Neurol* 18: 20–33
21. Riley DE, Lang AE, Lewis A, Resch L, Ashby P, Hornykiewicz O, Black S (1990) Cortico-basal ganglionic degeneration. *Neurology* 40: 1203–1212
22. Rinne JO, Lee MS, Thompson PD, Marsden CD (1994) Corticobasal degeneration. A clinical study of 36 cases. *Brain* 117: 1183–1196
23. Uchiyama T, Mitani K, Mori H, Kondo H, Yamada M, Ikeda K (1994) Abnormal cytoskeletal pathology peculiar to corticobasal degeneration is different from that of Alzheimer's disease or progressive supranuclear palsy. *Acta Neuropathol* 88: 379–383
24. Wakabayashi K, Oyanagi K, Makifuchi T, Ikuta F, Homma Y, Horikawa Y, Tokiguchi S (1994) Corticobasal degeneration: etiopathological significance of the cytoskeletal alterations. *Acta Neuropathol* 87: 545–553
25. Weintraub S, Rubin NP, Mesulam MM (1990) Primary progressive aphasia. Longitudinal course, neuropsychological profile, and language features. *Arch Neurol* 47: 1329–1335
26. Yamada T, McGeer PL (1990) Oligodendroglial microtubular masses: an abnormality observed in some human neurodegenerative diseases. *Neurosci Lett* 120: 163–166
27. Yoshimura I, Yoshimura N, Hayashi S, Tasaki H, Fukushima Y (1995) A clinicopathological study of senile dementia presenting as progressive sensory aphasia; a variant of corticobasal degeneration (in Japanese). *Jpn J Clin Psychiatry* 24: 193–200