

Hereditary neurocutaneous angiomatosis

Report of four cases

**RICHARD LEBLANC, M.D., F.R.C.S.(C), DENIS MELANSON, M.D.,
AND RALPH D. WILKINSON, M.D., F.R.C.P.(C)**

*Departments of Neurology and Neurosurgery, Neuroradiology, and Dermatology, Montreal
Neurological Institute and Hospital and Royal Victoria Hospital, McGill University, Montreal,
Quebec, Canada*

✓ The authors report the coexistence of vascular nevi (hemangiomas and arteriovenous malformations (AVMs) of the skin) with AVMs and venous malformations of the brain in male sibs from two related but nonconsanguineous families of three generations.

The proband, his sibs, parents, aunts, uncles, and cousins were examined, underwent magnetic resonance (MR) imaging and MR angiography, and when appropriate, cerebral angiography. A father had vascular nevi and a mother, his sister, had an azygos anterior cerebral artery. No other cutaneous or cerebrovascular malformations were present in the parents. Each of the two families had two boys and one girl, 9 to 18 years of age. All the children had vascular nevi and all of the boys had coexisting cerebrovascular malformations: AVMs in three, and a venous malformation in another. One boy had three cerebral AVMs. Two boys had a cerebral hemorrhage, and one also had focal motor seizures. The skin lesions were not those of the Sturge-Weber-Dimitri, Rendu-Osler-Weber, or Wyburn-Mason syndromes.

The association of cutaneous and cerebrovascular malformations was seen only in males in these families, but females have also been reported in the literature. The results obtained in these families and three other families reported from Western and Central Europe indicate that the association of cerebral and cutaneous vascular hamartomas constitutes a distinct, hereditary clinicopathological entity with autosomal dominant inheritance and variable penetrance. The clinical manifestations of this syndrome are visible, painful vascular nevi, epilepsy, cerebral hemorrhage, and focal neurological deficits.

The preponderance of male patients with the full expression of the syndrome suggests a possible hormonal influence on the expression of the gene.

KEY WORDS • arteriovenous malformations • blue rubber bleb nevus syndrome • cavernous hemangioma • phacomatoses • telangiectasis

IN their various forms, cerebrovascular malformations may be seen in approximately 5% of unselected autopsies.²³ They are usually asymptomatic but can produce focal and generalized seizures, cerebral hemorrhage, and neurological deficits. Although cerebrovascular malformations are usually sporadic, familial forms have been described.²⁵ Some types of cerebrovascular malformations such as capillary telangiectasias and venous malformations are part of distinct, well-characterized neurocutaneous syndromes, such as Rendu-Osler-Weber and Sturge-Weber-Dimitri disease, respectively.²⁷ Cerebrovascular malformations have also been reported in less well-characterized disorders where coexisting cutaneous vascular hamartomas are a prominent feature.³⁸ We report the association of cerebral arteriovenous and venous malformations and vascular nevi in four boys from three generations of two related, but not consanguineous, families (Generations I, II, and III), and we discuss other reported cases that suggest this association constitutes a distinct,

hereditary, clinicopathological entity with autosomal dominant inheritance.

Study Methods and Families

The proband, a 15-year-old boy (Case 3, Generation III, No. 4), was referred to us because he had a cerebellar arteriovenous malformation (AVM). The family history revealed a similar lesion in a male cousin (Case 2; Generation III, No. 1) as well as a family history of cutaneous lesions, which prompted examination and investigation of his sibs, his parents, his cousins, and their parents (Fig. 1). These family members underwent magnetic resonance (MR) imaging, MR angiography, and intraarterial digital subtraction angiography when MR imaging and angiography were abnormal. The medical records were obtained for those individuals having undergone surgical procedures. Further details of the family were provided by individuals in Generation II (Nos. 4, 5, 7, and 8), the par-

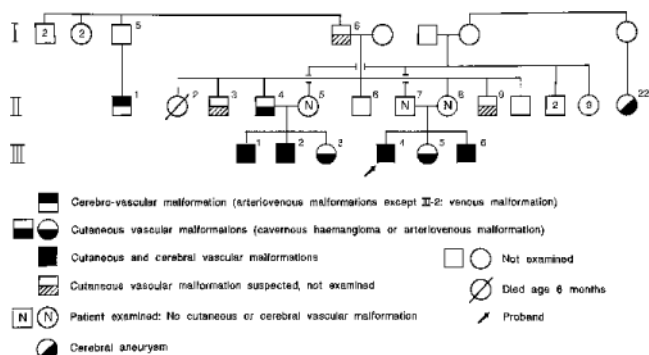


FIG. 1. Pedigree of the families reported. Squares indicate males and circles females.

ents of the six Generation III children. One individual in Generation II refused examination, but his medical records were available for review. From the second generation, one individual (No. 4) is the brother of an individual (No. 8) who is married to a man (No. 7), the brother of individual No. 5 who is married to individual No. 4. Thus a brother and sister from one family married a sister and brother from the other. All the individuals are from a small, remote region of New Brunswick, Canada. There is no known consanguinity with the exception of the grandfather (of the individuals in Generation II, Nos. 5 and 6) who had a child by one of his nieces.

Generation I

One individual (Generation I, No. 6) is reported to have cutaneous lesions on the lip and eyelid similar to those of the patient in Case 4 (Generation III, No. 6).

Generation II

One man in Generation II (No. 1) had an angiographically and surgically proven cerebral AVM discovered following a cerebral hemorrhage. His medical records do not reveal skin lesions, but there is no indication that these were specifically searched for. Individual No. 2 died of pneumonia at age 6 months.

Individual No. 3 is reported to have cutaneous lesions on the wrist similar to those of Individual No. 4, who has a bluish-tinged, soft, nonpulsatile, 1-cm-diameter subcutaneous lesion of the forehead; a 1.8-cm-diameter, firm, nonpulsatile subcutaneous lesion of the left wrist; and a 4-mm cavernous hemangioma of the tip of the tongue. Magnetic resonance imaging and MR angiography are normal.

Individual No. 5 has no cutaneous lesions. Her fundoscopic examination as well as her MR imaging studies are normal.

Individual No. 7 has no cutaneous lesions and MR imaging and MR angiography are normal. The sequelae of a previous retinal hemorrhage of unknown etiology were noted in the right retina.

Individual No. 8 has no cutaneous lesions except for freckles. Whereas her fundoscopic examination and MR images are normal, MR angiography and cerebral angiography demonstrated an azygos anterior cerebral artery, a

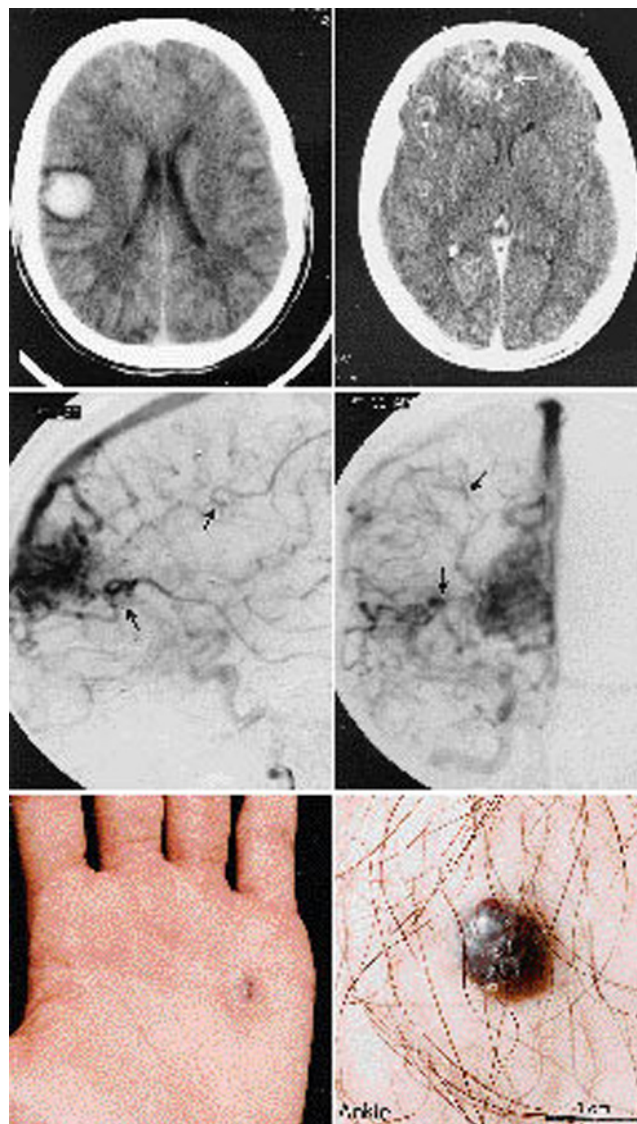


FIG. 2. Case 1. Initial noninfused computerized tomography (CT) scans, carotid angiograms, and photographs showing vascular nevi. Upper: Computerized tomography scans demonstrating a right central intracerebral hematoma, a right frontopolar cerebral arteriovenous malformation (AVM) (large arrow), and an AVM in the right subopercular region of the frontal lobe (small arrow), both distant from the hematoma. Center: Right internal carotid artery angiograms demonstrating three cerebral AVMs. The largest is frontopolar where a large agglomeration of cerebral blood vessels is seen with shunting of blood through early draining veins. Two smaller AVMs with early draining veins are indicated by the arrows. The smallest AVM is the one that produced the cerebral hematoma seen on the CT scans. Lower: Photograph of the patient's palm (left) revealing a subcutaneous lesion (approximately 0.75 cm in largest diameter) diagnosed as a cavernous hemangioma on the basis of inspection and palpation; photograph of the patient's ankle (right) demonstrates a similar lesion of similar size.

variant of normal.

Individual No. 9 is reported to have cutaneous lesions on a wrist similar to those of Individual No. 4.

The siblings of Generation II individuals (Nos. 5 and 7) were interviewed by telephone; none reported having

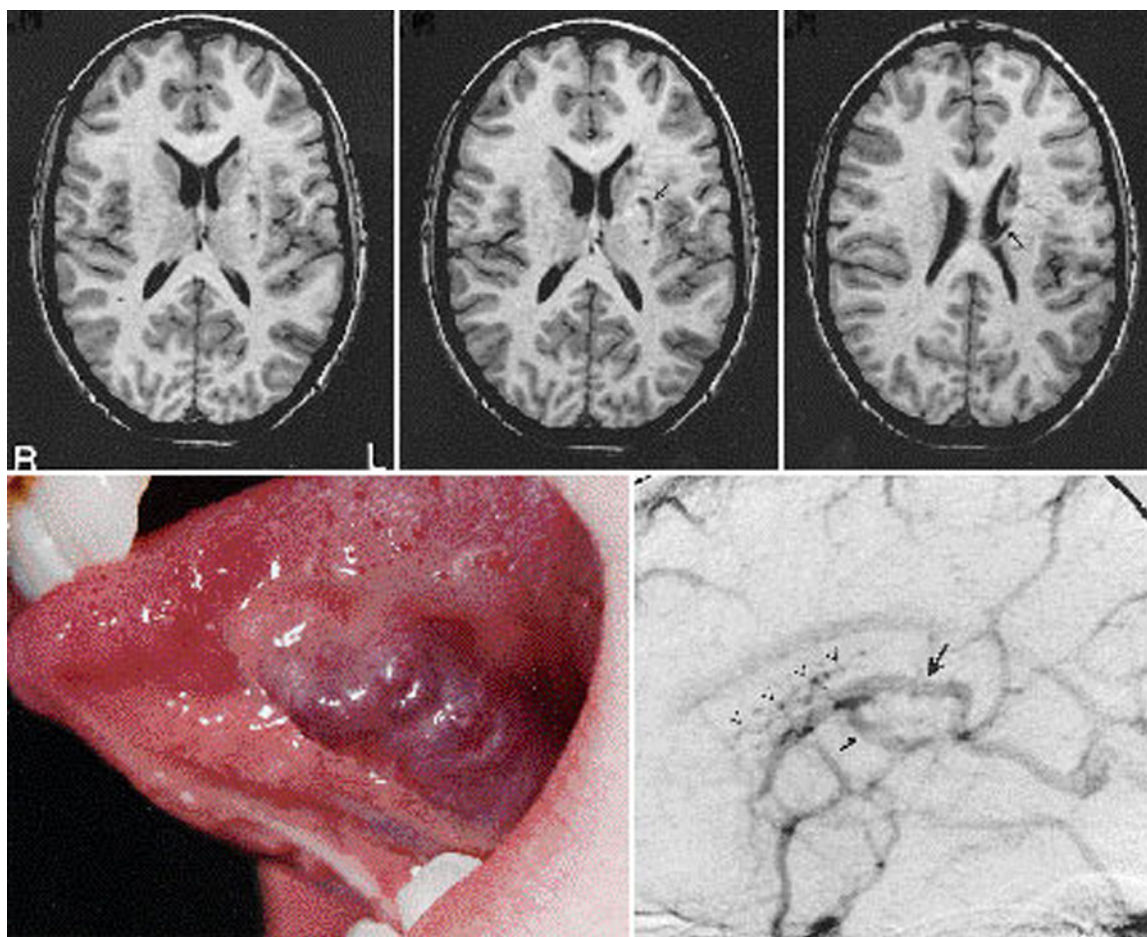


FIG. 3. Case 2. *Upper:* Magnetic resonance (MR) images showing punctate, filiform, and serpentine lesions in the region of the left (L) basal ganglia associated with two large draining veins (*arrows*). *Lower Left:* Photograph demonstrating a large lesion of the tongue diagnosed as a cavernous hemangioma on the basis of inspection and palpation. *Lower Right:* Venous phase of a left internal carotid artery angiogram demonstrating the punctate and filiform lesions seen on MR imaging to be small, Medusa-like venous channels (*arrowheads*) drained by a monstrosly enlarged caudate vein (*large arrow*) and tributaries (*small arrow*).

nevi. One relative (Generation II, No. 22), however, died at age 32 years from a ruptured aneurysm of the left middle cerebral artery.

Generation III

Case 1. This 18-year-old man (Case 1; Generation III, No. 1) had histologically proven cutaneous cavernous hemangiomas removed from the scapula and deltoid regions at 8 years of age. He also has palmar and plantar dark red cavernous hemangiomas of varying sizes, the largest being 1 cm in diameter in his right palm (Fig. 2). There are no mucosal lesions, and he has no gastrointestinal complaints. Fundoscopic examination is normal. At the age of 18 years he developed focal motor seizures characterized by twitching of the left side of the face. The onset of seizures was shortly followed by a right posterior frontal cerebral hemorrhage from an angiographically proven small cortical AVM. Angiography also disclosed two larger, distinct AVMs in the mesiofrontal and frontal opercular areas (Fig. 2).

Case 2. At the age of 13 years, the patient in Case 2 (Generation III, No. 2) has a 2- to 3-cm, bluish cavernous hemangioma of the left lower tongue (Fig. 3) and a stellate-shaped telangiectactic macule of the right infraauricular area. Fundoscopic examination is normal. There are no gastrointestinal complaints. Magnetic resonance imaging and cerebral angiography demonstrated a left paraventricular venous malformation (Fig. 3).

His 9-year-old sister (Generation III, No. 3) had a histologically proven cutaneous cavernous hemangioma of the right thigh removed at age 4 years. Fundoscopic examination is normal. There are no gastrointestinal complaints. Her MR imaging and MR angiography are normal.

Case 3. The patient in Case 3 (Generation III, No. 4) had complained of visual disturbances 1 year before coming to our attention. A CT scan had revealed the characteristic appearance of orbital pseudotumor and suggested the presence of a cerebrovascular anomaly of the left cerebellum. There was a 3-mm mobile nontender, compressible subcutaneous nodule of the scalp above the left pinna. A

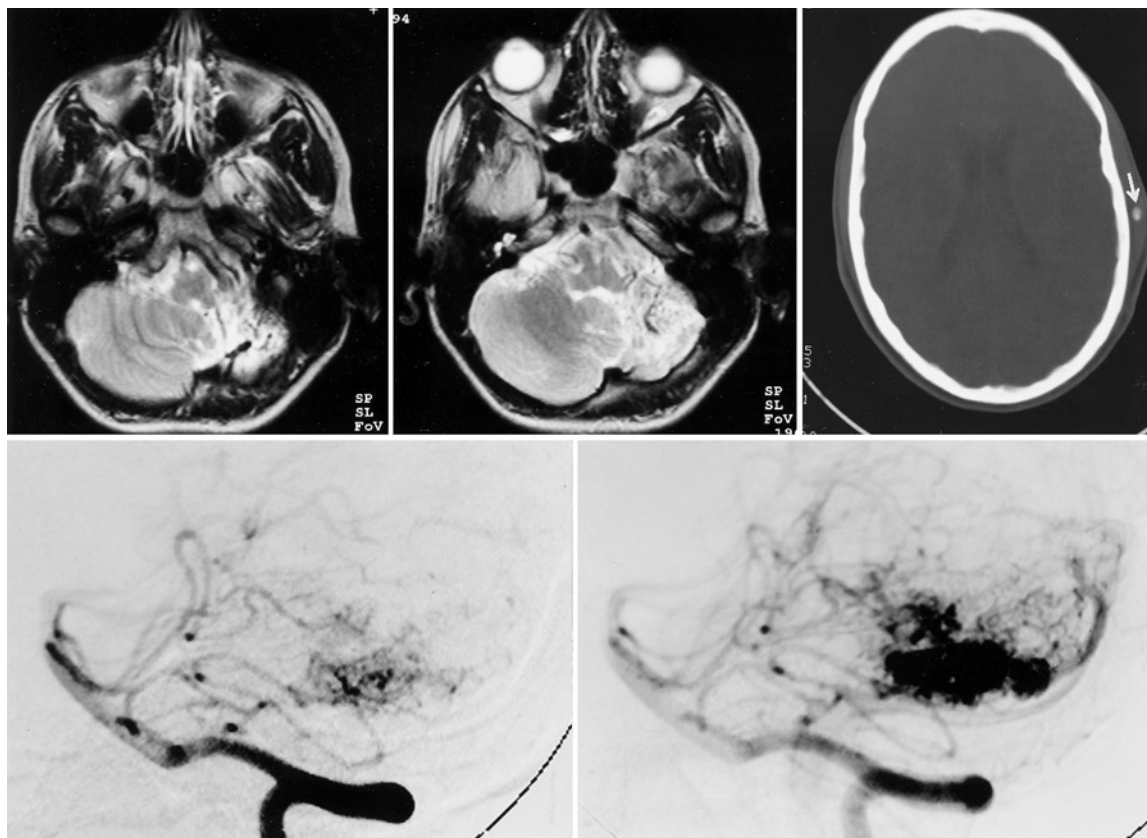


FIG. 4. Case 3. Magnetic resonance (MR) images, computerized tomography (CT) scan, and vertebral angiograms in the proband. The MR images (*upper left and center*) show the left cerebellar arteriovenous malformation (AVM) and hypoplasia of the left cerebellar hemisphere and tonsil. The CT scan (*upper right*) shows a subcutaneous phlebolith (*arrow*) from a subcutaneous hemangioma in the left temporal region ipsilateral to the AVM. A small vascular lesion was also present, largely subcutaneous, in the ipsilateral palm. Vertebral angiograms (*lower left and right*) confirm the cerebellar lesion as an AVM.

subcutaneous Doppler study of the head demonstrated low-flow vascular cavities, which suggested a cavernous angioma with associated phlebolith (Fig. 4). A 4-mm spiderlike vascular nevus of the left hypothenar eminence was also present. Funduscopic examination was normal. He has no gastrointestinal complaints. A left cerebellar AVM was demonstrated by MR imaging, MR angiography, and cerebral angiography as well as left cerebellar hypoplasia (Fig. 4). A spina bifida occulta of the arch of the C-1 vertebra, with fusion of the right arch to the occiput, fusion of the bodies of C2-3, and a spina bifida occulta of the arch of S-1 were noted on x-ray films. His cerebral AVM was removed surgically. Marked hemosiderin staining, reflecting previous hemorrhage, was seen in the surrounding cortex, and there was hypoplasia of the left cerebellar hemisphere and tonsil.

His sister, a 13-year-old girl (Generation III, No. 5), has a tender, bluish, soft and mobile 1.5-cm-diameter vascular nevus of the right forearm consistent with a cavernous hemangioma, as well as a blue nevus of the right helix. Her funduscopic examination is normal. She has occasional nonspecific abdominal pain. Her imaging studies are normal.

Case 4. The patient in Case 4 (Generation III, No. 6), 9

years of age, had a cutaneous, histologically proven AVM removed from the right side of the neck at 6 years of age. There was a purple, spiderlike, nonpulsatile area with a prominent local venous pattern on the right forearm topped with three small spider nevi, compatible with a cavernous hemangioma (Fig. 5). A soft, poorly defined papule of the right upper eyelid was also present. Funduscopic examination is normal. There are no gastrointestinal complaints. Magnetic resonance imaging, MR angiography, and cerebral angiography demonstrated a large AVM of the right temporal lobe (Fig. 5).

Discussion

Cerebrovascular Malformations

Cerebrovascular malformations are properly considered as hamartomas²⁸ and are usually classified as capillary telangiectases, cavernous hemangiomas, AVMs, and venous malformations. Disturbances and arrests during a particular period of development may determine the type and the location (dural, pial, parenchymal) of the malformation.⁴ Thus, interference prior to differentiation into arteries, veins, and capillaries may result in the development of cavernous hemangiomas or AVMs.

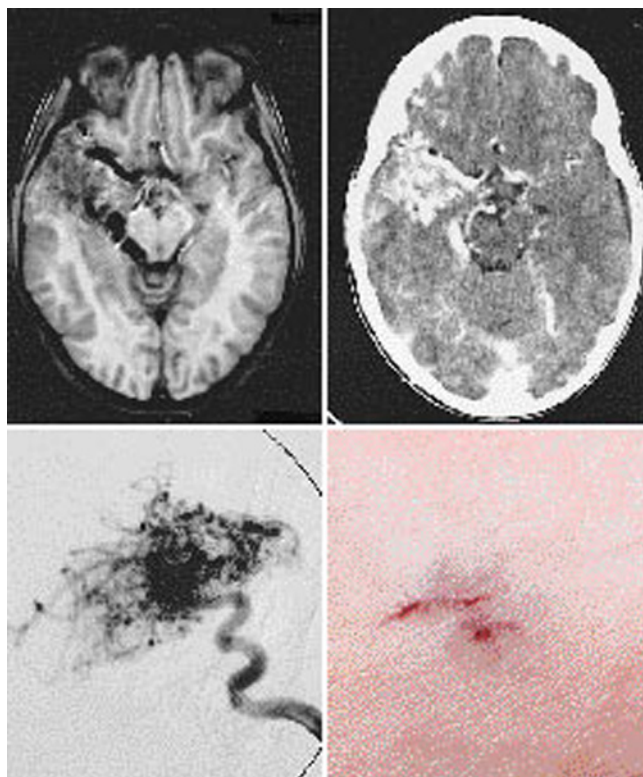


FIG. 5. Case 4. Magnetic resonance (MR) image, infused computerized tomography (CT) scan (*upper*), internal carotid artery angiogram, and photograph showing vascular nevus. The MR image (*upper left*) and CT scan (*upper right*) demonstrate abnormally enlarged arteries and veins and a nidus of abnormal blood vessels in the right temporal lobe. Carotid angiography (*lower left*) confirms this lesion to be a cerebral arteriovenous malformation. The photograph (*lower right*) of the forearm demonstrates the spiderlike vascular nevus measuring approximately 0.75 cm in largest diameter diagnosed by inspection and palpation.

Cerebral AVMs are characterized by an agglomeration of abnormally formed arteries and veins, with deficient and altered muscular and elastic layers.^{15,28} There is no distinct capillary network between the elongated and dilated feeding arteries and the enlarged sinuous draining veins that contain arterialized blood under high pressure (Fig. 2).¹⁵ The surrounding cortex is usually atrophic. The atrophy may result from maldevelopment, repeated microhemorrhages, or chronic ischemia. Cerebral AVMs are present at birth and frequently produce symptoms in adolescence or early adulthood, although they can become manifest at any age²² or remain clinically silent throughout life. Men and women are equally affected. Their clinical manifestations are focal or generalized epilepsy, intracranial, usually intraparenchymal, hemorrhage that produces acute focal neurological deficits and progressive neurological deficits as perfusional flow is diverted from the surrounding brain through the arteriovenous fistula.²⁰ Although rare familial clusters of cerebral AVMs have been reported, a pattern of inheritance has not been defined.^{1,6,32,40} One of the familial patients reported had labial nevi.⁶ Cerebral AVMs, usually located in the mid-

brain, can coexist in association with ipsilateral cutaneous, retinal, and mandibular or maxillary AVMs (the Bonnet-Deschaume-Blanc syndrome, otherwise known as the Wyburn-Mason syndrome).³⁴ Although two of our patients had retinal lesions, these were not vascular in nature, and the patients did not have AVMs at the other sites characteristic of the Wyburn-Mason syndrome.

Cavernous hemangiomas are composed of abnormally dilated blood vessels that resemble veins without intervening neural tissue.²⁸ They often involve the cerebral hemispheres (where they can produce epileptic seizures), the pons, and the basal ganglia. They are frequently multiple and can produce cerebral hemorrhage. Familial cases of cavernous angiomas transmitted through an autosomal dominant pattern have been described in Hispanic populations, among others.²⁵

Capillary telangiectases are composed of small clusters of abnormally dilated capillaries.²⁸ They frequently affect the pons as well as the cerebral and cerebellar hemispheres and basal ganglia and are usually found incidentally at autopsy. Cerebral capillary telangiectases (and, less frequently, cerebral AVMs) have been described as a feature of Rendu-Osler-Weber disease.^{17,27} The nature of the cutaneous lesions in our patients excludes this diagnosis.

Venous malformations are composed of single or multiple enlarged veins that drain normal cerebral tissue (Fig. 3). They are usually clinically silent although they can, rarely, cause cerebral hemorrhage. Cerebral venous malformations have been described in patients with the blue rubber bleb nevus syndrome (BRBNS).

Capillary hemangioblastomas are true tumours of cerebral blood vessels. They occur sporadically or as part of Von Hippel-Lindau disease.²⁷ In this condition there is coexistence of cerebral capillary hemangioblastomas and vascular lesions of the retina, multiple cysts of the kidneys and pancreas, and renal cell carcinoma. Capillary nevi of the skin may also be present. The radiological appearance and histology in the patient in Case 3 rule out capillary hemangioblastomas as a diagnosis.

The individual in Generation II, No. 9, had a cerebral aneurysm. Although familial clusters of cerebral aneurysms have been described,²¹ these lesions are usually believed to result from atherosclerotic changes related, perhaps, to hemodynamic stress. We have encountered two other families with cerebral AVMs and aneurysms in different individuals, in the absence of vascular nevi.

Phacomatoses

The coexistence of congenital anomalies involving the skin, the retina, and the central nervous system has long been recognized. These conditions are termed phacomatoses, after the Greek for lens, in reference to the morphology of the cutaneous lesions (Table 1).²⁷ Malformations of blood vessels are prominent features of some of the phacomatoses. Besides Von Hippel-Lindau's disease discussed above, the phacomatoses include encephalotrigeminal angiomatosis (Sturge-Weber-Dimitri disease), which is characterized by a port-wine discoloration of the face in the distribution of the trigeminal nerve and extensive venous malformations of the leptomeninges overlying an atrophic cerebral hemisphere;

TABLE 1
Classification of vascular neurocutaneous syndromes

phacomatoses
hereditary hemorrhagic telangiectasia (Rendu-Osler-Weber disease)
encephalotrigeminal angiomatosis (Sturge-Weber-Dimitri disease)
von Hippel-Lindau disease
neurofibromatosis (von Recklinghausen's disease)
ataxia telangiectasia (Louis-Bar disease)
hereditary neurocutaneous angiomatosis*
neurocutaneous vascular hamartomas
cerebroretinal arteriovenous malformations (Bonnet-Deschaume-Blanc syndrome; Wyburn-Mason syndrome)
multiple (systemic) hemangiomatosis
the blue rubber bleb nevus syndrome
cutaneomeningospinal angiomatosis (Cobb's syndrome)

* As proposed in this report.

hereditary hemorrhagic telangiectasia (Rendu-Osler-Weber disease) that can be accompanied by cerebral telangiectases and, occasionally, by multiple cerebral AVMs; and central neurofibromatosis (von Recklinghausen's disease), which can be associated with meningeal or cortical angiomatosis characterized by thick-walled, fibrosed, and hyalinized cerebral blood vessels.^{17,27} Ataxia telangiectasia (Louis-Bar syndrome) is characterized by the presence of oculocutaneous telangiectases and cerebellar ataxia. It is sometimes associated with dilated cerebellar venules. Tuberous sclerosis (Bourneville's disease) is not associated with cerebrovascular anomalies.²⁷ The cutaneous and the cerebrovascular lesions in our patients are not those of the classically described phacomatoses.

Neurocutaneous Vascular Hamartomas

Vascular hamartomas of the skin and central nervous system occur in the Bonnet-Deschaume-Blanc (or Wyburn-Mason) syndrome, in multiple (systemic) hemangiomatosis, in the BRBNS, in cutaneomeningospinal angiomatosis, sometimes referred to as Cobb's syndrome,² and in what has been referred to as hereditary neurocutaneous angiomas,⁴¹ as exemplified by our patients (Table 1).

Multiple (Systemic) Hemangiomatosis. Multiple hemangiomatosis is seen most commonly in infants but has been described in older patients.^{8,12,32} Multiple organs are affected including skin and viscera, as well as the central and peripheral nervous systems, including the cerebral hemispheres, the pons, medulla, spinal cord, and peripheral nerves. Hundreds of lesions are usually present and are usually cavernous hemangiomas. The patients, usually infants, present with hydrocephalus and epilepsy.

Blue Rubber Bleb Nevus Syndrome. The BRBNS, as originally described by Bean in 1958,³ includes characteristic bluish cavernous hemangiomas of the skin in association with cavernous hemangiomas of the gastrointestinal tract. Although most cases of BRBNS appear to be sporadic, a familial autosomal dominant form has been described.^{5,19,24,35} Variable penetrance may be operant in this condition, and there may be increased penetrance in males.³³ Cutaneous cavernous hemangiomas characteristically appear as a bluish nevus of the skin, the larger nevi

having the look and feel of rubber nipples (Fig. 2).³ They are compressible and fill promptly.³ They frequently involve the upper extremities and trunk and produce local pain and tenderness. Gastrointestinal involvement is predominantly of the small intestine and of the distal colon and rectum, producing gastrointestinal hemorrhage, iron deficiency anemia, or bowel obstruction. The tongue can also be involved as occurred in a father and son (Generation II, No. 4 and Generation III, No. 2, respectively), and the son also harbored a cerebral venous malformation (Fig. 3).

The first unequivocal report of a cerebrovascular malformation associated with the BRBNS was that by Waybright, *et al.*,³⁷ who described a 19-year-old man with BRBNS and cortical cavernous hemangiomas, capillary telangiectasias, and a thrombosed AVM of the vein of Galen. This case was studied histologically and may represent an overlap between the BRBNS and the Rendu-Osler-Weber syndrome.²⁶ Satya-Murti, *et al.*,²⁹ described a 19-year-old man with the BRBNS and frontoparietal and caudate "angiomas" and a large "angioma" of the cerebellum. The lesions reported by Satya-Murti, *et al.*, did not exhibit arteriovenous shunting on angiography, the hallmark of AVMs.¹ Sherry, *et al.*,³⁰ described a 6-month-old boy with the BRBNS and a cerebral venous malformation demonstrated by CT and angiography. Bean³ described a patient with the BRBNS and epilepsy, although the presence or absence of a cerebrovascular malformation in that patient was not ascertained. Branch, *et al.*,⁷ reported the case of a 19-year-old man with an isolated cavernous hemangioma of the tongue and a venous malformation of the brain; and Waybright, *et al.*,³⁶ in 1981, also reported a patient with bilateral cavernous hemangiomas of the sublingual mucosa and what appears to be a small cerebral venous malformation. It is unclear whether these patients had BRBNS or a sublingual hemangioma in isolation.

The vascular nevi in some of our patients are compatible with those seen in BRBNS. However, in the absence of gastrointestinal involvement, with the exception of the tongue in the individuals in Generation II, No. 4 and Generation III, No. 2, a formal diagnosis of BRBNS cannot be made. It is possible that the individuals that we report have a variant of BRBNS in which cerebrovascular lesions predominate over the putative gastrointestinal lesions, or that they have a condition that, save for the vascular nevi, is unrelated to BRBNS: hereditary neurocutaneous angiomatosis, discussed below.

Cutaneomeningospinal Angiomatosis. Cutaneomeningospinal angiomatosis, sometimes also termed dermatospinal angioma, was first described in 1915 by Cobb^{9,10} in an 8-year-old boy with paraplegia and a port-wine stain overlying a dermatome, demarcating the sensory level compatible with the paraplegia. Cushing suggested that, by analogy with the then newly described Sturge-Weber-Dimitri syndrome, the child must have a vascular lesion underlying the port-wine stain. An "angioma" was found at surgery (the published operative drawing illustrates an AVM), and the association of cutaneous and spinal vascular malformations is sometimes now referred to, perhaps unfairly to Cushing, as Cobb's syndrome. Kaplan, *et al.*,¹⁶ reported the case of a 16-month-old girl with paraplegia and sensory level at L-2 from a spinal AVM who had multiple telangiectatic nevi flammei, including one at the L-3

Hereditary neurocutaneous angiomatosis

or L-4 dermatome.¹⁶ Her mother, maternal grandmother, a maternal great uncle, and a maternal uncle had cutaneous hemangiomas, albeit without neurological symptoms. Zaremba, *et al.*,⁴¹ similarly reported the case of a 13-year-old boy with a family history of cutaneous hemangioma planum who also had a spinal AVM; and Foo, *et al.*,¹¹ also reported the case of a 33-year-old man with numerous cutaneous hemangiomas and a spinal AVM whose mother, brother, and sister had similar skin lesions but no neurological symptoms.

Hereditary Neurocutaneous Angiomatosis. Zaremba, *et al.*,⁴¹ and Hurst and Baraitser¹³ reported familial cases similar to ours. The patient reported by Zaremba, *et al.*, was a 28-year-old man who died due to a cerebral hemorrhage from the rupture of a frontoparietal AVM. He had numerous cutaneous hemangiomas planum, and his daughter had similar cutaneous lesions but no neurological symptoms. His 13-year-old brother, discussed above, also had similar skin lesions and a spinal AVM. His father, who also had vascular nevi, had an acute hemiplegia, the cause of which was not diagnosed. The pattern of inheritance was thought to be autosomal dominant. Hurst and Baraitser¹³ reported similar patients from two different families. In the first family a 30-year-old woman with multiple cutaneous hemangiomas was rendered hemiplegic from a ruptured AVM in the internal capsule. Her father, daughter, and a grandson had similar vascular nevi but no neurological symptoms, and a 2-year-old granddaughter had a temporal lobe AVM and cerebral seizures but no vascular skin lesions. In the second family a 7-month-old boy with cutaneous hemangiomas had hydrocephalus associated with a paramedian AVM. His father had similar skin lesions but no neurological symptoms.

We believe that, along with the two families we present, the families described by Kaplan, *et al.*, Zaremba, *et al.*, Foo, *et al.*, and by Hurst and Baraitser, identifying cases from North America and Western and Central Europe, delineate a distinct hereditary cerebrovascular neurocutaneous clinicopathological entity with autosomal dominant inheritance and variable penetrance. The preponderance of males with the full neurovascular expression of the syndrome as opposed to just the cutaneous manifestations indicates a possible hormonal influence on the expression of the gene. The presence of cerebellar dysgenesis in our Case 3 (Generation III, No. 4) suggests that this condition may be properly included within the category of phacomatoses.

Conclusions

We report the familial association of vascular nevi, mainly cavernous hemangiomas, and vascular malformations of the brain. The clinical manifestations of this association include visible, tender cutaneous and lingual vascular malformations and epilepsy, cerebral hemorrhage, and focal neurological deficits as the cerebrovascular lesions, especially the AVMs, become symptomatic; and quadra- or paraplegia in patients with the spinal form. In the two individuals in whom the vascular nevi were unilateral, the cerebrovascular malformations were ipsilateral to the skin lesions (Cases 3 and 4) and the patient with bilateral vascular nevi (Case 2) also had a cavernous angioma of the tongue that was ipsilateral to his cerebral

venous malformation. The prevalence of coexisting cutaneous and cerebrovascular malformations is unknown. Yaşargil³⁹ has observed that 0.5% of his patients with cerebral AVMs have "cutaneous angiomas." Noninvasive MR imaging and MR angiography make it possible to screen individuals with cutaneous or sublingual vascular malformations for the presence of cerebrovascular anomalies. At this time, the yield of such screening can only be conjectural. One of our patients also had cerebellar dysgenesis and malformations of the spinal column. Thus these phenotypic expressions may also come to be considered an integral part of the hereditary neurocutaneous angiomatosis syndrome. The mode of inheritance of the cerebral and cutaneous vascular malformations in our two families and in other reported families appears to be autosomal dominant with variable penetrance. The cerebral and the spinal forms can coexist in different individuals of the same family, and as is the case in hereditary hemorrhagic telangiectasia, phenotypic variations within the same family can occur, with some individuals having only the skin lesions and not the cerebral ones, or vice versa. A possible hormonal influence is suggested by the full expression of coexisting cerebral and cutaneous vascular hamartomas mainly in males.

Acknowledgments

We are grateful to Dr. Antoine Salloum, Moncton Hospital, for permission to study one of these patients; Dr. Gilbert Quartey, Moncton Hospital, for referring the proband; Dr. Trevor Kirkham, Montreal Neurological Hospital, for performing the neuroophthalmological examinations; Dr. Donatella Tampieri of the Montreal Neurological Hospital, for performing the angiograms; and Dr. Kathleen Meagher-Villemure, Montreal Children's Hospital, for reviewing the histology.

References

1. Aberfeld DC, Rao KR: Familial arteriovenous malformations of the brain. *Neurology* **31**:184-186, 1981
2. Aita JA: **Neurocutaneous Diseases**. Springfield, Ill: Charles C Thomas, 1966, p 85
3. Bean WB: **Vascular Spiders and Related Lesions of the Skin**. Springfield, Ill: Charles C Thomas, 1958, pp 178-185
4. Bebin J, Smith EE: Vascular malformations of the brain, in Smith RR, Haerer AF, Russel WF (eds): **Vascular Malformations and Fistulas of the Brain**. New York: Raven Press, 1982, pp 13-29
5. Berlyne GM, Berlyne N: Anaemia due to "blue-rubber-bleb" naevus disease. *Lancet* **2**:1275-1277, 1960
6. Boyd MC, Steinbock P, Paty DW: Familial arteriovenous malformations. Report of four cases in one family. *J Neurosurg* **62**:597-599, 1985
7. Branch CE Jr, Kunath AM, Buscemi JH: Sublingual venous angioma. Marker of intracranial lesion? *Arch Neurol* **38**: 259-260, 1981
8. Burke EC, Winkelmann RK, Strickland MK: Disseminated hemangiomatosis. The newborn with central nervous system involvement. *Am J Dis Child* **108**:418-424, 1964
9. Cobb S: Haemangioma of the spinal cord. Associated with skin naevi at the same metamere. *Ann Surg* **62**:641-649, 1915
10. Doppman JL, Wirth FP Jr, Di Chiro G, et al: Value of cutaneous angiomas in the arteriographic localization of spinal cord arteriovenous malformations. *N Engl J Med* **281**:1440-1444, 1969
11. Foo D, Chang YC, Rossier AB: Spontaneous cervical epidural hemorrhage, anterior cord syndrome, and familial vascular malformation: case report. *Neurology* **30**:308-311, 1980

12. Holden KR, Alexander F: Diffuse neonatal hemangiomatosis. **Pediatrics** **46**:411–421, 1970
13. Hurst J, Baraitser M: Hereditary neurocutaneous angiomatous malformations: autosomal dominant inheritance in two families. **Clin Genet** **33**:44–48, 1988
14. Jaffé RH: Multiple hemangiomas of the skin and of the internal organs. **Arch Pathol** **7**:44–54, 1929
15. Kaplan HA, Aronson SM, Browder EJ: Vascular malformations of the brain. An anatomical study. **J Neurosurg** **18**:630–635, 1961
16. Kaplan P, Hollenberg RD, Fraser FC: A spinal arteriovenous malformation with hereditary cutaneous hemangiomas. **Am J Dis Child** **130**:1329–1331, 1976
17. Kikuchi K, Kowada M, Sasajima H: Vascular malformations of the brain in hereditary hemorrhagic telangiectasia (Rendu-Osler-Weber disease). **Surg Neurol** **41**:374–380, 1994
18. King CR, Lovrien EW, Reiss J: Central nervous system arteriovenous malformations in multiple generations of a family with hereditary hemorrhagic telangiectasia. **Clin Genet** **12**:372–381, 1977
19. Kisu T, Yamaoka K, Uchida Y, et al: A case of blue rubber bleb nevus syndrome with familial onset. **Gastroenterologia Jpn** **21**:262–266, 1986
20. Leblanc R, Little JR: Hemodynamics of arteriovenous malformations. **Clin Neurosurg** **36**:299–317, 1990
21. Leblanc R, Melanson D, Tampieri D, et al: Familial cerebral aneurysms. A study of 13 families. **Neurosurgery** **37**:633–639, 1995
22. Locksley HB: Natural history of subarachnoid hemorrhage, intracranial aneurysms and arteriovenous malformations, in Sahs AL, Perret GE, Locksley HB, et al (eds): **Intracranial Aneurysms and Subarachnoid Hemorrhage: A Cooperative Study**. Philadelphia: JB Lippincott, 1966, pp 219–239
23. McCormick WF: Pathology of vascular malformations of the brain, in Wilson CB, Stein BM (eds): **Intracranial Arteriovenous Malformations**. Baltimore: Williams & Wilkins, 1984, pp 44–63
24. Munkvad M: Blue rubber bleb nevus syndrome. **Dermatologica** **167**:307–309, 1983
25. Rigamonti D, Hadley MN, Drayer BP, et al: Cerebral cavernous malformations. Incidence and familial occurrence. **N Engl J Med** **319**:343–347, 1988
26. Rosenblum WI, Nakoneczna I, Konerding HS, et al: Multiple vascular malformation in the “blue rubber bleb naevus” syndrome: a case with aneurysm of vein of Galen and vascular lesions suggesting a link to the Weber-Osler-Rendu syndrome. **Histopathology** **2**:301–311, 1987
27. Rubinstein LJ: **Atlas of Tumor Pathology**. Washington, DC: Armed Forces Institute of Pathology, 1970, pp 300–311
28. Russell DS, Rubinstein LJ: **Pathology of Tumours of the Nervous System**, ed 4. London: Edward Arnold, 1977, pp 128–141
29. Satya-Murti S, Navada S, Eames F: Central nervous system involvement in blue-rubber-bleb-nevus syndrome. **Arch Neurol** **43**:1184–1186, 1986
30. Sherry RG, Walker ML, Olds MV: Sinus pericranii and venous angioma in the blue-rubber bleb nevus syndrome. **AJNR** **5**:832–834, 1984
31. Smit LME, Barth PG, Stam FC, et al: Congenital multiple angiomatosis with brain involvement. **Childs Brain** **8**:461–467, 1981
32. Snead OC III, Acker JD, Morawetz R: Familial arteriovenous malformation. **Ann Neurol** **5**:585–587, 1979
33. Talbot S, Wyatt EH: Blue rubber bleb naevi (report of a family in which only males were affected). **Br J Dermatol** **82**:37–39, 1970
34. Théron J, Newton TH, Hoyt WF: Unilateral retinocephalic vascular malformations. **Neuroradiology** **7**:185–196, 1974
35. Walshe MM, Evans CD, Warin RP: Blue rubber bleb naevus. **Br Med J** **2**:931–932, 1966
36. Waybright EA, Selhort JB, Chu F, et al: Sublingual angiomata and the blue rubber-bleb nevus syndrome. **Arch Neurol** **38**:784–785, 1981 (Letter)
37. Waybright EA, Selhorst JB, Rosenblum WI, et al: Blue rubber bleb nevus syndrome with CNS involvement and thrombosis of a vein of Galen malformation. **Ann Neurol** **3**:464–467, 1978
38. Wood MW, White RJ, Kernohan JW: Cavernous hemangiomas involving the brain, spinal cord, heart, skin and kidney. Report of case. **Proc Staff Meet Mayo Clinic** **32**:249–254, 1957
39. Yaşargil MG: **AVM of the Brain, Clinical Considerations, General and Special Operative Techniques, Surgical Results, Nonoperated Cases, Cavernous and Venous Angiomas, Neuroanesthesia**. New York: Thieme, 1988, p 14
40. Yokoyama K, Asano Y, Murakawa T, et al: Familial occurrence of arteriovenous malformation of the brain. **J Neurosurg** **74**:585–589, 1991
41. Zaremba J, Stepién M, Jelowicka M, et al: Hereditary neurocutaneous angioma: a new genetic entity? **J Med Genet** **16**:337–443, 1979

Manuscript received March 8, 1996.

Accepted in final form June 13, 1996.

Address reprint requests to: Richard Leblanc, M.D., Department

Title

of Neurosurgery, Montreal Neurological Institute and Hospital,