

Aneurysm of the Internal Auditory Artery: Our Experience and Review of the Literature

P. Banczerowski, L. Sipos, and J. Vajda

National Institute of Neurosurgery, Budapest, Hungary

Summary

The aneurysms of the internal auditory artery (IAA) situated distal from anterior inferior cerebellar artery (AICA)-IAA junction, are extremely rare lesions. A case of distal aneurysm of IAA is presented causing subarachnoid haemorrhage (SAH) and complete ipsilateral deafness. After the neurosurgical treatment the hearing of the patient definitely improved. The literature of distal aneurysms of AICA is reviewed focusing on the clinical features of these malformations, causing cerebello-pontine angle (CPA) symptoms with or without SAH.

Keywords: Cerebral aneurysm; anterior inferior cerebellar artery; internal auditory artery; subarachnoid haemorrhage; cerebello-pontine angle symptoms.

Introduction

The incidence of aneurysms of the posterior circulation has been reported between 3.3 and 29.5% (average 15%) of all cerebral aneurysms. The distribution of aneurysms in the posterior circulation in percentage is as follows: posterior cerebellar artery (PCA) 14 (7.4–34), basilar artery bifurcation (BAB) 53 (50–66), basilar artery (BA)-superior cerebellar artery (SCA) junction and SCA 8 (5–12), BA trunk 5, vertebral artery (VA), VA-BA junction, posterior inferior cerebellar artery (PICA), PICA-VA junction 20 [5, 36]. The occurrence of aneurysms of anterior inferior cerebellar artery (AICA) is less than 1% [13, 27].

Most of the distal aneurysms of AICA, excluding aneurysms of BA-AICA junction, caused subarachnoid haemorrhage [2, 4, 7, 8, 10, 12, 13–17, 19–21, 23, 25, 26–30, 32–34, 36, 38, Present study], sometimes followed by cerebellar [8], medullary [8] and lower cranial nerve signs [16, 20], with [2, 4, 7, 12, 13, 15, 17, 20, 21, 23, 25, 28, 29, 32–34, 36, Present study] or without [7, 8, 10, 14, 16, 19, 25–27, 30, 38]

syndromes of cerebello-pontine angle lesions, caused 8th [2, 4, 7, 12, 15, 17, 20, 21, 23, 25, 28, 29, 32–34], 7th [2, 4, 7, 12, 13, 15, 17, 20, 21, 25, 29, 32, 34, 36], 5th [7, 21, 32] nerve dysfunction, tinnitus, nystagmus, vertigo, ataxia. In some of the cases pure CPA lesions were mimicked [3, 6, 9, 11, 18, 22, 32, 34, 39]. According to the literature, the localisation of aneurysms causing only CPA syndrome were often able to cause differential diagnostic problems.

An extremely rare case of an IAA aneurysm is presented, which ruptured and caused general SAH and ipsilateral deafness. The clinical appearance is discussed, the neuroradiological pictures and neurosurgical treatment are presented. Data of aneurysms of the distal AICA in the literature are reviewed being the clinical features in focus.

Case Report

A 49-year-old right-handed caucasian woman suffered sudden onset of occipital headache, vertigo, nausea, and vomiting a day prior her admission the National Institute of Neurosurgery, Budapest. She was taken to a local Neurological Department, where lumbar puncture revealed blood in the cerebrospinal fluid and neurological examination revealed nuchal rigidity and deafness on the left side. There was no other focal neurological sign. Computer tomography (CT) demonstrated a moderate subarachnoid haemorrhage along with blood sediment in the 3rd and 4th ventricles and the prepontine cistern (Fig. 1). The second day after the haemorrhage 4-vessel-digital subtraction angiography (DSA) was performed, which showed an 8 mm in diameter saccular aneurysm of the internal auditory artery (IAA), distal to the AICA-IAA junction on the left side and did not seem to penetrate into the internal auditory meatus. The IAA originated from the AICA. The left AICA and the aneurysm was not filled from the ipsilateral vertebral artery and the right external occipital artery originated from the right vertebral artery (Fig. 2 a, b). Pre-operative audiometry revealed a total

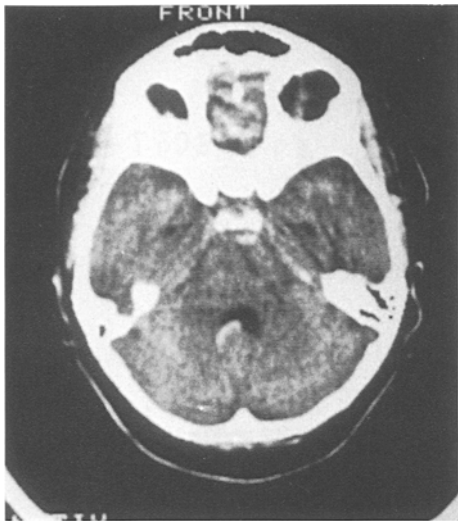

Fig. 1. CT scan shows moderate bleeding in the 4th ventricle and the prepontine cistern

hearing loss on the left and normal hearing on the right side. The patient lying in park-bench position a lateral suboccipital craniotomy was performed on the left side on the eleventh day after the rupture. The cerebellar hemisphere was retracted medially and the postero-lateral surface of the petrous temporal bone and ponto-cerebellar angle were exposed where signs of chronic subarachnoid haemorrhage were seen. Following the dissection of the arachnoid layer the aneurysmal sac and 7th, 8th nerve complex became visible. The proximal segment of the IAA was identified overlying the aneurysm (Fig. 3 a). The distal segment of the IAA was situated between the 7th, 8th nerve complex and the aneurysmal sac. The neck of the aneurysm was found wide and too turgid to be clipped directly because an occlusion of the parent artery was feared. Both proximal and distal portions of IAA were temporarily clipped, the aneurysm was opened and was found to be partially thrombosed. After removing the thrombus the aneurysm was clipped using a 5 mm straight Yasargil clip (Fig. 3 b). The postoperative course was uneventful. An intra-operative opening of the aneurysmal sac proved the secure clipping and made control angiography unnecessary. We performed, however, control audiometry which demonstrated the return of useful hearing in the left ear (Fig. 4). The patient was discharged in good condition on the 8th day following operation.

Discussion

The aneurysms of the peripheral portion of AICA are very rare, but aneurysms of IAA distal from AICA-IAA junction are even more infrequent. Two thousand six hundred patients with intracranial aneurysms (about 3800 aneurysms were clipped) were operated on at the National Institute of Neurosurgery, Budapest since 1977 and there were no aneurysms of IAA except this case. The IAA in most of the cases originates from AICA, sometimes from the SCA, BA, and PICA [37]. Forty cases [2–4, 6–23, 25–30, 32–36,

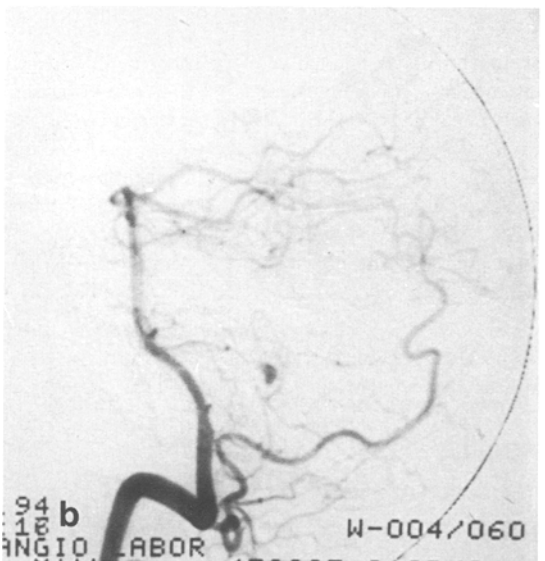
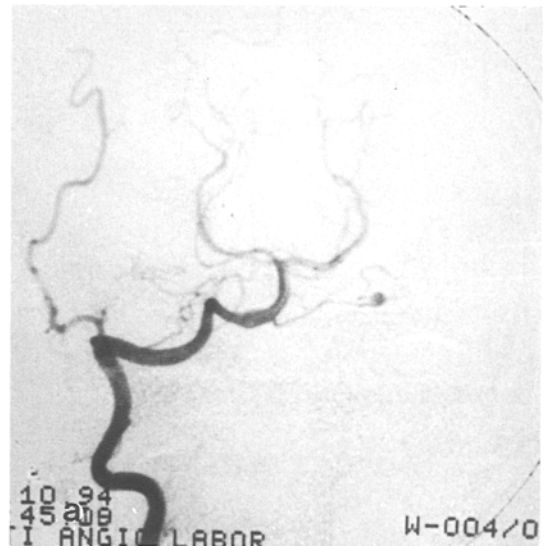


Fig. 2 a, b. Anteroposterior (a) and lateral (b) views of the right vertebral subtraction angiography show a saccular aneurysm of IAA. The right external occipital artery originates from the right vertebral artery

38, 39] of AICA aneurysms have so far been reported since the first publication by Schwartz *et al.* [32] in 1948. Among them 27 female (71%), 11 male (29%) and 3 patients with unknown sex were reported with a female predominance. The mean age of female patients was 45.5, (range 20–72) male patients 45.1 (range 21–60) years.

We grouped the reported cases into five categories according to the clinical onset of distal aneurysms of AICA (Table 1). In most of the cases the initial symptoms were signs of the subarachnoid haemorrhage,

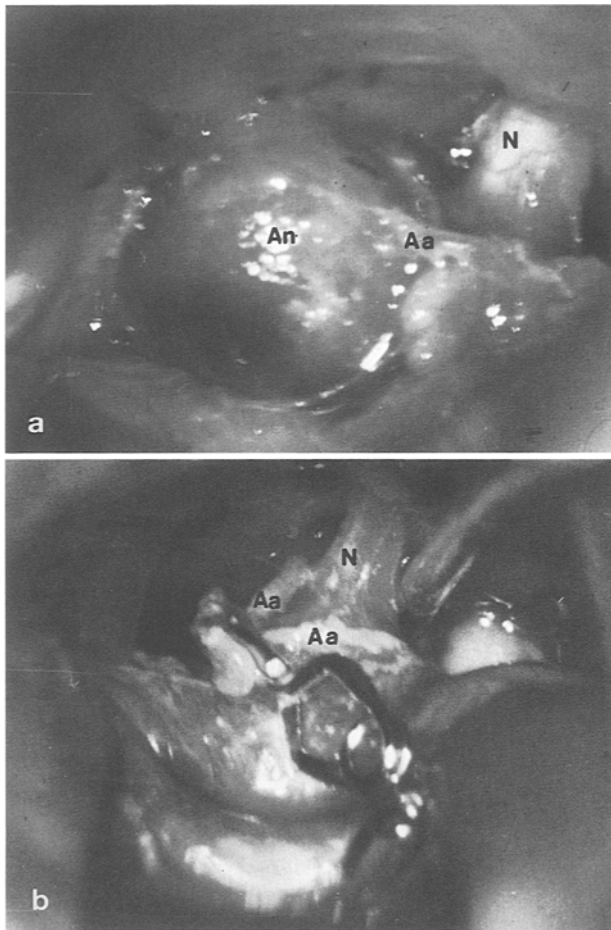


Fig. 3 a, b. Intra-operative photographs show the aneurysm of IAA (a) before and (b) after clipping. An aneurysm, Aa internal auditory artery, N 8th nerve

followed by cerebello-pontine angle symptoms and signs immediately or within a few days. In sixteen cases (39%) symptoms of both SAH and CPA lesions have been reported. Thirteen cases (31.7%) presented with SAH, this was in some cases followed by cerebellar, medullary or lower cranial nerve signs, without signs of CPA lesion. Eight patients (19.5%) had CPA symptoms, which in most of the cases presented differential diagnostic problems. In some cases acoustic neurinoma was suspected pre-operatively, since CT scan demonstrated a contrast enhancing mass [6, 22, 34] at the internal acoustic meatus and/or an erosion of its bony wall [6, 9, 34, 39]. Eight patients had hearing disturbance, 6 (75%) vertigo, 5 (62.5%) tinnitus, another 5 facial palsy, and 3 (37.5%) showed trigeminal nerve involvement. Three (7.3%) cases appeared with initial signs of CPA followed by SAH. In these cases the aneurysms were explored after the

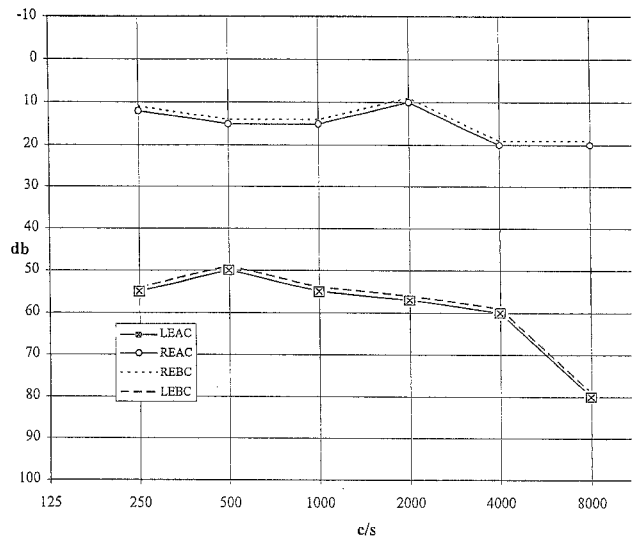


Fig. 4. Postoperative pure tone audiogram. REAC right ear air conduction, REBC right ear bone conduction, LEAC left ear air conduction (masking), LEBC left ear bone conduction (masking)

SAH. Two of them started with signs of facial palsy followed by hypacusis and dizziness, the rest with signs of hearing loss and combined with tinnitus as well as dizziness. One patient (2.4%) could not be fitted into either group.

In twenty-nine (70.7%) cases the presenting sign of the aneurysm was SAH and in those cases there was no doubt about the diagnosis. In 55% of the patients with SAH, where CPA signs developed after the haemorrhage these gave some help in identifying the site of the vascular malformation. In twenty-seven cases (65.8%) CPA symptoms developed with or without SAH (16 cases of SAH + CPA, 8 cases of CPA, 3 cases of CPA + SAH). In three cases (7.3%) the SAH called attention to the aneurysms of AICA after the initial CPA signs.

Most of distal AICA aneurysms originated from the arterial loop near the internal acoustic meatus, frequently caused CPA signs [7, 27]. The cause of 8th and 7th nerve palsies can be ischaemic [7, 24], direct nerve compression [7] or the presence of haemosiderin after SAH within the inner ear [1]. If the aneurysm of the IAA compresses the 7th and/or 8th nerve the sac should be removed in order to achieve a good recovery of the nerve. If pre-operative hearing disturbances appeared haemo-rheological therapy might be useful. According to the literature in 37.5% of the cases hearing loss or disturbances improved significantly following the operation, which was the case with our patient. According to Kiya *et al.* [17] the

Table 1. Summary of Published Cases of Aneurysms of Distal Anterior Inferior Cerebellar Artery

No.	Author (ref. no.)	Age/sex	Initial signs and symptoms	Features
1	Schwartz, 1948 [32]	27/F	Headache, vomiting, hearing loss, ataxia, nystagmus, dizziness, 5th and 7th nerve palsies	SAH + CPA
2	Krayenbühl and Yasargil, 1957 [18]	69/U	Hearing loss, tinnitus, facial palsy, trigeminal neuralgia	CPA
3	Castaigne <i>et al.</i> 1967 [4]	62/F	Facial palsy, headache, vomiting, tinnitus, decrease of hearing, nystagmus, staggering while walking	CPA + SAH
4	Weibel <i>et al.</i> 1967 [36]	61/F	Headache, confusion, facial palsy, convulsion, dysphasia, diplopia	SAH + CPA
5	Hitselberger and Gardner 1968 [11]	U	Hearing loss	CPA
6	Glasscock 1969 [9]	49/M	Hearing loss, dizziness, inappropriate lacrimation	CPA
7	Hori <i>et al.</i> 1971 [12]	35/F	Headache, vomiting, facial palsy, deafness tinnitus, nystagmus	SAH + CPA
8	Malter and Robertson 1971 [20]	41/F	Semicomatose, vomiting, nuchal rigidity, papilloedema, 6th–12th nerve palsies	SAH + CPA
9	Porter and Eyster 1973 [29]	20/F	General malaise, headache, diplopia, hearing loss, vertigo, facial palsy, right sided-hemiparesis	SAH + CPA
10	Benedetti <i>et al.</i> 1975 [2]	49/F	Facial palsy, hypacusis, nausea, headache dizziness, lateropulsion	CPA + SAH
11	Johnson and Kline 1978 [13]	54/M	Headache, nausea, vomiting, tinnitus, facial palsy, nuchal rigidity	SAH + CPA
12	Mori <i>et al.</i> 1978 [22]	48/M	Hearing loss, vertigo, tinnitus, vomiting	CPA
13	Higuchi <i>et al.</i> 1978 [10]	53/M	Headache, nausea, vomiting, tinnitus	SAH
14	Takara <i>et al.</i> 1980 [33]	56/F	Headache, nausea, vomiting, hearing loss, disturbance of consciousness	SAH + CPA
15	Zlotnik <i>et al.</i> 1982 [39]	44/F	Hearing loss, headache, tinnitus, nystagmus, vertigo, trigeminal palsy	CPA
16	Pelliccioli 1982 [28]	U	Hearing loss, dizziness, tinnitus, headache	CPA + SAH
17	Cantore <i>et al.</i> 1982 [3]	35/M	Vertigo, facial paresis, trigeminal neuralgia, hearing loss	CPA
18	Nishimoto <i>et al.</i> 1983 [25]	48/F	Headache, nausea, vomiting, vertigo, tinnitus, nystagmus, decreased hearing, nuchal rigidity	SAH + CPA
		63/F	Headache, nausea, vomiting, vertigo, facial weakness, hypacusis	SAH + CPA
		40/M	Orbital pain, vertigo, tinnitus, diplopia, facial weakness, adiadochokinesis	SAH
20	Gács <i>et al.</i> 1983 [8]	28/F	SAH, diplopia, cerebellar et medullary sy.	SAH
		59/F	Symptoms of SAH, cerebellar signs	SAH
21	Nakagawa <i>et al.</i> 1984 [23]	40/F	Headache, vomiting, vertigo, hearing loss, tinnitus, nystagmus	SAH + CPA
22	Matsubara and Sakakura 1985 [21]	47/F	Headache, vomiting, vertigo, 5th–8th nerve palsies, cerebellar signs	SAH + CPA
23	Dalley <i>et al.</i> 1986 [6]	21/F	Hearing loss, tinnitus, vertigo, facial palsy	CPA
24	Ueki <i>et al.</i> 1986 [35]	54/F	Syndrome of Horner	N
25	Uede <i>et al.</i> 1986 [34]	51/M	Tinnitus, vertigo, deafness	CPA
		42/F	Headache, nausea, vomiting, hearing loss, facial palsy, diplopia, tinnitus	SAH + CPA
26	Kamano <i>et al.</i> 1986 [15]	58/F	Headache, vertigo, facial palsy, nuchal rigidity, deafness	SAH + CPA
27	Nowak <i>et al.</i> 1986 [26]	63/F	Headache, nausea	SAH
28	Fukuya <i>et al.</i> 1987 [7]	60/M	Headache, vertigo, nausea, lost consciousness, nuchal rigidity, nystagmus, bilateral deafness	SAH
		72/F	Headache peripheral facial palsy, hearing loss, trigeminal palsy	SAH + CPA
29	Kaech <i>et al.</i> 1987 [14]	44/M	Symptoms of SAH, drowsy, disorientated	SAH
30	Kiya <i>et al.</i> 1989 [17]	64/F	Headache, vomiting, tinnitus, diplopia, facial palsy, hearing disturbance	SAH + CPA
31	Kamii <i>et al.</i> 1989 [16]	20/F	Disphagia, difficulty of swallowing, headache, vomiting, convulsion, disturbance of consciousness	SAH
32	Kumon <i>et al.</i> 1990 [19]	38/F	Headache, vomiting	SAH
33	Oana <i>et al.</i> 1991 [27]	44/F	Headache, vomiting	SAH
34	Zager <i>et al.</i> 1991 [38]	25/F	Headache, nausea, photophobia, trigeminal palsy, meningismus, diplopia	SAH
35	Pritz 1993 [30]	21/M	Headache, nausea, vomiting, meningismus, photophobia, nuchal rigidity	SAH
		41/M	Headache, nausea, vomiting, meningismus photophobia	SAH
36	Present study, 1994	49/F	Headache, vertigo, nausea, vomiting, nuchal rigidity, deafness	SAH + CPA

SAH subarachnoid haemorrhage, CPA cerebello-pontine angle symptoms, N unclassable, U unknown sex.

paresis of the 7th nerve improved in 69% of the cases, which showed that the function of this nerve is more likely to improve. Although more than 90% of cases of CPA symptoms are caused by neoplasms such as vestibular schwannomas, meningiomas etc., but distal aneurysms of AICA can cause similar symptoms, including enlargement of the internal acoustic meatus. If the CPA signs appear together with symptoms of SAH, the possibility of an aneurysm of the distal AICA is fairly high.

All patients in a satisfactory condition with ruptured supratentorial aneurysms undergo a surgical repair within 48 hours after the bleeding in our code of practice. In cases of Hunt-Hess IV grade we treat the patients conservatively and if the patient improves the operation is delayed until the vasospastic period is over. Due to the improvement of microsurgical techniques even posterior fossa aneurysms should be operated on as soon as possible. According to our experience the rupture of infratentorial aneurysms that are in a wide subarachnoid space (PICA and possibly IAA aneurysms) is less frequently followed by vasospasm. Therefore the aim of surgery in these cases is not so much to remove cisternal blood in the acute stage. We may operate when the patient's clinical condition is stabilized.

Surgical repair of peripheral IAA aneurysms seems straightforward. There is still a lively discussion regarding the position in which the patient should be operated on for any CPA lesion. Although the majority of CPA schwannomas have been explored in the sitting position at our institute, we preferred the park-bench position in this case because a genuine proximal control for the aneurysm was felt more suitable when the cerebellum is almost falling off the petrous bone in the park-bench position. The IAA aneurysm in our case was a real saccular one but there was no branching at its origin, therefore a clippable neck had to be created in a way that is common in cases with giant aneurysms: temporary trapping and relative distal clipping. It was also important to decompress the cranial nerves at the meatus by gentle separation in order to gain functional recovery.

References

1. Arnold W, Vosteen KH (1977) Akute Ertaubung als Folge der Ruptur eines Basilarisaneurysma. *HNO* 25(4): 127–130
2. Benedetti A, Curri D, Carbonin (1975) Aneurysm of the internal auditory artery revealed by a partial cerebellopontine angle syndrome. *Neurochirurgia* 18: 126–130
3. Cantore GP, Ciappetta P, Vagnozzi R, Bozzao L (1982) Giant aneurysm of the anterior inferior cerebellar artery simulating a cerebellopontine angle tumor. *Surg Neurol* 18 (1): 76–78
4. Castaigne P, Pertuiset B, Cambier J, Brunet P (1967) Anévrisme de l'artère auditive interne révélé par une paralysie faciale récidivante, cure radicale. *Press Med* 22: 2493–2496
5. Czepko R (1993) Posterior circulation aneurysms. In: Palmer J (ed) *Neurosurgery*, Vol 93. Newman Thomson, Brighton, pp 62–66
6. Dalley RW, Robertson WD, Nugent RA, Durity FA (1986) Computed tomography of anterior inferior cerebellar artery aneurysm mimicking an acoustic neurinoma. *Comput Assist Tomogr* 10: 881–894
7. Fukuya T, Kishikawa T, Ikeda J, Kudo S, Kuwano H, Matsu-moto S, Fujii K (1987) Aneurysm of the peripheral portion of the anterior inferior cerebellar artery: report of two cases. *Neuroradiology* 29 (5): 493–496
8. Gács Gy, Vinuela F, Fox AJ, Drake CG (1983) Peripheral aneurysms of the cerebellar arteries. Review of 16 cases. *J Neurosurg* 58: 63–68
9. Glasscock SP, Davison C (1969) Middle fossa approach to the temporal bone. *Arch Otolaryngol* 90: 15–27
10. Higuchi H, Yajima K, Nakagawa S (1978) A case of aneurysm of the left internal acoustic meatus. *Neurol Surg* 6: 401–404
11. Hitselberger WE, Gardner G (1968) Other tumors of the cerebellopontine angle. *Arch Otolaryngol* 88: 712–714
12. Hori T, Hirakawa K, Ishijima B, Manaka S, Fukushima T, Shimizu N, Sato T (1971) Aneurysm in the internal auditory meatus. Case report. *J Neurosurg* 35: 605–609
13. Hohnson JH, Kline DJ (1978) Anterior inferior cerebellar artery aneurysms. Case report. *J Neurosurg* 48 (3): 455–460
14. Kacch D, deTribolet N, Lasjaunias P (1987) Anterior inferior cerebellar artery aneurysm, carotid bifurcation aneurysm, and dural arteriovenous malformation of the tentorium in the same patient. *Neurosurgery* 21 (4): 575–582
15. Kamano S, Kirino T, Mizuno S (1986) Intrameatal aneurysm. *Neurochirurgia* 29 (1): 28–30
16. Kamii H, Ogawa A, Sakurai Y, Kayama T (1989) Anterior inferior cerebellar artery aneurysm with a sudden onset of caudal cranial nerve symptoms. *No Shinkei Geka* 17 (4): 387–391
17. Kiya K, Uozumi T, Emoto K, Matsuoka T (1989) Anterior inferior cerebellar artery aneurysm at the internal auditory meatus. Case report. *Neurol Med Chir (Tokyo)* 29: 592–595
18. Kraysenbühl H, Yasargil MG (1957) Die vascularen Erkrankungen im Gebiet der Arteria vertebralis und Arteria basilaris. Thieme, Stuttgart
19. Kumon Y, Sakaki S, Chaki T (1990) Aneurysm of the distal anterior inferior cerebellar artery. Case report. *Jpn J Stroke* 12: 68–73
20. Malter IJ, Robertson EF (1972) Angiographic demonstration of anterior inferior cerebellar artery aneurysm by use of base view. *Radiology* 103 (1): 125–126
21. Matsubara T, Sakakura M (1985) A case of the distal anterior inferior cerebellar artery aneurysm presenting as a cerebellopontine angle tumor. *Mie-Igaku* 29: 323
22. Mori K, Miyazaki H, Ono H (1978) Aneurysm of the anterior inferior cerebellar artery at the internal auditory meatus. *Surg Neurol* 10 (5): 297–300
23. Nakagawa K, Sakaki S, Kimura H, Matsuoka K (1984) Aneurysm of the anterior inferior cerebellar artery at the internal auditory meatus. *Surg Neurol* 21 (3): 231–235

24. Nishida H, Kumagami H, Baba M (1981) Electrocochleographies study of patient with cerebral vascular lesions. *Arch Otolaryngol* 107 (2): 74–78
25. Nishimoto A, Fujimoto S, Tsuchimoto S, Matsumoto Y, Tabuchi K, Higashi T (1983) Anterior inferior cerebellar artery aneurysm. Report of three cases. *J Neurosurg* 59 (4): 697–702
26. Nowak G, Arnold H, Winkler D, Freckmann N (1986) Aneurysm der Arteria auditiva am Porus acusticus internus. *Neurochirurgia* 29 (6): 241–243
27. Oana K, Murakami T, Beppu T, Yamaura A, Kanaya H (1991) Aneurysm of the distal anterior inferior cerebellar artery unrelated to the cerebellopontine angle: case report. *Neurosurgery* 28 (6): 899–903
28. Pelliccioli GP, Floridi P, Luccioli R, Signorini E (1982) Rare malformation of the anterior inferior cerebellar artery. Cerebellar hemisphere angioma and aneurysm of the labyrinthine artery. *Riv Patol Nerv Ment* 103 (2): 57–60
29. Porter RJ, Eyster EF (1973) Aneurysm in the anterior cerebellar artery at the internal acoustic meatus: report of a case. *Surg Neurol* 1 (1): 27–28
30. Pritz MB (1993) Aneurysms of anterior inferior cerebellar artery. *Acta Neurochir (Wien)* 120 (1–2): 12–19
31. Rusegger L, Furtschegger A (1990) Aneurysmen der A. cerebelli inferior anterior. *Nervenarzt* 61: 499–503
32. Schwartz HG (1948) Arterial aneurysm of the posterior fossa. *J Neurosurg* 5: 312–316
33. Takara E, Inoue N, Kohno H (1980) Disappearance of the co-existing aneurysm and arteriovenous malformation after wrapping of aneurysm. *Neurol Surg* 8: 587–591
34. Uede T, Matsumura S, Ohtaki M, Kurokawa Y, Tanabe S, Hashi K (1986) Aneurysm of the anterior inferior cerebellar artery at the internal auditory meatus: report of two cases. *No Shinkei Geka* 14 (10): 1263–1268
35. Ueki K, Morita A, Teraoka A (1986) A case of the anterior inferior cerebellar artery aneurysm. *Clin Neurol* 26: 26
36. Weibel J, Fields WS, Campos RJ (1967) Aneurysms of the posterior cervicocranial circulation. Clinical and angiographic consideration. *J Neurosurg* 26: 223–234
37. Wende S, Nakayama N, Schwerdtfeger P (1975) The internal auditory artery: embryology, anatomy, angiography, pathology. *J Neurol* 210 (1): 21–31
38. Zager E (1991) Isolated trigeminal sensory loss secondary to a distal anterior inferior cerebellar artery aneurysm: case report. *Neurosurgery* 28 (2): 288–291
39. Zlotnik EI, Sklyut JA, Smejanovich AF, Stasenکو EN (1982) Saccular aneurysm of the anterior inferior cerebellar-internal auditory artery. Case report. *J Neurosurgery* 57 (6): 829–832

Comment

The authors report a case of distal anterior inferior cerebellar artery aneurysm at the junction of the internal acoustic artery causing subarachnoid haemorrhage and hearing loss.

The authors mention that peripheral AICA aneurysms are very rare and refer to the literature cited. Although I agree that peripheral AICA aneurysms are rare, they are not as rare as might be suggested. Most case reports referring to peripheral aneurysms in the posterior fossa were written in the 70s and 80s. Today, these aneurysms are a known entity and hardly reported any more.

Because the case is well presented and a thorough review of the literature is included in the manuscript, it is presented to our readers.

H. J. Steiger

Correspondence: Peter Banczerowski, M.D., National Institute of Neurosurgery, Budapest, Amerikai út 57, H-1145 Budapest, Hungary.