

Intraoperative high-dose regional urokinase infusion for cerebrovascular occlusion after carotid endarterectomy

Anthony J. Comerota, MD, FACS, and Augustine R. Eze, MD,
Philadelphia, Pa.

Operative stroke complicating carotid endarterectomy is traditionally treated by reexploration of the operative site to correct a potentially causative lesion; however, attempts are not made to diagnose or treat the intracranial arterial occlusion. A 65-year-old man had a right hemiplegia during a left carotid endarterectomy that was caused by premature reversal of heparin, which resulted in thrombosis of his left anterior cerebral artery. On reexploration, the patient was treated with a 1-hour infusion of 1 million U urokinase through an indwelling carotid shunt. A repeat arteriogram demonstrated patency of the left anterior cerebral artery, with complete clot dissolution and resolution of the right hemiplegia on awakening. Natural history studies of stroke and prospective, angiographically controlled clinical trials of intraarterial thrombolytic therapy for acute stroke support the use of intraoperative intraarterial infusion of urokinase as part of a therapeutic approach to patients who have an ischemic stroke during carotid endarterectomy. (*J Vasc Surg* 1996;24:1008-16.)

Carotid endarterectomy is the most commonly performed vascular operation in the United States. Although neurologic complications are infrequent, their occurrence can be devastating to both patient and surgeon. Operative strokes complicating carotid endarterectomy are reluctantly accepted by surgeons, with treatment directed at reexploration of the operative site to repair a potentially causative lesion in the operative field, most commonly without any attempt to define or correct intracranial ischemia.

In recent years, substantial interest in the use of thrombolytic therapy for acute stroke has yielded data to support the hypothesis that dissolution of symptom-causing thrombi in the cerebral arteries may lead to the resolution of the stroke symptoms.¹

This paper summarizes a patient who had a stroke during carotid endarterectomy as a result of premature heparin reversal. The patient awoke with a dense right hemiplegia caused by acute thrombosis of the

left anterior cerebral artery (ACA). The patient was successfully treated with a high-dose regional infusion of urokinase (UK), which restored patency to the ACA and resolved the right hemiplegia.

CASE REPORT

A 65-year-old Hispanic man sought medical attention with a history of two previous right-hemispheric strokes followed by near full recovery. The patient was referred for evaluation because of recent left-hemispheric transient ischemic attacks and left-eye amaurosis fugax. The patient's physical evaluation was unremarkable except for a harsh left cervical bruit. Carotid artery duplex imaging demonstrated a 40% to 50% stenosis of the right internal carotid artery (ICA) with a small ulcer, and a 70% stenosis of the left ICA associated with marked ulceration. Because of the multiplicity of the patient's symptoms, the previous stroke, and the duplex evidence of contralateral ulceration, a head computed tomographic (CT) scan and a preoperative carotid arteriogram were obtained. A 40% stenosis with a small ulcer of the right ICA was confirmed, as well as the ulcerated stenosis of the left ICA (Fig. 1). Furthermore, both ACAs were patent; however, there was no cross-filling of either ACA as a result of occlusion of the anterior communicating artery (Fig. 2).

A routine left carotid endarterectomy was performed with the patient under general anesthesia with continuous 20-lead electroencephalographic monitoring. The patient was given 7500 U heparin before carotid artery clamping, and the endarterectomy was performed in the standard fashion without a shunt because the electroencephalogram

From the Department of Surgery, Temple University School of Medicine.

Supported in part by NIH grant #1K07 HL02658-01.

Presented at the Tenth Annual Meeting of the Eastern Vascular Society, Washington, D.C., May 3-5, 1996.

Reprint requests: Anthony J. Comerota, MD, FACS, Department of Surgery, Broad and Ontario Streets, Philadelphia, PA 19140.

Copyright © 1996 by The Society for Vascular Surgery and International Society for Cardiovascular Surgery, North American Chapter.

0741-5214/96/\$5.00 + 0 24/6/76659

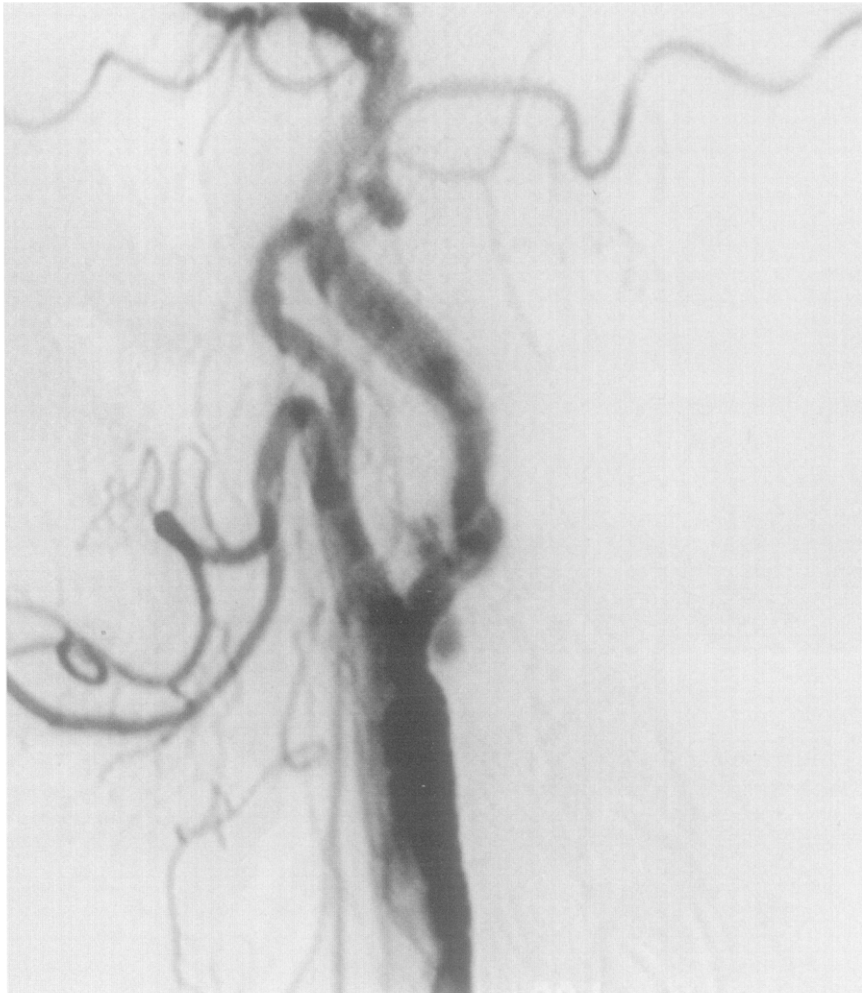

Fig. 1. Carotid arteriogram demonstrates cervical portion of left carotid bifurcation and shows ICA stenosis with multilobulated ulceration.

(EEG) remained normal after carotid artery clamping. Because the ICA was approximately 6 mm in diameter, the arteriotomy was closed primarily. Unfortunately, protamine was infused in a full heparin-reversal dose approximately 15 minutes before the carotid artery clamps were removed.

When the patient awoke from anesthesia on the operating room table, a dense right hemiplegia was present. The patient was reanesthetized, and the incision was reopened. Interestingly, during reexploration when the carotid artery was clamped, the EEG demonstrated significant slowing. A Pruitt-Inahara carotid artery shunt (Ideas for Medicine, Inc., Clearwater, Fla.) was inserted that has a sideport for access to the flow stream. The EEG reverted to baseline after the shunt was placed. The endarterectomized segment was smooth without adherent fibrin or thrombus, and there was no intimal flap. An on-table arteriogram was obtained

through the side arm of the shunt, which demonstrated occlusion of the previously patent left ACA (Fig. 3), which corresponded to the regional slowing of the EEG. One million U UK dissolved in 100 ml of nine-tenths-normal saline solution was slowly infused through the side port during the next hour. A repeat arteriogram (Fig. 4) demonstrated contrast refilling the left ACA. Because the quality of the intraoperative films was suboptimal and because persistent intracerebral thrombus was suspected, a formal carotid and intracranial arteriogram was requested, anticipating that a cerebral microcatheter would be inserted directly into the left ACA if residual thrombus was found. The shunt was removed, and the arteriotomy and neck wounds were closed. Remaining intubated and under general anesthesia, the patient was taken to the neuroradiology suite. Through a right femoral artery approach, the left cervical carotid artery was examined under fluoroscopy and

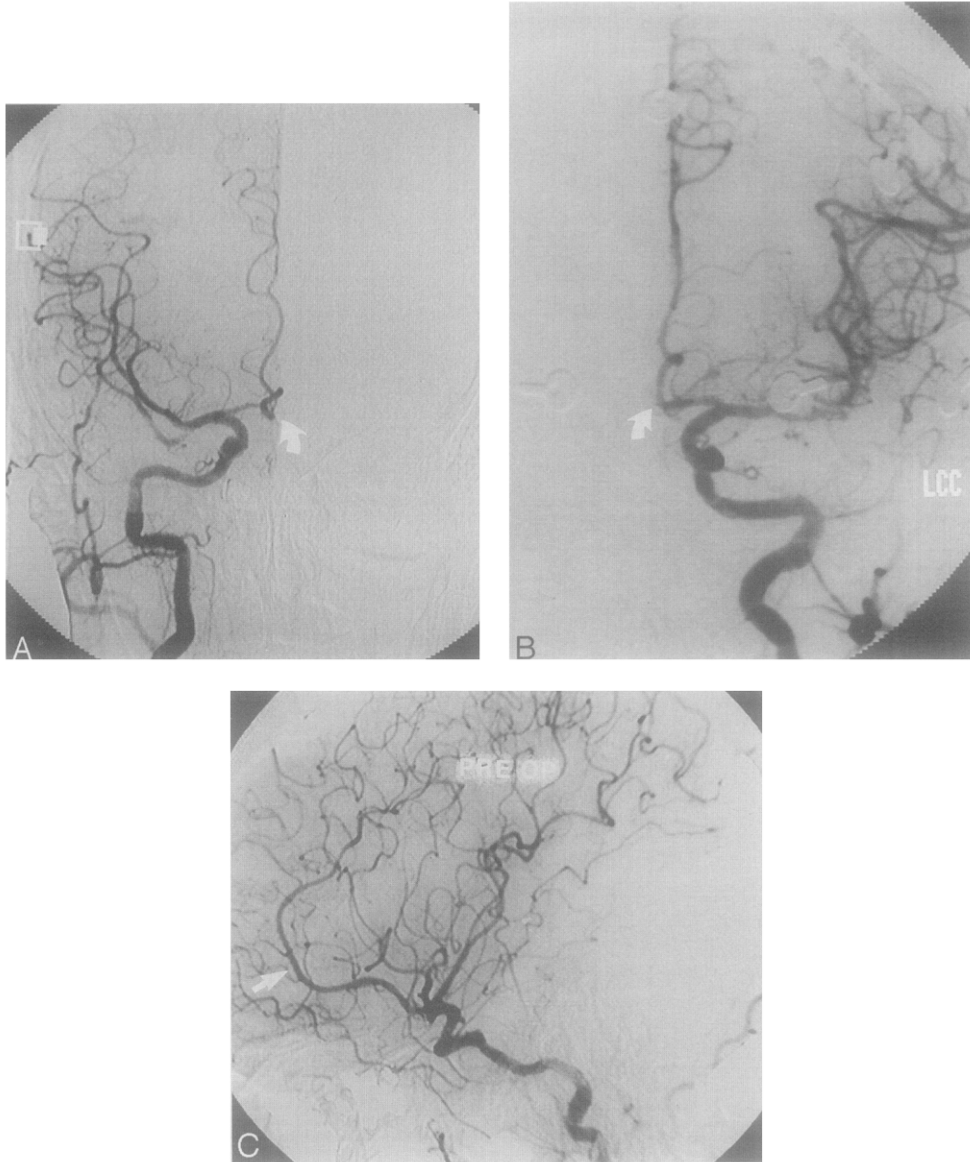


Fig. 2. **A**, Intracranial view of carotid arteriogram demonstrates patent right middle cerebral artery and right ACA; anterior communicating artery is occluded (*arrow*). **B**, Intracranial arteriogram demonstrates patent left middle cerebral artery and left ACA and again indicates occluded anterior communicating artery (*arrow*). **C**, Lateral intracranial arteriogram from left carotid injection demonstrates patent left ACA (*arrow*).

was found to be normal. Intracranial images demonstrated uninterrupted flow of contrast into the left ACA (Fig. 5). The previously thrombosed ACA was now patent, and all visible thrombus had resolved. An immediate CT scan demonstrated no change from the preoperative scan and failed to demonstrate any evidence of hemorrhage. The patient was then transferred to the ICU. When the patient awakened, it was immediately evident that the right hemiplegia had resolved.

During the ensuing 2 days, the patient's response to simple commands was inappropriate and he demonstrated weakness of his left arm. A repeat head CT scan on the third day after surgery demonstrated bilateral nonhemorrhagic infarcts in the region supplied by the posterior cerebral arteries (Fig. 6). In the meantime, the patient's pulmonary status deteriorated and right lower-lobe pneumonia developed, which subsequently cleared with treatment. After resolution of the patient's medical problems, he was trans-

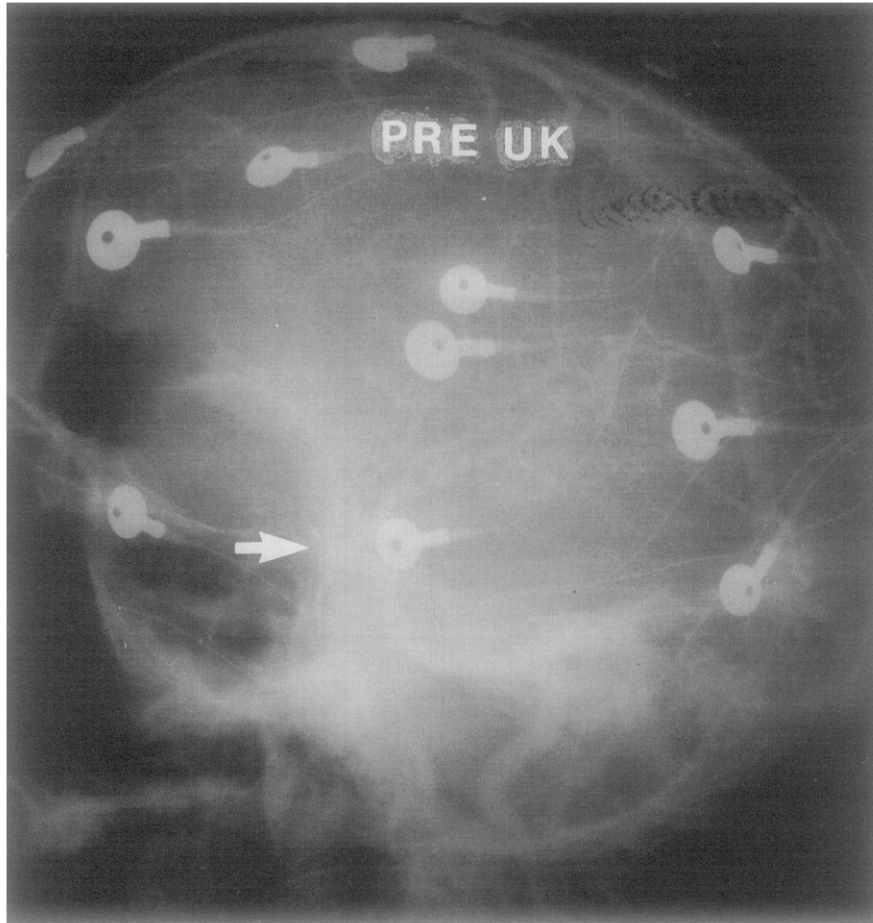


Fig. 3. Initial operative arteriogram through left ICA shunt demonstrates occlusion of left ACA (arrow).

ferred to the rehabilitation unit, where he continued to have good strength and function of the right side of his body and his expressive aphasia and overall neurologic condition improved.

DISCUSSION

Carotid endarterectomy has been proved to be effective in reducing stroke and subsequent neurologic events in patients who have focal hemispheric and retinal ischemia,^{2,3} and in asymptomatic patients who have significant cervical carotid artery disease.^{4,5} The most dreaded complication of carotid endarterectomy is precisely that which the operation is designed to avoid: an ischemic cerebral infarction. Current efforts in the care of patients who have strokes during carotid endarterectomy focus on preventing additional events, but do nothing to diagnose or correct the existing intracranial ischemia. This case

offers a new approach to those patients who have a neurologic deficit during carotid enterectomy. In this particular instance, occlusion of the left ACA likely resulted from in situ thrombosis after the premature reversal of heparin while the carotid artery clamps were in place. Because the anterior communicating artery was occluded, the left ACA represented an "end artery," susceptible to thrombosis if inflow was occluded unprotected by anticoagulation.

When the neurologic deficit was documented, an approach was taken that was designed to correct any cervical lesion and eliminate the intracerebral arterial occlusion that caused the right hemiplegia. In recent years, thrombolytic therapy for acute stroke has received widespread interest. Clinical observations from previous and ongoing studies offer support for the approach taken in our patient.

In patients who had carotid-territory strokes, del

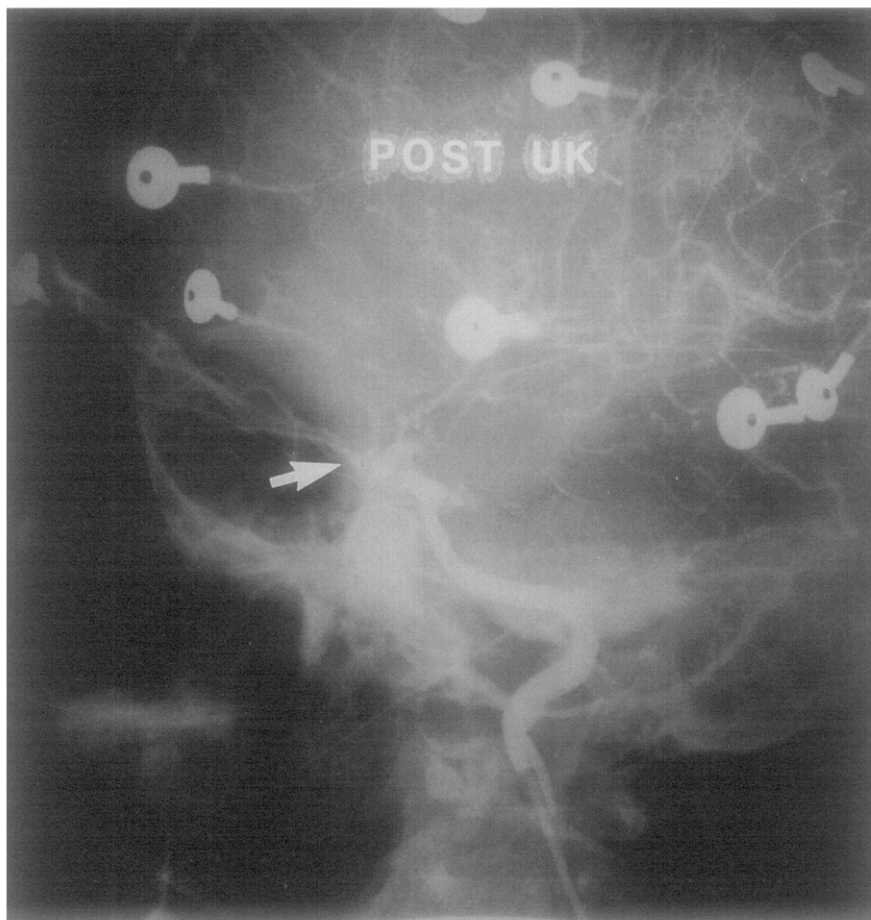


Fig. 4. Repeat operative arteriogram through ICA shunt 1 hour later after infusion of 1 million U UK. There appears to be reperfusion of left ACA (*arrow*).

Zoppo and colleagues⁶ reported either partial or complete recanalization in 90% of patients (18 of 20) who had thrombotic stroke and who were treated with extended local intraarterial or regional infusion of UK plasminogen activator or streptokinase within 1 to 4 hours of symptom onset. Fifty-five percent of patients demonstrated complete or partial clinical recovery; however, no patient recovered in the absence of recanalization. This is a consistent finding in experimental models of stroke^{7,8} and other prospective angiographically controlled trials of thrombolytic therapy for acute stroke.⁹⁻¹¹ Hemorrhagic infarction was seen in 20% of patients, was independent of recanalization, and subsequently resolved in all patients. Similar observations were reported by Mori and colleagues⁹ when they used regional delivery of UK plasminogen activator. These studies typify the observations of other prospective angiographically

controlled studies of intraarterial delivery of thrombolytic agents for carotid-territory stroke.

Hemorrhagic transformation of ischemic brain tissue includes both hemorrhagic infarction and parenchymal hematoma. The prognosis is vastly different between these two entities. Hemorrhagic infarction refers to petechial or confluent petechial hemorrhage in the region of ischemic injury and may represent only a temporary CT or magnetic resonance imaging finding without clinical consequences. Parenchymal hematoma refers to a defined mass of blood in brain tissue that may cause a mass effect or extend into the ventricle. Large natural history studies of carotid-territory stroke have documented that hemorrhagic infarction occurs in 43% to 46% and parenchymal hematoma in 11% to 14%.^{12,13}

Although patient numbers are small, the intensity of the arteriographic investigation in recent prospec-

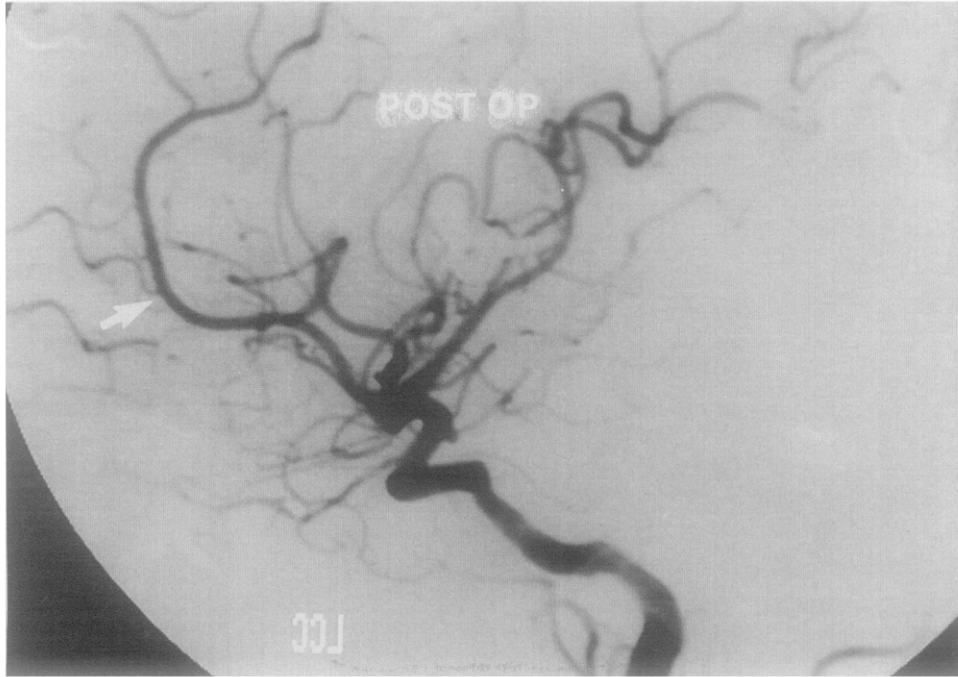


Fig. 5. Intracranial view of formal postoperative left carotid arteriogram demonstrates patent left ACA (*arrow*), without evidence of hemorrhage.

Table I. Rate of recanalization in arteriographically controlled trials of intraarterial thrombolytic therapy for carotid-territory stroke

<i>Author</i>	<i>Agent</i>	<i>n</i>	ΔT	<i>Duration (hr)</i>	<i>Arteriographic recanalization</i>
del Zoppo et al. ⁶	SK/u-PA	20	7.6	1 to 4	90%
Mori et al. ⁹	u-PA	22	4.5	0.2 to 0.5	46%
Matsumoto and Satoh ¹⁰	u-PA	40	1-24	0.2 to 0.5	60%
Theron et al. ¹¹	SK/u-PA	12	2-504	<1.0	100%

ΔT , time from ischemic event to initiation of treatment in hours; *Duration*, duration of lytic infusion in hours; *SK*, streptokinase; *u-PA*, urokinase plasminogen activator.

tive studies offers insight regarding the outcome of treatment. Short-duration delivery of an intraarterial thrombolytic agent early in the course of the cerebral ischemic event is associated with a 46% to 100% chance of recanalization (Table I). In all angiographically controlled studies of ischemic stroke, patient recovery has been directly linked to recanalization (reperfusion) of the occluded artery and is most likely to occur if treatment is instituted soon after the ischemic event. Hemorrhagic transformation increases significantly as the time from onset of ischemia to initiation of treatment increases (particularly if treatment is initiated more than 6 hours from

symptom onset; Table II). Interestingly, there is no relationship between intracerebral hemorrhage and recanalization.

Because operative neurologic deficits can be diagnosed early after the neurologic event occurs, treatment with the regional infusion of the thrombolytic agent to resolve the intracerebral occlusion is appropriate. When treated within the first 4 hours, there is no apparent increased risk of intracranial hemorrhage when compared with nontreated control subjects. The potential for restoring perfusion to the ischemic area, and therefore resolution of the neurologic deficit, is significantly higher in patients who receive

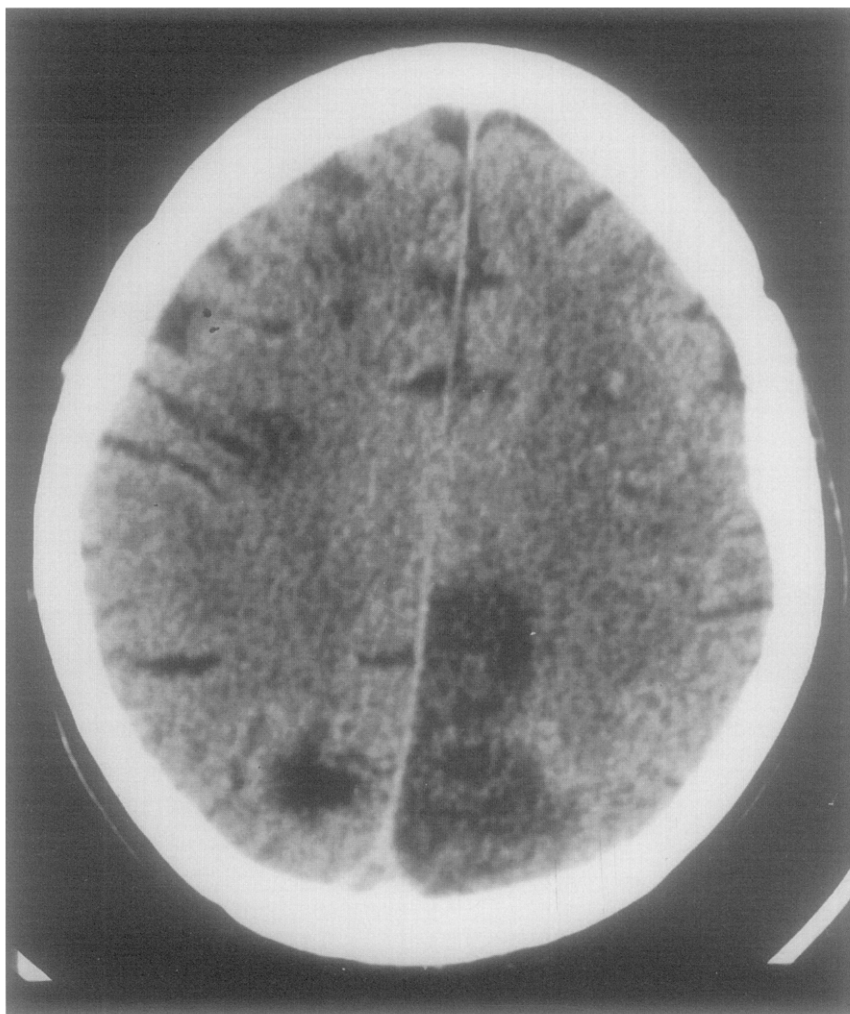


Fig. 6. CT scan 3 days after surgery demonstrates multifocal infarcts; however, there is no evidence of infarction in distribution of ACA, and there is no evidence of intracranial hemorrhage.

Table II. Intracranial bleeding complications of intraarterial thrombolytic therapy for carotid-territory stroke in arteriographically controlled trials

Author	Agent	n	ΔT	Hemorrhage	
				HI	PH
del Zoppo et al. ⁶	SK/u-PA	20	7.6	20%	0%
Mori et al. ⁹	u-PA	22	4.5	4.5%	13.6%
Theron et al. ¹¹	SK/u-PA	12	<10.0	0%	25%

ΔT , time from ischemic event to initiation of treatment in hours; HI, hemorrhagic infarction; PH, parenchymal hematoma; SK, streptokinase; u-PA, urokinase plasminogen activator.

thrombolysis than in untreated patients. We would be unwilling to offer this treatment for occlusions present longer than 6 hours.

Arteriographic imaging of the intracranial vascu-

lature is important. Although the quality of operative arteriograms of the cerebral vasculature is frequently suboptimal, having all available information on these patients is important. The presence of a vascular

occlusion, its relationship to the patient's clinical presentation, and the documentation of the outcome are important for gathering future data. Because neurologic complications after endarterectomy occur infrequently in any single center, an individual vascular surgeon is unlikely to develop an experience broad enough to answer the many important questions that arise when treating these patients. For example, should lytic therapy be withheld if intracranial arterial occlusion is not documented? Is regional infusion into the ICA safer or more effective than local (intrathrombus) infusion? Is there a difference between fibrinolytic agents? Clues to the answers to these questions may be available if a registry is established and the aggregate experience of the multiple centers is analyzed.

Successful use of the intraoperative infusion of UK for embolic stroke during carotid endarterectomy has been reported by Barr et al.¹⁴ They diagnosed a right middle cerebral artery embolic occlusion when the somatosensory evoked potential (right cortical SEP P₅₀ wave) did not recover with carotid artery shunting, and an on-table intracranial carotid arteriogram demonstrated occlusive thrombus in the proximal middle cerebral artery. The thrombus was successfully lysed, with 500,000 U UK delivered into the thrombus through a microcatheter that was appropriately positioned under fluoroscopic guidance. Barr et al. demonstrated the benefit of catheter-directed lysis, and their observations suggest that intracranial arterial occlusion should be suspected if intraoperative abnormalities of SEP or EEG occur that do not normalize after the insertion of a properly functioning carotid artery shunt.

The patient reported herein demonstrated reperfusion of a thrombosed ACA with resolution of a dense hemiplegia after intraoperative high-dose regional infusion of UK. The cause of the patient's other infarcts is uncertain, although they are most consistent with multifocal small-vessel thrombosis that occurs in a similar fashion to the ACA thrombosis.

If reexploration of the operated carotid artery in a patient who had an operative neurologic deficit demonstrated thrombosis of the ICA, we would recommend gentle balloon catheter thrombectomy, operative angiography to examine for adherent thrombus, an intracranial arteriogram, and intraarterial UK infusion through the side port of the carotid artery shunt. Advancing a minicatheter into an occluded intracranial artery (if present) would likely increase the chance of successful lysis.

Intraarterial delivery of UK is commonly used to

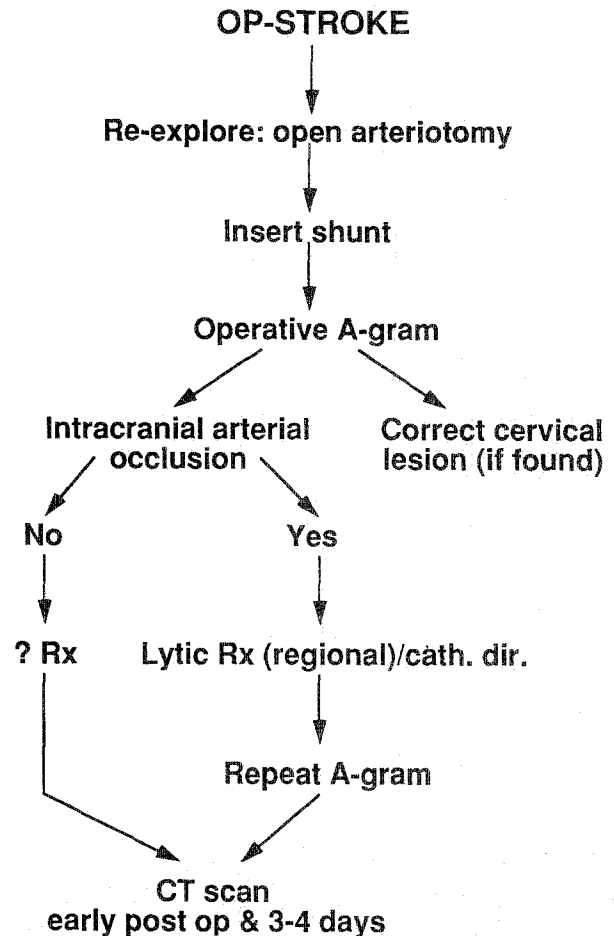


Fig. 7. Suggested approach to patients who have ischemic strokes during carotid endarterectomy.

treat acute arterial and graft occlusion. Although it has not been approved by the Food and Drug Administration for this specific indication, it has become a valuable adjunctive therapy for eliminating thrombus in various parts of the arterial tree. Because the half-life of UK is approximately 14 minutes, the systemic thrombolytic effect should dissipate after 2-3 half-lives. Used judiciously, this form of treatment should not incur any additional medical-legal risk over any other available drug used for a nonapproved indication.

The currently available data from trials of thrombolytic therapy for acute stroke and this case, which documents arteriographic reperfusion of an occluded artery with resolution of a dense hemiplegia after intraoperative UK for an operative stroke, support continued investigation of this therapeutic approach for patients who have intraoperative neurologic deficits during carotid endarterectomy (Fig. 7).

REFERENCES

1. del Zoppo GJ, Otis SM. Thrombolytic therapy for acute stroke. In: Comerota AJ, editor. Thrombolytic therapy for peripheral vascular disease. Philadelphia: J.B. Lippincott, 1995:399-418.
2. North American Symptomatic Carotid Endarterectomy Trial Collaborators. Beneficial effect of carotid endarterectomy in symptomatic patients with high-grade carotid stenosis. N Engl J Med 1991;325:445-53.
3. European Carotid Surgery Trialists' Collaborative Group. MRC European Carotid Surgery Trial: interim results for symptomatic patients with severe (70-99%) or with mild (0-29%) carotid stenosis. Lancet 1991;337:1235-43.
4. Hobson RW, Weiss DG, Fields WS, Goldstone J, Moore WS, Towne JB, et al. Efficacy of carotid endarterectomy for asymptomatic carotid stenosis. N Engl J Med 1993;328:221-7.
5. Executive Committee for the Asymptomatic Carotid Atherosclerosis Study. Endarterectomy for asymptomatic carotid artery stenosis. JAMA 1995;273:1421-8.
6. del Zoppo GJ, Ferbert A, Otis S, Bruckman H, Hacke W, Zyroff J, et al. Local intraarterial fibrinolytic therapy in acute carotid territory stroke: a pilot study. Stroke 1988;19:307-13.
7. Zivin JA, Fisher M, DeGirolami U. Tissue plasminogen activator reduces neurological damage after cerebral embolism. Science 1985;320:1289-92.
8. Zivin JA, Lyden PD, DeGirolami U, Kochhar A, Mazzarella V, Hemenway CC, et al. Tissue plasminogen activator reduction of neurologic damage after experimental embolic stroke. Arch Neurol 1988;45:387-91.
9. Mori E, Tabuchi M, Yoshida T, Yamadori A. Intracarotid urokinase with thromboembolic occlusion of the middle cerebral artery. Stroke 1988;19:802-12.
10. Matsumoto K, Satoh K. Topical intracranial urokinase infusion for acute stroke. In: Hacke W, del Zoppo GJ, Hirshberg M, editors. Thrombolytic therapy in acute stroke. Heidelberg: Springer-Verlag, 1991:207.
11. Theron J, Courteoux P, Casaseo A. Local intraarterial fibrinolysis in the carotid territory. Am J Neuroradiol 1989;10:753-8.
12. Okada Y, Yamaguchi T, Minematsu K, Miyashita T, Sawada T, Sadoshima S, et al. Hemorrhagic transformation in cerebral embolism. Stroke 1989;20:598-603.
13. Horing CR, Dorndorf W, Agnoli AL. Hemorrhagic cerebral infarction: a prospective study. Stroke 1986;17:280-5.
14. Barr JD, Horowitz MB, Mathis JM, Sclabassi RJ, Yonas H. Intraoperative urokinase infusion for embolic stroke during carotid endarterectomy. Neurosurgery 1995;36:606-11.

Submitted May 15, 1996; accepted July 17, 1996.

ON THE MOVE?

Send us your new address at least six weeks ahead

Don't miss a single issue of the journal! To ensure prompt service when you change your address, please photocopy and complete the form below.

Please send your change of address notification at least six weeks before your move to ensure continued service. We regret we cannot guarantee replacement of issues missed due to late notification.

JOURNAL TITLE:

Fill in the title of the journal here. _____

OLD ADDRESS:

Affix the address label from a recent issue of the journal here.

NEW ADDRESS:

Clearly print your new address here.

Name _____

Address _____

City/State/ZIP _____

COPY AND MAIL THIS FORM TO:

Journal Subscription Services
Mosby-Year Book, Inc.
11830 Westline Industrial Dr.
St. Louis, MO 63146-3318

OR FAX TO:

314-432-1158

OR PHONE:

1-800-453-4351
Outside the U.S., call
314-453-4351

