

Multiple brain gas embolism after ingestion of concentrated hydrogen peroxide

Article abstract—We present a 63-year-old man who developed multiple brain infarction after ingesting a 35% hydrogen peroxide solution. Neurologic examination revealed left hemiparesis, primarily affecting the lower limb, and mild weakness of the right lower limb. Gadolinium-enhanced MRI revealed patchy bilateral brain lesions. Oxygen gas embolization is the likely cause of the brain infarctions.

NEUROLOGY 1997;48:277-279

T. Ijichi, MD; T. Itoh, MD; R. Sakai, MD; K. Nakaji, MD; T. Miyauchi, MD; R. Takahashi, MD; S. Kadosaka, MD; M. Hirata, MD; S. Yoneda, MD; Y. Kajita, MD; and Y. Fujita, MD

Concentrated hydrogen peroxide solution, an industrial bleaching or oxidizing agent, is a clear and odorless ubiquitous liquid used in many industries. Accidental exposures to the solution sometimes occur. Because the main route of exposure is ingestion,¹⁻⁵ gastrointestinal tract involvement is the most common complication.⁵ Although there have been reports of brain involvement,^{1,3,6} only one case report has documented neuroimaging findings.⁶ We report a patient who developed multiple brain infarction with unusual MRI findings after ingestion of concentrated hydrogen peroxide.

Case report. A 63-year-old left-handed man was working in a brewery as a seasonal laborer when he unintentionally ingested three cups of 35% hydrogen peroxide (approximately 120 ml) stored in a Japanese rice wine bottle in the factory kitchen. His past medical history was notable only for partial gastrectomy for gastric ulcer at the age of 57 years.

Soon after the ingestion, the patient vomited three times and complained of general malaise and was taken to our emergency room. He arrived approximately 45 minutes after the ingestion. On presentation, the patient's consciousness level was decreased (Glasgow Coma Scale score of 5). Vital signs were as follows: blood pressure 164/112 mm Hg, pulse 100/min, respiratory rate 18 breaths/min, and body temperature 36.0° C. Subcutaneous emphysema was not noted. The patient's lungs were clear and heart sounds were normal; the abdomen was slightly distended. Complete neurologic examination could not be performed because of the patient's decreased level of consciousness. Routine blood test results were normal except for a slight increase in the serum glucose and liver enzyme concentrations. Arterial blood gas analysis showed pH 7.463, PCO₂ 39.0 Torr, and PO₂ 69.6 Torr.

Radiographs of the abdomen and chest revealed a crescent-shaped region of air under the left diaphragm, suggesting intra-abdominal free air (figure 1). Preoperative esophagogastroduodenoscopy 1 hour later showed diffuse hemorrhage of the gastric mucosa. The esophagus and duodenum appeared normal. At laparotomy 5 hours after the ingestion, severe erythema, edema, and emphysema of the gastric serosa were noted; however, a visible perforation was not detected.

The patient's level of consciousness gradually improved. On the fifth hospital day, the patient became alert and complained of numbness of the extremities. Neurologic examination demonstrated a left hemiparesis predominantly

affecting the lower limb while sparing the face and a mild weakness of right lower limb. A left Babinski sign was present. Unenhanced axial brain MRI on the tenth hospital day showed patchy areas of low intensity on T₁-weighted images and high intensity on T₂-weighted images, mainly in the gray matter of the frontal and parietal lobes bilaterally. Five days later, a coronal MRI with gadolinium demonstrated multiple enhancing lesions in the premotor, motor, and sensory cortices bilaterally (figure 2, A through C). Although the abdominal symptoms had rapidly improved, recovery from the neurologic deficits was only partial. Four weeks later, follow-up MRI revealed that the gadolinium-enhancing lesion had almost disappeared (figure 2, D through F). The T₁-weighted images showed low intensity in some areas previously enhancing.

Discussion. There are multiple reports of oxygen embolization associated with the use of dilute hydrogen peroxide to irrigate tissues during surgery,⁷⁻⁹ but ingestion of the dilute form is usually benign. Ingestion of industrial-strength hydrogen peroxide can cause venous or arterial oxygen embolization.^{1,3,4,6} Giberson et al.¹ reported a case of embolic brain injury in an adult woman who ingested an unknown volume of 35% hydrogen peroxide. Christensen et al.³ described portal venous and possible cerebral venous oxygen embolization in a 2-year-old boy who ingested 4 to 6 ounces of 35% hydrogen peroxide. They showed a chest radiograph demonstrating gas in the portal venous system and documented marked diffuse cerebral edema with cerebellar and uncal tonsillar notching on autopsy, suggesting the presence of severe brain venous oxygen embolism. Sherman et al.⁶ reported a case of multiple brain infarction documented by neuroimaging in an elderly man who had ingested 30 ml of 35% hydrogen peroxide. Brain MRI in this patient showed the characteristic distribution of lesions consistent with brain gas embolism.

The clinical signs in our patient were consistent with bihemispheric brain infarction. The patchy distribution of the brain infarction and the predominance of lesions in the gray matter with relatively sparing of the white matter as shown by T₁- and T₂-weighted MRI of our patient is consistent with brain arterial gas embolism.¹⁰ Moreover, the presence of enhancing lesions on brain MRI on the 15th hospital day and the resolution of the enhancement on subsequent MRI suggest that these lesions were

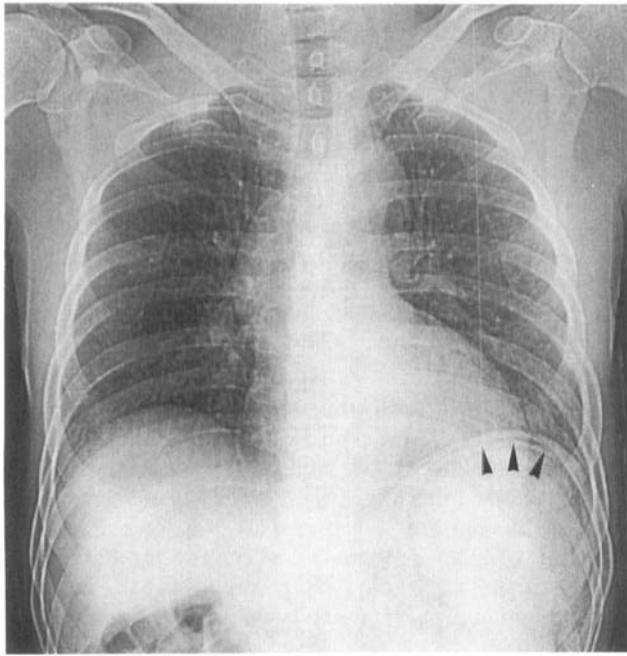


Figure 1. Chest radiograph demonstrating a crescent-shaped region of gas under the left diaphragm (arrowheads).

subacute. The distribution of the lesions favoring parasagittal areas is well correlated with the predominant lower limb paresis. Thus, we propose that the multiple foci of brain infarction in our patient were due to oxygen gas embolization after ingestion of concentrated hydrogen peroxide solution. This may be the first report demonstrating gadolinium-enhancing MRI lesions produced by brain gas embolism.

One hundred twenty milliliters of 35% hydrogen peroxide can release about 14 liters of oxygen gas on contact with organic tissue in the presence of catalase.² Although our patient vomited soon after the ingestion, a sufficient amount of hydrogen peroxide could have entered into the blood vessels through the

erosive stomach mucosa as noted during esophago-gastroduodenoscopy. We speculate that a substantial amount of hydrogen peroxide was catalyzed in the blood vessels or the tissue as evidenced by the presence of subdiaphragmatic air and subserosal emphysema without visible perforation during laparotomy.

Previous reports proposed at least three mechanisms of oxygen gas embolization due to hydrogen peroxide. First, oxygen bubbles are formed in or brought into right atrium or ventricle by way of the portal system.³ These bubbles may move to left atrium through a patent foramen ovale, causing arterial oxygen gas embolization. Second, pulmonary aspiration of hydrogen peroxide can cause direct arterial oxygen gas embolization.⁶ Third, undissociated hydrogen peroxide absorbed in the gastrointestinal system may catalyze in the arterial circulation after crossing the lung, causing arterial oxygen gas embolization.⁶ In our patient, the last mechanism seems the most plausible, because he did not develop circulatory or respiratory failure during his clinical course.

Although there have been no reports concerning hyperbaric therapy for the treatment of brain oxygen gas embolism caused by hydrogen peroxide, theoretically it should decrease the bubble size as suggested by some authors.^{4,6} Armon et al.¹⁰ emphasized that this therapy is effective for brain air embolism complicating cardiac surgery even if administered during the subacute phase. In addition to hyperbaric therapy, vasodilators, such as prostaglandin E₁ analogues, may be beneficial to remove oxygen bubbles in arterioles.

Our case re-emphasizes the hazard of concentrated hydrogen peroxide solution and suggests that physicians should be alert to the possibility of CNS involvement in patients after ingestion. As suggested by previous reports,^{3,5} the accident of our patient could have been avoided if the solution was stored appropriately. Therefore, we further recommend that concentrated hydrogen peroxide solution should have

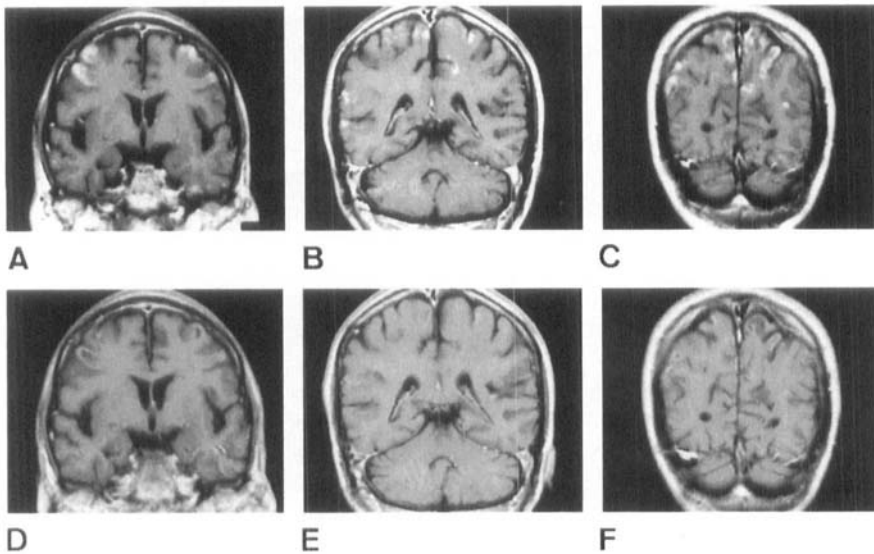


Figure 2. Gadolinium-enhanced brain MRI on the 15th hospital day showing enhancing lesions involving premotor (A), motor (B), and sensory cortices (C). Involvement of the premotor and motor cortex is more severe on the right side. The white matter is relatively spared. On follow-up MRI on the 43rd hospital day, the enhancement appears almost resolved (D-F).

a distinct color or odor if possible and should be labeled and stored as a toxic agent.

From the Division of Neurology (Dr. Ijichi), Department of Surgery (Drs. Itoh, Nakaji, and Miyauchi), and Department of Internal Medicine (Drs. Sakai, Takahashi, Kadosaka, Hirata, Yoneda, Kajita, and Fujita), Nantan General Hospital, Funai-gun, Kyoto, Japan.

Received March 28, 1996. Accepted in final form May 22, 1996.

Address correspondence and reprint requests to Dr. T. Ijichi, Division of Neurology, Nantan General Hospital, Yagi-cho, Funai-gun, Kyoto 629-01, Japan.

References

1. Giberson TP, Kern JD, Pettigrew DW III, Eaves CC, Haynes JF Jr. Near-fatal hydrogen peroxide ingestion. *Ann Emerg Med* 1989;18:778-779.
2. Humberston CL, Dean BS, Krenzelok EP. Ingestion of 35% hydrogen peroxide. *Clin Toxicol* 1990;28:95-100.
3. Christensen DW, Faught WE, Black RE, Woodward GA, Tim-

- mons OD. Fatal oxygen embolization after hydrogen peroxide ingestion. *Crit Care Med* 1992;20:543-544.
4. Luu TA, Kelley MT, Strauch JA, Avradopoulos K. Portal vein gas embolism from hydrogen peroxide ingestion. *Ann Emerg Med* 1992;21:1391-1393.
5. Dickson KF, Martin Caravati E. Hydrogen peroxide exposure—325 exposures reported to a regional poison control center. *Clin Toxicol* 1994;32:705-714.
6. Sherman SJ, Boyer LV, Sibley WA. Cerebral infarction immediately after ingestion of hydrogen peroxide solution. *Stroke* 1994;25:1065-1067.
7. Shaw A, Cooperman A, Fusco J. Gas embolism produced by hydrogen peroxide. *N Engl J Med* 1967;277:238-241.
8. Basson MM, Dudai M, Shalev O. Near-fatal systemic oxygen embolism due to wound irrigation with hydrogen peroxide. *Postgrad Med J* 1982;58:448-450.
9. Morikawa H, Mima H, Fujita H, Mishima S. Oxygen embolism due to hydrogen peroxide irrigation during cervical spinal surgery. *Can J Anaesth* 1995;42:231-233.
10. Armon C, Deschamps C, Adkinson C, Fealey RD, Orszulak TA. Hyperbaric treatment of cerebral air embolism sustained during an open-heart surgical procedure. *Mayo Clin Proc* 1991;66:565-571.

Unusual MRI and pathologic findings of progressive multifocal leukoencephalopathy complicating adult Wiskott-Aldrich syndrome

Article abstract—We present a long-surviving patient with Wiskott-Aldrich syndrome complicated by atypical progressive multifocal leukoencephalopathy (PML). MRI showed multiple tiny spots of Gd-DTPA-enhanced lesions on the T₁-weighted image. Pathologic findings for brain biopsy were patchy demyelinated vascularized lesions infiltrated by a surprising number of eosinophils. The presence of polyomavirus JC was confirmed by in situ hybridization and polymerase chain reaction. PML should be included in the differential diagnosis when Gd-DTPA-enhanced spotty lesions are present in the white matter, especially in patients who have a mild immunologic defect.

NEUROLOGY 1997;48:279-282

T. Matsushima, MD; K. Nakamura, MD; T. Oka, MD; N. Tachikawa, MD; T. Sata, MD; S. Murayama, MD; N. Nukina, MD; and I. Kanazawa, MD

Wiskott-Aldrich syndrome (WAS) is an X-linked recessive combined immune deficiency that manifests the triad of thrombocytopenia, eczema, and recurrent infection. Several reports have described patients with variant forms of WAS, with milder clinical features of bleeding and infection. Patients survived into adulthood; however, it is very rare for patients to survive longer than 10 years.¹

In contrast, progressive multifocal leukoencephalopathy (PML) is typically a rapidly progressive degenerative disease, resulting from CNS infection by polyomavirus JC (JC virus). This infection results in continued neurologic decline, mostly in immunocompromised hosts, and is usually relentlessly progressive with death within 9 months of the onset of symptoms. Typical MRI features of PML involve multiple asymmetrical lesions, predominantly in the white matter, without mass effect or enhancement.² We present a patient with WAS who has survived more than 35 years and then developed PML. Unusual MRI and pathologic findings are discussed.

Case report. A 36-year-old man was hospitalized because of slowly progressive dementia that included anomia, alexia, and agraphia. He had a history of idiopathic thrombocytopenic purpura at the age of 1 month, atopic dermatitis at 1 year, and pulmonary tuberculosis at age 20. At age 34, 2 years before admission, a sudden epileptic attack occurred, and treatment with antiepileptic drugs was begun. Thereafter, his mental symptoms gradually worsened. In January 1994, he was hospitalized for a complete medical examination.

His family history disclosed that a maternal uncle had a bleeding tendency combined with an immunodeficiency and died of malignant lymphoma at age 31. A granddaughter of this uncle also showed thrombocytopenia. This family history strongly suggests a disease of X-linked recessive inheritance. On physical examination, erythema with teleangiectasia on the face and eczema over the entire body were noted. Neurologic and neuropsychological examinations revealed mild anomia, aphasia with phonemic paraphasia, alexia, and agraphia. He showed slight right hemiparesis. Deep tendon reflexes, however, were reduced in

Neurology[®]

Multiple Brain Gas Embolism After Ingestion of Concentrated Hydrogen Peroxide

T. Ijichi, T. Itoh, R. Sakai, et al.

Neurology 1997;48;277-279

DOI 10.1212/WNL.48.1.277

This information is current as of January 1, 1997

Updated Information & Services	including high resolution figures, can be found at: http://www.neurology.org/content/48/1/277.full.html
References	This article cites 10 articles, 1 of which you can access for free at: http://www.neurology.org/content/48/1/277.full.html##ref-list-1
Citations	This article has been cited by 3 HighWire-hosted articles: http://www.neurology.org/content/48/1/277.full.html##otherarticles
Permissions & Licensing	Information about reproducing this article in parts (figures, tables) or in its entirety can be found online at: http://www.neurology.org/misc/about.xhtml#permissions
Reprints	Information about ordering reprints can be found online: http://www.neurology.org/misc/addir.xhtml#reprintsus

Neurology® is the official journal of the American Academy of Neurology. Published continuously since 1951, it is now a weekly with 48 issues per year. Copyright Copyright 1997 by Advanstar Communications Inc.. All rights reserved. Print ISSN: 0028-3878. Online ISSN: 1526-632X.

