

Simultaneous Bilateral Thalamic Hemorrhages Following the Administration of Intravenous Tissue Plasminogen Activator

Alexander W. Dromerick MD, James F. Meschia, MD, Ashok Kumar MD, Robert E. Hanlon, PhD

ABSTRACT. Dromerick AW, Meschia JF, Kumar A, Hanlon RE. Simultaneous bilateral thalamic hemorrhages following the administration of intravenous tissue plasminogen activator. *Arch Phys Med Rehabil* 1997;78:92-4.

A patient suffered the onset of simultaneous bilateral thalamic hemorrhage several hours after the administration of intravenous tissue plasminogen activator. The patient exhibited features of the paramedian diencephalic syndrome, including executive dysfunction, anterograde amnesia, inattention, and disturbances of visual perception. During rehabilitation, she made significant gains in overlearned activities of daily living tasks, but her inability to retain new information left her severely disabled. The use of intravenous thrombolytic therapy is believed to account for this patient's unusual stroke syndrome. With recent evidence supporting the efficacy of intravenous thrombolysis in acute stroke, patients with multiple hemorrhagic strokes as a result of thrombolysis may become more common on rehabilitation services.

© 1997 by the American Congress of Rehabilitation Medicine and the American Academy of Physical Medicine and Rehabilitation

A RECENT REPORT of the efficacy of intravenous tissue plasminogen activator (IV t-PA) in the treatment of acute stroke¹ will likely lead to the admission of many t-PA recipients to stroke rehabilitation centers. We report the neurological and functional outcome of a patient who sustained bilateral simultaneous thalamic hemorrhages following IV t-PA therapy for myocardial infarction. We believe this unusual case raises several important rehabilitation issues and that it also provides an opportunity to review the complications of IV t-PA therapy.

CASE REPORT

A 73-year-old woman presented to an outside hospital with chest pain and dyspnea, demonstrating electrocardiographic evidence of acute myocardial infarction. The patient was intubated, mechanically ventilated, and received 100mg of IV t-PA over 3 hours. She extubated herself the same day. Within 24 hours she became stuporous but arousable to pain. She moaned spontaneously, showed downward deviation of her eyes, and exhibited flexion posturing to pain. She had mild right hemiparesis, and plantar responses were extensor bilaterally. Computed tomography (CT) showed bilateral acute thalamic hemorrhages. CT on the second hospital day (fig 1) showed interval enlargement of the left hemorrhage but no hydrocephalus. The patient

gradually improved and was transferred to the stroke rehabilitation service on the 13th hospital day. Repeat noncontrast CT of the head showed isodense thalamic lesions and no new lesions.

The patient had previously lived alone and had been independent in basic and instrumental activities of daily living (ADL). On admission, she was awake and attended to voice for less than 60 seconds. Eye contact was poor. She was oriented to self only. Spontaneous speech was fluent and articulate, but perseverative. She had severe dysnomia, characterized by semantic substitutions and perceptual errors. She registered 4/5 objects, but recalled 0/5 at 1 minute. Overall, she demonstrated severe global anterograde amnesia and retrograde memory loss, with extensive confabulation. Cranial nerve examination revealed right gaze preference. Eye movements including convergence were intact, and the pupillary examination was unremarkable. Muscle strength, bulk, and tone were normal, but she demonstrated severe motor impersistence and ideomotor apraxia. She withdrew to noxious stimuli in all extremities. Myotatic reflexes were +1 and symmetric, and plantar responses were flexor. She stood and walked with a flexed posture.

Multidisciplinary rehabilitation, including speech, physical, and occupational therapy, was initiated emphasizing cognitive retraining, basic ADL, mobility, balance and gait training. She achieved a total Functional Independence Measure² (FIM) score of 24/126 at that time. Her inpatient course was characterized by improvement in self-care and mobility; however, she showed minimal cognitive improvement. On the Mini-Mental State Examination, she achieved scores of 6, 11, 9, and 8 on posthemorrhagic days 19, 32, 33, and 40, respectively. Her most refractory deficits were marked inattention, severe memory impairment, and perseveration. During a 35-day course of inpatient rehabilitation she gained 25 FIM points, resulting in a total FIM score of 49/126. She was discharged to an extended care facility and ultimately returned home to her family.

At 6 months after discharge from rehabilitation, she showed mild improvement in attention, orientation, comprehension, and the ability to follow commands. Memory remained markedly defective, compounded by impulsivity and perseveration. Standing balance was poor and ambulation was limited to a few short steps in a flexed, stooped posture. Total FIM score at 7 months after onset was 54/126.

A neuropsychological evaluation at 9 months after onset revealed extensive cognitive impairment, with notable sparing of specific cognitive functions. Spontaneous speech was fluent and articulate, but dysnomic. Auditory comprehension was relatively well preserved. Basic attentional functions, including auditory span of apprehension, were also within normal limits. She continued to manifest severe global anterograde amnesia, in addition to moderate retrograde memory loss. Conversely, procedural learning of movement sequences was comparatively well preserved. She revealed ongoing visuoperceptive disturbance, compounded by mild left spatial inattention. Behaviorally, she manifested motor impersistence and perseverative tendencies. In summary, she revealed severe bihemispheric cognitive deficits, but demonstrated remarkable sparing of basic language and attentional functions, as well as a preserved capacity for motor learning (table 1).

From the Stroke Rehabilitation Service, Division of Rehabilitation, Washington University School of Medicine, St. Louis, MO.

Submitted for publication February 26, 1996. Accepted in revised form April 8, 1996.

No commercial party having a direct financial interest in the results of the research supporting this article has or will confer a benefit upon the authors or upon any organization with which the authors are associated.

Reprint requests to Alexander Dromerick MD, Campus Box 8111, Department of Neurology, 660 S. Euclid Ave, St. Louis, MO 63110.

© 1997 by the American Congress of Rehabilitation Medicine and the American Academy of Physical Medicine and Rehabilitation
0003-9993/97/7801-3913\$3.00/0

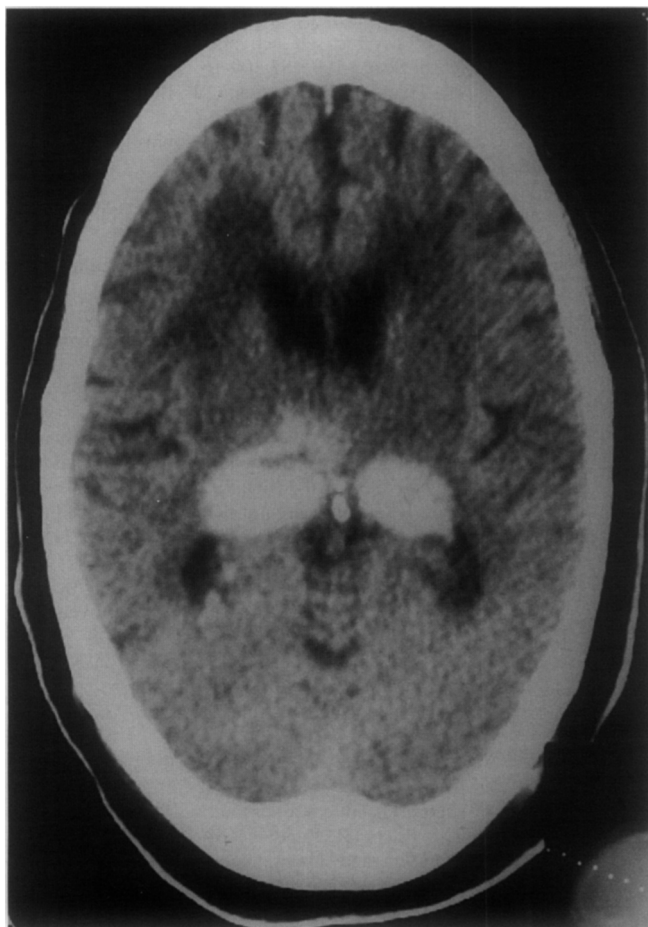


Fig 1. Noncontrast CT of the brain, hospital day 2.

DISCUSSION

We report this case for two reasons. First, it demonstrates an extremely unusual and purely cognitive stroke syndrome which will be encountered occasionally on a busy rehabilitation service. Patients with this syndrome are profoundly disabled, yet their neurological impairments may easily be diagnosed incorrectly or missed entirely by an unwary physician. Second, this case illustrates a neurological complication of intravenous thrombolysis, a treatment commonly administered to patients who eventually undergo cardiac, stroke, or subacute level rehabilitation. With the recent report of the efficacy of IV t-PA in acute stroke,¹ patients with such complications will become more frequent on the rehabilitation ward.

This patient's primary impairment involved severe cognitive dysfunction consistent with bilateral diencephalic involvement. In addition to inattention, visuoperceptual disturbance, and executive dysfunction, she manifested dense anterograde amnesia with moderate retrograde memory loss. Her inability to retain new information made rehabilitation difficult. However, preservation of procedural learning in functional tasks involving movement sequences and object manipulation enabled her to make notable gains in overlearned tasks such as feeding, grooming, and walking.

Our patient exhibited many of the features of the paramedian diencephalic syndrome (PDS).³⁻⁶ This syndrome is characterized by acute stupor or coma lasting several days followed by hypersomnolence, amnesia, apathy, and vertical gaze palsy. It appears that bilateral lesions are required to generate the syndrome, and

disruption of bilateral mammillothalamic and ventroamygdalofugal pathways has been proposed as the cause of amnesia in these patients. Most commonly, this syndrome occurs after two separate ischemic infarcts, one involving each thalamus. There have been reports of simultaneous bilateral paramedian infarcts that were not hemorrhagic; most were attributed to an anatomic variant in which both paramedian thalamic arteries arise from a single basilar communicating artery.^{7,8} A single case does not allow us to comment on the rehabilitation "potential" in this syndrome. Rehabilitation strategies that are effective in amnesia from head trauma or hypoxia were tried in this patient but were unsuccessful because of the severity and persistence of her amnesia and abulia. Pharmacological options were limited by her medical comorbidities. Other patients may do better; the anatomic and vascular complexity of the thalamus and posterior circulation allows great variability in presentation, severity, and outcome.⁹ Two patients with PDS were reported to have eventually returned to work, and one of these patients was thought by his wife to have returned to normal. Another patient was apparently recovered to be independent in basic ADL.^{7,8}

We believe that the use of an intravenous thrombolytic agent accounts for this unusual hemorrhagic event in our patient. Bleeding is by far the most common complication of thrombolysis, and t-PA therapy for myocardial infarction confers an overall cerebral hemorrhage rate of about 0.6%.^{5,10-12} For patients treated with thrombolytics for stroke, rates of cerebral hemorrhage are much higher, from 6% to 40%.^{1,13,14} Proposed risk factors include age greater than 65 years, hypertension, and aspirin use. As in our patient, neurological symptoms typically occur between 7 and 96 hours after initiation of thrombolysis. Most intracranial hemorrhages occurring after thrombolysis for myocardial ischemia are lobar in location (70%), other locations being thalamus (17%) and brain stem or cerebellum (13%).¹⁵ Roughly a third of patients who suffer intracerebral hemorrhage as a complication of cardiac thrombolytic therapy present with bleeding at multiple sites within the brain. The predominance of lobar hemorrhages has led to speculation that amyloid angiopathy may underly many of these injuries. Others suggest that postthrombolysis hemorrhage occurs at the sites of previous, perhaps silent, infarcts.¹⁶ The latter explanation seems more likely in our patient with bilateral deep gray matter lesions.

In the short run, IV t-PA will probably have very little effect on rehabilitation. The patient population to which IV t-PA will initially be available will be small because of the need to evaluate, perform CT, and begin drug infusion within 3 hours of the onset of symptoms. Data from European thrombolytic trials^{13,14}

Table 1: Neuropsychological Test Results

Test	Raw Score	Standard Score
Boston Naming Test	31/60	z = -4.5
COWAT	15	< 1st percentile
WAB Comprehension A	60/60	WNL
WAB Comprehension B	80/80	WNL
WMS-R Log. Mem. I	7/50	4th percentile
WMS-R Log. Mem. II	0/50	2nd percentile
WMS-R Vis. Repro. I	0/41	2nd percentile
WMS-R Vis. Repro. II	0/41	2nd percentile
Digit Span Forward	6	22nd percentile
Digit Span Backward	2	2nd percentile
Visual Form Discrimination	2/32	Defective
RCPM	4/36	<5th percentile
Finger Tapping Dominant	10	T = 22
Finger Tapping Nondominant	9	T = 23
Motor Impersistence	1/8	Defective

Abbreviations: COWAT, Controlled Oral Word Association Test; WAB, Western Aphasia Battery; WMS-R, Wechsler Memory Scale-Revised; RCPM, Raven's Colored Progressive Matrices.

for stroke demonstrate unacceptable rates of cerebral hemorrhage when drug is administered beyond 3 hours. Because of this strict time limitation, we estimate that no more than 5% of stroke patients will be eligible for IV t-PA in our tertiary care center. Moreover, although some patients may be helped by the treatment, there will be an increase in symptomatic cerebral hemorrhage associated with its use in other patients, which may counterbalance the effect of IV t-PA on rehabilitation populations.

We believe that rehabilitation physicians should only rarely refer their patients for IV t-PA. As of this writing, IV t-PA has not been approved by the Food and Drug Administration for use in stroke. Thus, physicians are likely to adhere strictly to the National Institutes of Health trial IV t-PA inclusions: onset of symptoms within 3 hours, no evidence of cerebral hemorrhage on CT, no history of cerebral hemorrhage, no history of surgery within 14 days, and no use of anticoagulants within 48 hours. We anticipate that few rehabilitation inpatients, and only an occasional rehabilitation outpatient, will qualify.

In summary, we report a remarkable cognitive syndrome resulting from an extremely unusual cerebrovascular accident. The likely cause of this patient's cerebral hemorrhage was intravenous thrombolytic therapy, and rehabilitation physicians may encounter more such patients if the use of IV t-PA for acute stroke becomes widespread.

Since the acceptance of this article, IV t-PA has been approved by the Food and Drug Administration for use in acute stroke. A multicenter trial of the use of IV t-PA in acute stroke for 3 to 5 hours after the onset of symptoms is planned.

References

1. rt-PA Stroke Study Group. Tissue plasminogen activator for acute ischemic stroke. *N Engl J Med* 1995;333:1581-7.
2. Keith RA, Granger CV, Hamilton BB, Sherwin FS. The functional independence measure: a new tool for rehabilitation research. In: Eisenberg MG, Gresiak RC, editors. *Advances in clinical rehabilitation*. New York: Springer, 1987:6-18.
3. Bogousslavsky J, Regli J, Delaloye B, Delaloye-Bischof A, Assal G, Uske A. Loss of psychic self activation with bithalamic infarction. *Acta Neurol Scand* 1995;83:309-16.
4. Graff-Radford NR, Tranel D, Van Hoesen GW, Brandt JP. Diencephalic amnesia. *Brain* 1990;113:1-25.
5. Sobel BE, Collen D. Strokes, statistics, and sophistry in trials of thrombolysis for acute myocardial infarction. *Am J Cardiol* 1993;71:424-7.
6. Bogousslavsky J, Regli F, Uske A. Thalamic infarcts: clinical syndromes, etiology, and prognosis. *Neurology* 1988;38:837-48.
7. Guberman A, Stuss D. The syndrome of bilateral paramedian thalamic infarction. *Neurology* 1983;33:540-6.
8. Castaigne P, Lhermitte F, Buge A, Escourrolle R, Hauw JJ, Lyon-Caen O. Paramedian thalamic and midbrain infarcts: clinical and neuropathological study. *Ann Neurol* 1981;10:127-48.
9. Chua KSG, Kong K. Functional outcome in brain stem stroke patients after rehabilitation. *Arch Phys Med Rehabil* 1996;77:194-7.
10. Kase CS, Pessin MS, Zivin JA, Del Zoppo GJ, Furlan AJ, Buckley JW, et al. Intracranial hemorrhage after coronary thrombolysis with tissue plasminogen activator. *Am J Med* 1992;92:384-90.
11. Wijndicks EFM, Jack Jr CJ. Intracerebral hemorrhage after fibrinolytic therapy for acute myocardial infarction. *Stroke* 1993;24:554-7.
12. Grines CL, DeMaria AN. Optimal utilization of thrombolytic therapy for acute myocardial infarction: concepts and controversies. *J Am Coll Cardiol* 1990;16:223-31.
13. Hacke W, Kaste M, Fieschi C, Toni D, Lesaffre E, von Kummer R, et al. Intravenous thrombolysis with recombinant tissue plasminogen activator for acute hemispheric stroke. *JAMA* 1995;274:1017-25.
14. Multicentre Acute Stroke Trial-Italy (MAST-I) Group. Randomised controlled trial of streptokinase, aspirin, and combination of both in treatment of acute ischaemic stroke. *Lancet* 1995;346:1509-14.
15. Gore JM, Sloan M, Price TR, Randall AM. Intracerebral hemorrhage, cerebral infarction, and subdural hematoma after acute myocardial infarction and thrombolytic therapy in the Thrombolysis in Myocardial Infarction Study. *Circulation* 1991;83:448-59.
16. Molinari GE. Lobar hemorrhages: Where do they come from? How do they get there? *Stroke* 1993;24:523-26.