

## CASE REPORT

# A rare case of diplopia: medial inferior pontine syndrome or Foville's syndrome

I. HUBLOUE<sup>1</sup>\*, S. LAUREYS<sup>2</sup> and A. MICHOTTE<sup>2</sup>

<sup>1</sup>*Emergency Department and* <sup>2</sup>*Neurology Department, University Hospital of the Free University of Brussels (AZ-VUB), 101 Laarbeeklaan, 1090 Brussels, Belgium*

A case of medial inferior pontine syndrome or Foville's syndrome is described. The patient presented to the emergency department with an acute history of slurred speech, vertigo and diplopia as major complaints. He also mentioned the appearance of weakness and numbness in his left leg. The physical examination revealed a crossed neurological deficit (ipsilateral cranial nerve deficit with contralateral motor weakness) which is typical for posterior circulation stroke in the brainstem territory. In our patient the lesion was located in the right medial inferior pontine region. All the symptoms and signs disappeared within 24 hours confirming the importance of a detailed physical and neurological examination of each patient presenting at the emergency department with a neurological deficit.

**Keywords:** crossed paralysis; medial inferior pontine syndrome; Foville's syndrome; symptoms and signs

## CASE REPORT

A 74-year-old retired musician was admitted to the emergency department with a history of slurred speech, vertigo and diplopia. He also mentioned the appearance of weakness and numbness in his left leg. The patient's wife noticed the presence of strabismus as a result of impaired motility of the right eye. All these symptoms suddenly occurred 2 h before admission.

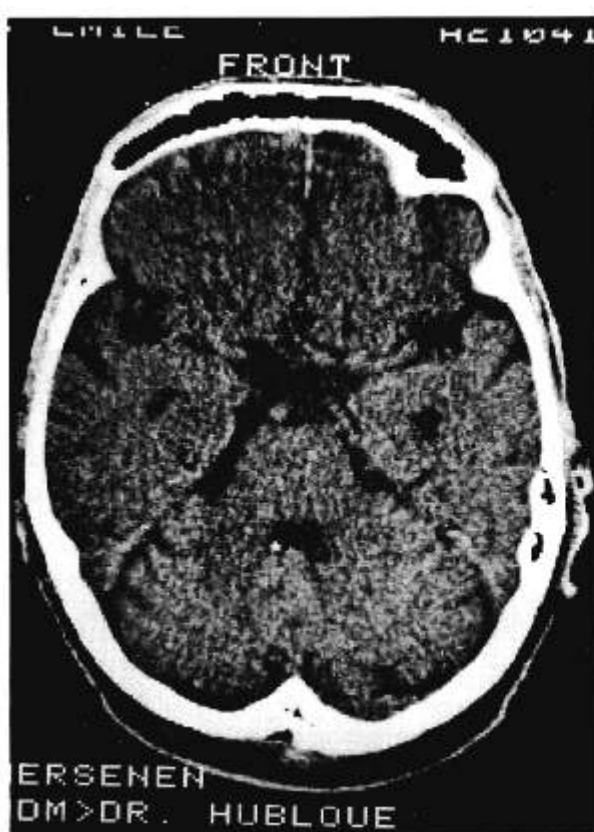
Medical history consisted of depression, an acute myocardial infarction, a cerebellar stroke a few years earlier and multiple surgical interventions (bilateral inguinal hernia, left meniscectomy, partial gastrectomy after peptic ulcer, peritonitis of unknown origin, removal of vocal cord polyps). He also wore a hearing-aid for bilateral hypacusis due to otosclerosis. He stopped smoking cigarettes 9 years previously; the tobacco-consumption at that time was estimated at 50 packyears. There was no abuse of alcohol. His daily medication consisted of amitriptylin 75 mg once a day and bromazepam 6 mg before sleeping.

General physical examination showed no abnormal findings. The blood pressure was 130/80 mmHg, the heart rate 80 beats/min and regular. Auscultation of the heart and lungs was normal, as was the examination of the abdomen. A detailed neurological examination revealed a normal mental status, adduction and abduction paresis of the right eye, adduction paresis of the left eye and a horizontal nystagmus of the left eye on lateral gaze (abduction). There was a weakness of the right half of the face with a marked asymmetry of the nasolabial folds. Furthermore the patient presented a mild paresis of the left arm and leg and an impaired tactile and proprioceptive sense over the left half of the body with preserved pain and temperature perception. The finger-nose testing was less disturbed than the heel-to-shin testing on the left side of the body. Performing the Romberg-test the patient had difficulty in holding his position with open as well as with closed eyes. He tended to fall over to the right. Both deep tendon and regressive reflexes were symmetric and brisk. Snout, root and grasp reflexes were absent.

Based on the medical history and the findings on the clinical examination the diagnosis of posterior circulation stroke, more specific right medial

---

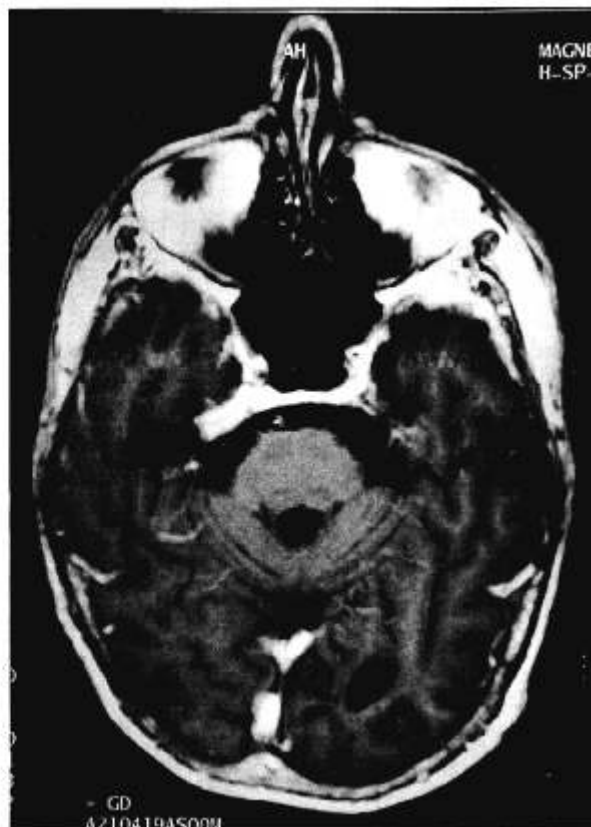\* To whom correspondence should be addressed



**Fig. 1.** Computed tomography scan of the brain (at the level of the pons) performed 6 h after admission.

inferior pontine syndrome or Foville's syndrome was forwarded. ECG, chest X-ray and blood analysis performed at the emergency department were normal. A computed tomography (CT) scan of the brain with and without contrast performed 6 h after admission revealed cortical atrophy but no other abnormalities (Fig. 1). The patient was admitted to the neurology ward for a detailed neurological work-up. Aspirin 160 mg once a day was added to his daily medication.

The day after his admission the neurological examination was completely normal. A magnetic resonance image (MRI) of the brain confirmed the presence of cortical atrophy but no other abnormal findings were evidenced (Fig. 2). Electroencephalography (EEG) and echocardiography were normal. An isotopic brain perfusion-scintigraphy with acetazolamide stress-testing showed a decreased vasodilatory reserve in the territory of the vertebrobasilar circulation. On carotid duplex scanning normal flow-velocities in both arteries and no high-grade stenoses were found. An angiography of the aortic cross, carotid and vertebral arteries, performed to complete the neurovascular evaluation, demonstrated in contrast with the duplex scanning an asymmetric concentric



**Fig. 2.** Magnetic resonance image of the brain (at the level of the pons) performed the day after admission.

stenosis of 75% at the level of the right carotid artery bifurcation and also a hypoplastic right vertebral artery with multiple stenotic lesions. The asymptomatic character of this 75% stenosis made it no direct indication for carotid endarterectomy.

After 5 days the patient was dismissed from the hospital. On neurological examination a few weeks later at the outpatient clinic no abnormal findings could be evidenced. His daily medication consisted of aspirin 160 mg once a day, amitriptylin 75 mg once a day and bromazepam 6 mg before sleeping.

## DISCUSSION

Neurological disorders are among the most common in the emergency department (ED). The approach of the patient with a neurological deficit can be considered a challenging test of the problem-solving ability of the emergency physician. Although a large battery of diagnostic tests is available for each problem daily seen in the ED, the diagnosis of neurological problems is mainly based on medical history and on detailed neurological examination. The physician must integrate

**Table 1.** The lesion sites and associated clinical syndromes in the four crossed paralyses

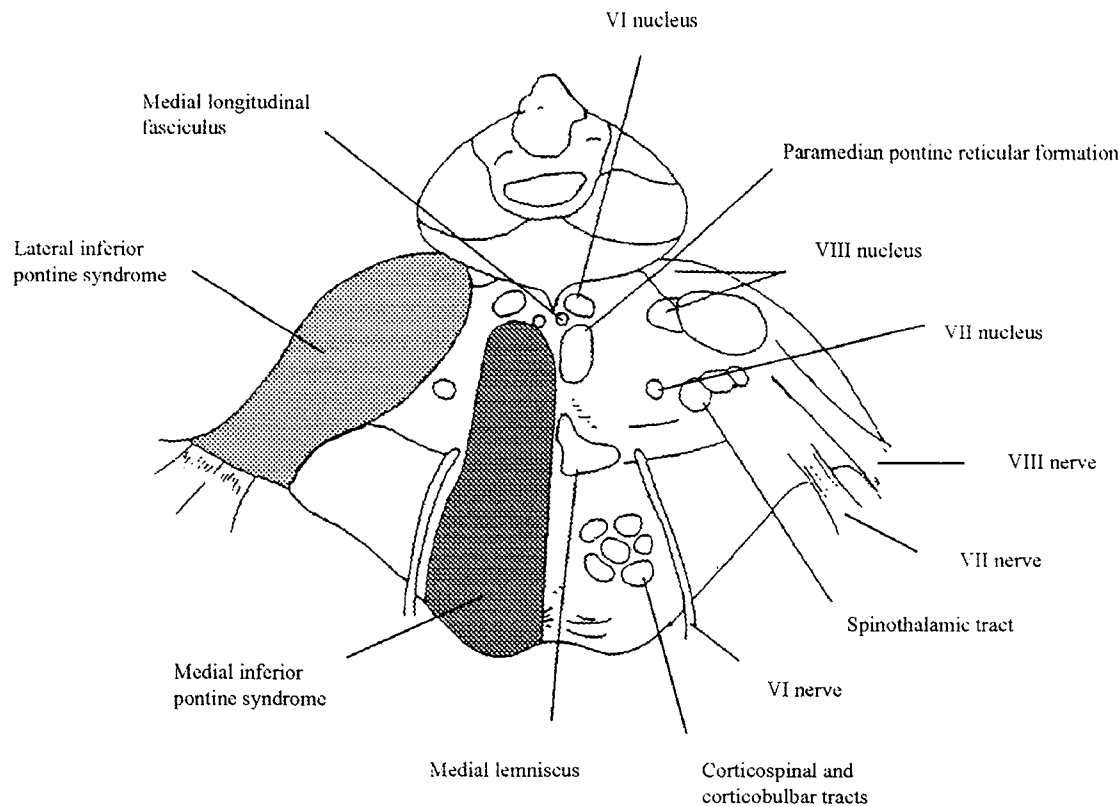
Syndrome	Lesion site	Clinical syndrome
Millard-Gubler (1856)	Caudal ventral pons: cranial nerve VII Corticospinal tract	Facial palsy Contralateral hemiparesis
Weber (1863)	Cerebral peduncle: cranial nerve III Corticospinal tract	Oculomotor palsy Contralateral hemiparesis
Raymond-Cestan (1903)	Rostral tegmental pons: medial longitudinal fasciculus Corticospinal tract Medial lemniscus Spinothalamic tract Superior/middle cerebellar peduncle	Internuclear ophthalmoplegia Contralateral dysesthesias Cerebellar signs Hemiparesis
Foville (1858)	Caudal tegmental pons: cranial nerve VII, VI Paramedian pontine reticular formation Corticospinal tract	Facial paralysis Conjugate gaze paralysis Contralateral hemiparesis

physical findings with brain anatomy and function to determine the anatomic location of the lesion. His second goal will be the determination of the possible vessels that may be involved in case of stroke syndromes. One should keep in mind that physical findings often follow very classical patterns that can assist the emergency physician when locating the lesion. As an example of the importance of a carefully performed neurological examination on admission, we described this case of medial inferior pontine syndrome or Foville's syndrome.

The four original brainstem syndromes described in the 19th century by Millard, Gubler, Weber, Foville, Raymond and Cestan contributed largely to the understanding of the neuro-anatomy of the brain stem (Foville, 1858; Larmande, 1985; Silverman *et al.*, 1995). These crossed paralyses featured cranial nerve deficits contralateral to limb weakness (Wall, 1991; Simon and Ho, 1992; Silverman *et al.*, 1995; Henry, 1996). In the case of the Millard-Gubler syndrome it consists of facial palsy and contralateral hemiparesis (Wall, 1991; Silverman *et al.*, 1995). The Weber syndrome is characterized by oculomotor palsy and contralateral hemiparesis (Wall, 1991; Silverman *et al.*, 1995). The Raymond-Cestan syndrome is known by the presence of an internuclear ophthalmoplegia and contralateral hemiparesis (Wall, 1991; Silverman *et al.*, 1995). In 1858 Achille Louis Foville (1799–1878) published a case of a 43-year-old commissioner suffering from a total left facial paralysis, an inability to look leftward and a right-sided hemiparesis (Foville, 1858). The Foville's syndrome is characterized by a peripheral type of facial palsy, conjugate gaze paraly-

sis and contralateral hemiparesis (Foville, 1858; Larmande, 1985; Wall, 1991; Silverman *et al.*, 1995). In the first original report Foville compared the control of horizontal conjugate eye-movements to a man steering two horses by uniting the reins in each hand. The clinical findings in his patient could be explained by a unilateral pontine lesion although he lacked any pathological finding to support his hypothesis (Foville, 1858). Table 1 summarizes the lesion sites and the associated clinical syndromes in the four crossed paralyses.

The brainstem, cerebellum and visual cortex receive their blood supplies from the posterior circulation (Wall, 1991; Simon and Ho, 1992; Kothari and Barson, 1996). Ischaemia in the vertebro-basilar circulation will lead to lesions with varied structural alterations and with a rostrocaudal or patchy localization (Hashizume *et al.*, 1984; Wall, 1991). Hence a stroke in this area is characterized by very subtle signs and symptoms like dizziness, vertigo, diplopia, ataxia, cranial nerve palsies and bilateral limb weakness (Hashizume *et al.*, 1984; Wall, 1991; Henry, 1996; Kothari and Barson, 1996). The clinicopathological correlation will not always be precise for these symptoms and signs. However, involvement of the long tracts of the brainstem and deficits of cranial nerve nuclei are the hallmarks of a brainstem stroke (Wall, 1991; Simon and Ho, 1992; Silverman *et al.*, 1995; Henry, 1996; Kothari and Barson, 1996). As already mentioned, ipsilateral cranial nerve deficits with contralateral motor or sensory long-tract deficits are the most characteristic signs; hence the term 'crossed paralyses' (Wall, 1991; Simon and Ho, 1992; Silverman *et al.*, 1995; Henry, 1996; Kothari and Barson, 1996).



**Fig. 3.** Cross-section through the inferior pons at the level of the VI nerve nucleus.

Next we will focus on the symptoms and signs of the Foville's syndrome. Common symptoms in patients with medial inferior pontine syndrome are contralateral weakness and numbness, ipsilateral total facial weakness and diplopia (Wall, 1991; Silverman *et al.*, 1995). Physical examination will reveal a contralateral paralysis or paresis of the arm and the leg, an impaired tactile and proprioceptive sense over half of the body at the opposite site of the lesion and an internuclear ophthalmoplegia (Wall, 1991; Silverman *et al.*, 1995). An internuclear ophthalmoplegia is characterized by an adduction paresis of one eye with a horizontal nystagmus in the contralateral eye when it is abducted (Larmande *et al.*, 1973; Striano *et al.*, 1990; Wall, 1991). The lesion which causes an internuclear ophthalmoplegia is localized in the medial longitudinal fasciculus between the nuclei of cranial nerve III and VI (Wall, 1991). In our patient we have an adduction paresis of the right eye with the presence of a horizontal nystagmus in the left eye on lateral gaze. Presence of an internuclear ophthalmoplegia is generally caused by a stroke in elderly patients and by multiple sclerosis in young patients (Wall, 1991; Kothari and Barson, 1996).

Ipsilateral signs of the medial inferior pontine syndrome are paresis of conjugate gaze to the site

of the lesion and also to the oculocephalic manoeuvre if the nucleus of the cranial nerve VI is involved (Wall, 1991). Other ipsilateral signs are a one-and-a-half syndrome, a nystagmus, diplopia on lateral gaze and a peripheral type of facial palsy (Wall, 1991; Silverman *et al.*, 1995). A one-and-a-half syndrome is the combination of an internuclear ophthalmoplegia on looking away from the lesion with a gaze palsy on looking toward the site of the lesion (Larmande *et al.*, 1973; Striano *et al.*, 1990; Wall, 1991). Our patient presented a typical one-and-a-half syndrome: on looking to the right (site of the lesion) he presented a gaze palsy; on looking to the left (away from the lesion) he presented an adduction paresis of the right eye with a horizontal nystagmus of the left eye. The site of the lesion is the right paramedian pontine reticular formation or the nucleus of the cranial nerve VI. An extension of the lesion site with involvement of the internuclear fibres crossing from the contralateral VI nerve nucleus is responsible for the internuclear ophthalmoplegia (Larmande *et al.*, 1973; Striano *et al.*, 1990; Wall, 1991).

Figure 3 shows a cross-section through the inferior pons at the level of the nucleus of cranial nerve VI. The shaded areas are the lesion sites in case of a lateral and medial inferior pontine syndrome. Occlusion of the median branches of the

basilar artery is responsible for the Foville's syndrome. An occlusion of the anterior inferior cerebellar artery leads to the lateral inferior pontine syndrome (Wall, 1991).

As in our patient the diagnosis can be made on the clinical history and physical examination alone. Imaging techniques may be of assistance depending upon the circumstances (Wall, 1991; Simon and Ho, 1992; Kothari and Barson, 1996). CT scan without contrast is essential in differentiating ischaemic from haemorrhagic infarction (Wall, 1991; Simon and Ho, 1992; Kothari and Barson, 1996). The role of MRI in the emergency department is not well known, mostly due to its inavailability to every ED (Kothari and Barson, 1996). Ischaemic infarcts apparently can be visualized earlier by MRI than by conventional CT (Wall, 1991; Kothari and Barson, 1996). MRI is also more effective than CT in identifying acute posterior circulation strokes (Wall, 1991; Kothari and Barson, 1996). In our patient the MRI of the brain did not demonstrate ischaemic lesions in the pontine region.

We also performed a brain perfusion-scintigraphy with Technetium-99m hexamethyl propylamine oxide (HMPAO) with acetazolamide stress-testing, which in our experience and in others can be used as a functional and non-invasive method to evaluate the vasodilatory reserve of the posterior circulation (Matsuda *et al.*, 1991; Trouillas *et al.*, 1991; Masdeu *et al.*, 1994; Laureys *et al.*, 1996). The standard to demonstrate stenoses, occlusions of large and small blood vessels in the brain definitely remains the angiography (Simon and Ho, 1992; Kothari and Barson, 1996). Angiography can detect subtle arterial abnormalities missed by other imaging techniques. Everybody should be aware of its cost, availability and invasiveness (Simon and Ho, 1992; Kothari and Barson, 1996).

In conclusion we would like to emphasize the importance of a detailed clinical examination, including a detailed neurological examination in each patient presenting at the emergency department with a neurological disorder. As symptoms and signs can disappear within a few hours, the first assessment of the patient by the emergency physician is of great importance and is often the

key to the diagnosis. Furthermore diagnostic imaging techniques will not always be able to confirm the clinical diagnosis.

## ACKNOWLEDGEMENTS

We thank Marc Terriere and Eddy Broodtaerts for their technical assistance in obtaining Figs 1, 2 and 3.

## REFERENCES

- Foville, A. (1858) Note sur une paralysie peu connue de certains muscles de l'oeil, et sa liaison avec quelques points de l'anatomie et la physiologie de la protubérance annulaire. *Bull. Soc. Anat. Paris*, **33**, 393-414.
- Hashizume, Y., Kishimoto, H. and Iijima, S. (1984) Occlusion of the basilar artery. A clinical and pathological study of thirteen autopsied cases. *Acta Pathol. Jpn*, **34**, 29-40.
- Henry, G.L. (1996) The neurological examination. In: Tintinalli, J.E., Ruiz, E. and Krome, R.L., eds. *Emergency Medicine, a Comprehensive Study Guide*. New York: McGraw-Hill, pp. 1005-8.
- Kothari, R.U. and Barson, W. (1996) Management of stroke. In: Tintinalli, J.E., Ruiz, E. and Krome, R.L., eds. *Emergency Medicine, a Comprehensive Study Guide*. New York: McGraw-Hill, pp. 1014-21.
- Larmande, A.M., Rossazza, C. and Delplace, M.P. (1973) Significance of the association of Foville's syndrome with contralateral anterior internuclear ophthalmoplegia. *Rev. Otoneuroophthalmol*, **45**, 165-7.
- Larmande, A.M. (1985) Points of history apropos of Foville's first publication. *J. Fr. Ophthalmol.*, **8**, 511-12.
- Laureys, S., Flamen, P., Franken, Ph., Everaert, H., Michotte, A., Ebinger, G. and Bossuyt, A. (1996) Acetazolamide enhanced Tc-99m HMPAO brain perfusion SPECT in patients with vertebro-basilar insufficiency. *J. Nucl. Med.*, **37**, 88 (abstract).
- Masdeu, J.C., Brass, L.M., Holman, B.L. and Kusher, M.J. (1994) Brain single-photon emission computed tomography. *Neurology*, **44**, 1970-7.
- Matsuda, H., Higashi, S. and Kinuya, K. (1991) SPECT evaluation of brain perfusion reserve by the acetazolamide test using Tc-99m HMPAO. *Clin. Nucl. Med.*, **16**, 572-9.
- Silverman, I.E., Liu, G.T., Volpe, N.J. and Galetta, S.L. (1995) The crossed paralyses. The original brain-stem syndromes of Millard-Gubler, Foville, Weber and Raymond-Cestan. *Arch. Neurol.*, **52**, 635-8.
- Simon, R.P. and Ho, M.T. (1992) Weakness and stroke. In: Saunders, C.E. and Ho, M.T., eds. *Current Emergency Diagnosis and Treatment*. East Norwalk: Appleton and Lange, pp. 180-201.
- Striano, S., Luciano, R., Meo, R., Bilo, L., Orefice, G. and Grasso, A. (1990) The physiology of supranuclear structures in oculomotor disorders. *Acta Neurol. Napoli*, **12**, 151-71.
- Trouillas, P., Nighoghossian, N. and Philippon, B. (1991) Nuclear hemodynamic vertebrobasilar insufficiency. A new approach with the xenon Xe 133 method. *Arch. Neurol.*, **48**, 921-9.
- Wall, M. (1991) Brainstem syndromes. In: Bradley, W.G., Daroff, R.B., Fenichel, G.M. and Marsden, C.D., eds. *Neurology in Clinical Practice. Principles of diagnosis and management. Volume 1*. Stoneham: Butterworth-Heinemann, pp. 347-62.