

Pituitary apoplexy producing internal carotid artery occlusion

Case report

THOMAS J. ROSENBAUM, M.D., O. WAYNE HOUSER, M.D.,
AND EDWARD R. LAWS, M.D.

Departments of Neurologic Surgery and Diagnostic Roentgenology, Mayo Clinic and Mayo Foundation, Rochester, Minnesota

✓ The authors report a case of pituitary apoplexy occurring several hours after carotid angiography. The event was associated with stupor, focal headache, and left hemiparesis. Repeat angiography demonstrated intracranial occlusion of the right internal carotid artery. At surgery, a hemorrhagic pituitary adenoma was found to be compressing the internal carotid artery, and the removal of the tumor resulted in restoration of flow. The mechanism, presenting symptoms and signs, and treatment of pituitary apoplexy causing compression of a major vessel are discussed.

KEY WORDS • pituitary apoplexy • carotid angiography • cerebrovascular disease • vascular occlusion

SINCE the initial report of Bleibtreu in 1905,² hemorrhage into a pituitary adenoma has been recorded over 200 times in the literature. Many precipitating factors have been implicated, including trauma,²⁰ radiotherapy,¹⁸ anticoagulant therapy,¹² nasal catarrh,⁵ estrogen treatment,¹³ and pneumoencephalography.⁵ Hemorrhage after cerebral angiography has been reported twice previously.^{5,19} The usual presenting symptoms and signs of pituitary apoplexy are headache, altered consciousness, nausea, extraocular palsies, pupillary abnormalities, and visual loss. Signs of focal cerebral hemispheric dysfunction are uncommon. The following is a case of pituitary apoplexy that occurred after carotid angiography and was associated with intracranial occlusion of the right internal carotid artery and left hemiparesis.

Case Report

This 77-year-old farmer was in good health until 1972, when he first noted some visual loss. In February, 1976, when he was no longer able to drive his tractor because of gradual progression of his visual symptoms, he sought medical attention and was admitted to the hospital in April, 1976, for evaluation of a suspected pituitary tumor. His past health had been excellent with the exception of mild diabetes, for which he was taking oral medication. He gave no history suggestive of endocrine deficiency.

Examination. The general medical examination was unremarkable. Neurological examination was normal with the exception of the visual system. The right eye had vision for gross hand movement in the nasal field only, an afferent pupillary defect, and Grade

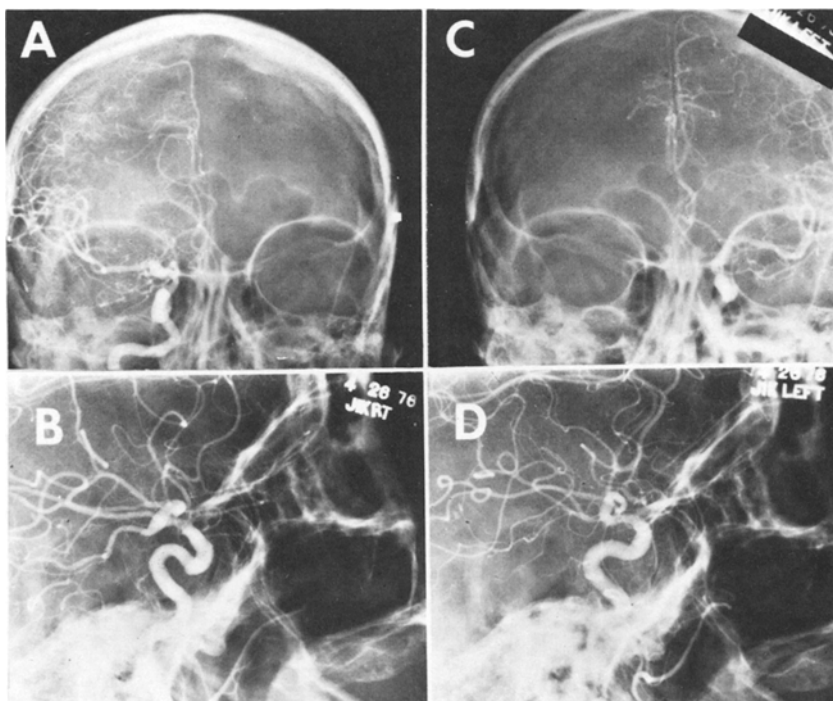


FIG. 1. Right and left anteroposterior and lateral common carotid angiograms. Bilateral suprasellar extension of the mass is evident.

4/4 pallor of the disc. The left eye had a complete temporal field loss, nasal field vision of 14/224, and Grade 3/4 pallor of the disc.

The fasting blood sugar was 93 mg/100 ml. Morning and afternoon corticosteroid levels were normal (12.0 and 8.8 $\mu\text{g}/\text{dl}$ plasma), and total (4.4 $\mu\text{g}/\text{dl}$) and free thyroxine (0.9 $\mu\text{g}/\text{dl}$) were low normal. Electrolytes, creatinine, and serology were normal, as were the remainder of the laboratory studies.

Skull roentgenograms showed a large destructive lesion causing expansion of the sella. Spiral polytomograms of the sella confirmed the presence of a lesion that seemed to extend into the sphenoid sinus and to be larger on the left than on the right side.

The day after admission, after appropriate preparation with cortisone, bilateral common carotid angiograms were performed. An intrasellar mass with a capillary blush showing suprasellar and bilateral parasellar extension was confirmed (Fig. 1). The diagnosis of a chromophobe adenoma was made and the patient was scheduled for transsphenoidal excision the next morning.

Twelve hours after angiography the patient complained of a right-sided headache, but at midnight he was alert and oriented, and was able to go to the bathroom unassisted. At 2:30 A.M. the patient became stuporous and gave inappropriate responses. His blood pressure rose to 220/120, pulse 60, and respiration rate 24. His pupils were equal and unchanged from their appearance at his hospital admission examination, but his eyes were tonically deviated to the right. He had a left central facial weakness, left hemiparesis, left hypotonia, and a left Babinski sign. Emergency bilateral common carotid angiograms were performed. These studies demonstrated occlusion of the right internal carotid artery; no contrast medium passed above the level of C-1. There was focal narrowing of the supraclinoid portion of the left internal carotid artery, which was not present on the previous angiogram and was believed to represent spasm. The previously noted elevation of the A-1 segment of the left anterior cerebral artery was unchanged. The right anterior cerebral artery now filled from

Pituitary apoplexy and carotid obstruction

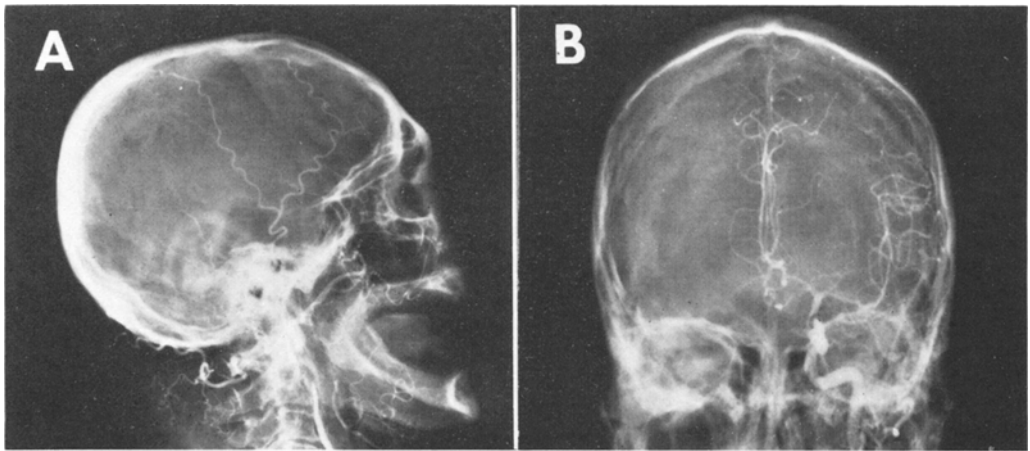


FIG. 2. Repeat right lateral and left anteroposterior common carotid angiograms following the apoplectic event. There is total obstruction to the flow of dye past C-1 on the right. The left supraclinoid internal carotid shows focal narrowing with filling of the right anterior cerebral artery.

the left carotid injection (Fig. 2). These findings were believed to be compatible with pituitary apoplexy causing obstruction of the right internal carotid artery in the cavernous or supraclinoid portion.

Operation. An emergency right frontotemporal craniotomy was done. The right frontal and temporal lobes appeared slightly pale. A large pituitary adenoma projected between the optic nerves anteriorly with a very firm nodule extending between the right optic nerve and the right internal carotid artery posterolaterally. The nodule contained fresh hemorrhage and was directly compressing the carotid artery. After the removal of this nodule, the right carotid artery began to pulsate normally. A radical subtotal removal of the tumor was accomplished and hemostasis was achieved. The intraoperative pathology report was pituitary adenoma with recent intraglandular hemorrhage throughout the majority of specimen removed.

Postoperatively, the patient remained stuporous and hemiplegic. Over the ensuing 2 days he gradually became more obtunded and died of respiratory arrest.

Pathological Findings. Autopsy revealed intrasellar and suprasellar residual pituitary adenoma, hematoma, and surgical packing. Atrophy of the right optic nerve and early partial necrosis of the optic chiasm were present. There was no evidence of an intravascular lesion suggestive of an angiographic complication such as intimal dissection or

hematoma at the puncture site. The carotid bifurcation had minimal atherosclerosis. There was atherosclerosis, Grade 2 (50% narrowing) of the right internal carotid artery in the cavernous sinus and Grade 3 (90% narrowing) at the origin of the middle cerebral artery. Transtentorial herniation with secondary brain-stem hemorrhages was present (Fig. 3).

Discussion

Hemiplegia as one of the presenting signs of pituitary apoplexy is unusual, but it has been recorded at least eight times. Schnitker and Lehnert,¹⁷ Rovit and Fein,¹⁶ Jolley and Mabon,⁹ Brougham, *et al.*,³ List, *et al.*,¹⁰ Wright, *et al.*,²¹ and Epstein, *et al.*,⁶ each recorded a confirmed case and Roberts, *et al.*,¹⁴ a single presumptive case. Lopez¹¹ reported one patient with pituitary apoplexy and hemiparesis, but the onset of hemiparesis followed angiography, which was performed several hours after the initial ictus; therefore the hemiparesis but not the pituitary apoplexy could be considered a complication of angiography.¹¹

When focal cerebral signs are associated with pituitary apoplexy, cerebral ischemia has been postulated to be the mechanism, resulting from spasm, hypotension, or the mechanical obstruction pressure effects of an enlarging mass upon a large artery. After angiography, hemiplegia may also result

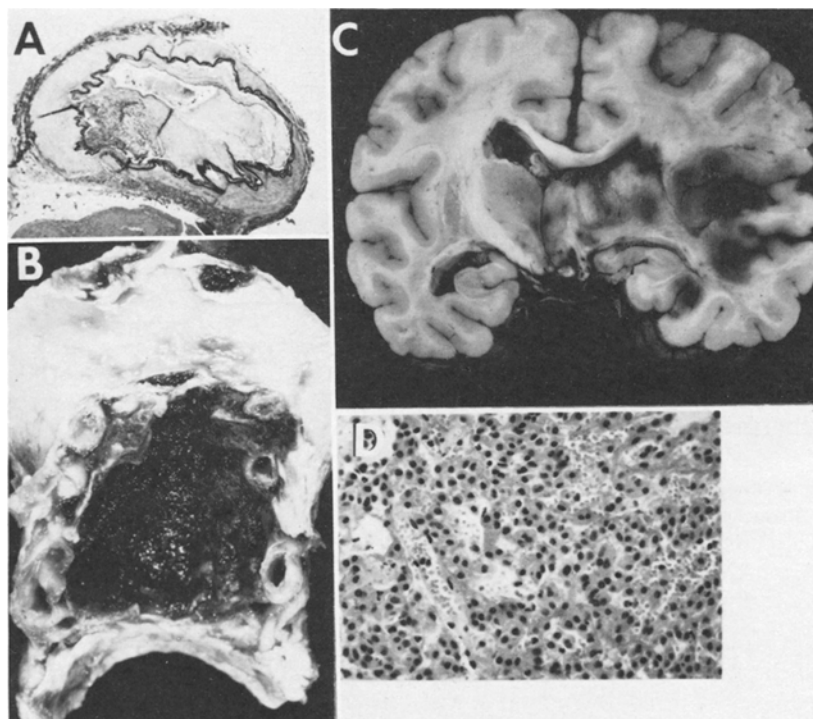


FIG. 3. Pathological specimens: A: Origin of the right middle cerebral artery with 90% atherosclerotic narrowing. B: Gross specimen of the sella demonstrating residual tumor and its relationship to the carotid arteries. C: Right middle cerebral artery distribution hemorrhagic infarction. D: Residual pituitary adenoma removed at postmortem examination.

from emboli formed at the puncture site, dislodged plaque, intimal dissection, toxicity from contrast substance, or combinations of these factors. In our case, an embolus from the carotid puncture site could have produced the catastrophic event; however, it seems more likely that the internal carotid artery was obstructed by an enlarging hemorrhagic tumor which caused right hemispheric infarction and left hemiparesis. Decompression of the internal carotid artery resulted in a patent vessel but may have converted a pale cerebral infarct into a hemorrhagic infarct.

Schnitker and Lehnert¹⁷ reported on a patient presenting with the syndrome of middle cerebral artery thrombosis who, at autopsy 16 days later, had a large right hemispheric infarction and a hemorrhagic pituitary adenoma that had caused compression of the right middle cerebral artery. Sakalas, *et al.*,¹⁸ reported on a 6-year-old boy with visual loss, lethargy, and a stiff neck. Although hemiparesis was not a presenting sign,

angiography showed that the left carotid artery was functionally occluded, and primary filling of the left middle cerebral artery occurred via the posterior circulation. At surgery, an eosinophilic adenoma was found to be compressing the left internal carotid artery. Thus, including our case, it has been verified in three cases that large artery mechanical obstruction can cause decreased cerebral perfusion.

Vascular spasm has been reported to be associated with pituitary apoplexy⁷ but has not yet been shown to cause cerebral ischemia. Our patient had spasm of the left internal carotid artery but the cerebral ischemia was right-sided secondary to right internal carotid artery occlusion. Rovit and Fein¹⁵ detailed a case with left hemiparesis and narrowing of the right internal carotid artery, but a prominent mass effect was present and the angiogram may have reflected direct compression rather than spasm. Systemic hypotension occurs not uncom-

Pituitary apoplexy and carotid obstruction

monly with pituitary apoplexy, but is associated with a decreased level of consciousness and not with focal cerebral hemispheric signs. Unless other factors are present, hypotension alone should not cause a focal neurological deficit. Pituitary apoplexy with hypotension and hemiparesis has been described twice but in both cases the hemiparesis occurred several days after the initial ictus.^{5,8} Angiography after the onset of hemiparesis was not performed to determine if other factors were present to account for this finding.

Pituitary apoplexy with focal cerebral signs has been reported twice when angiography revealed a pituitary tumor but did not show spasm or obstruction of a major vessel. In these cases, angiography was delayed 1 week to 1 month; either spasm or obstruction could have resolved in that period of time, leaving a residual cerebral infarction and hemiparesis.^{6,21}

Because of the small number of recorded cases of hemorrhage into a pituitary adenoma with associated focal cerebral deficit, statistical analysis of the efficacy of surgical intervention for this specific entity is not possible. Analysis of previously reported cases and the current case indicates that one patient did well and two did poorly with conservative therapy, and one did well and four had significant morbidity or mortality after surgical decompression. Both patients in whom improvement followed surgery had milder preoperative neurological deficits than did any of the six patients who had an unfavorable outcome. The size of the mass necessary to produce cerebral ischemia and the added insult of a cerebral infarction may be the cause of the high mortality rate.

Pituitary apoplexy should be suspected if a catastrophic event occurs in conjunction with extraocular muscle paresis, visual loss, and an enlarged sella on x-ray examination. Angiography is necessary to eliminate the possibility of aneurysmal rupture and to confirm the presence of a pituitary adenoma. Preservation of vision is a primary objective in surgical intervention. Prompt transphenoidal surgical decompression has recently been associated with a favorable outcome.^{1,4,22} In our case, it is doubtful that transphenoidal decompression would have been sufficient to decompress the right internal carotid artery. If focal cerebral hemi-

spheric signs are present and angiography reveals large vessel occlusion, transfrontal decompression within several hours of the initial ictus may be beneficial.

References

1. Berti G, Heisey WG, Dohn DF: Pituitary apoplexy treated by stereotactic transphenoidal aspiration. *Cleve Clin Q* 41:163-175, 1974
2. Bleibtreu L: Ein Fall von Akromeglie (Zerstörung der Hypophysis durch Blutung). *Munch Med Wochenschr* 52:2079-2080, 1905
3. Brougham M, Heusner AP, Adams RD: Acute degenerative changes in adenomas of the pituitary body — with special reference to pituitary apoplexy. *J Neurosurg* 7:421-439, 1950
4. Conomy JP, Ferguson JH, Brodkey JS, et al: Spontaneous infarction in pituitary tumors: neurologic and therapeutic aspects. *Neurology (Minneapolis)* 25:580-587, 1975
5. Dawson BH, Kothandaram P: Acute massive infarction of pituitary adenomas. A study of five patients. *J Neurosurg* 37:275-279, 1972
6. Epstein S, Pimstone BL, de Villiers JC, et al: Pituitary apoplexy in five patients with pituitary tumours. *Br Med J* 2:267-270, 1971
7. Goodman JM, Gilson M, Shapiro B: Pituitary apoplexy — a cause of sudden blindness. *J Indiana State Med Assoc* 66:320-321, 1973
8. Jefferson M, Rosenthal FD: Spontaneous necrosis in pituitary tumours (pituitary apoplexy). *Lancet* 1:342-344, 1959
9. Jolley FL, Mabon RL: Pituitary apoplexy. *J Med Assoc Ga* 47:75-78, 1958
10. List CF, Williams JR, Balyeat GW: Vascular lesions in pituitary adenomas. *J Neurosurg* 9:177-187, 1952
11. Lopez IA: Pituitary apoplexy. *J Oslo City Hosp* 20:17-27, 1970
12. Nourizadeh AR, Pitts FW: Hemorrhage into pituitary adenoma during anticoagulant therapy. *JAMA* 193:623-625, 1965
13. Pouyanne L, Pouyanne H, Arne L: *La forme hémorragique des adénomes chromophobes hypophysaires (à propos de 3 observations), Hommage à Clovis Vincent, Vol 1.* Paris: Maloine, 1949, pp 81-84
14. Roberts LN, Goldberg WM, Pickard H: Panhypopituitarism in a male following pituitary apoplexy (treated with ACTH and cortisone). *Can Med Assoc J* 66:458-461, 1952
15. Rovit RL, Fein JM: Pituitary apoplexy: a review and reappraisal. *J Neurosurg* 37:280-288, 1972
16. Sakalas R, David RB, Vines FS, et al: Pituitary apoplexy in a child. Case report. *J Neurosurg* 39:519-522, 1973

17. Schnitker MT, Lehnert HB: Apoplexy in a pituitary chromophobe adenoma producing the syndrome of middle cerebral artery thrombosis. Case report. **J Neurosurg** **9**:210-213, 1952
18. Sosman MC: The roentgen therapy of pituitary adenomas. **JAMA** **113**:1282-1285, 1939
19. Steimle R, Royer J, Oppermann A, et al: Hématome post-angiographique dans un adénome de l'hypophyse. Cécité et troubles oculo-moteurs régressant après intervention d'urgence. **Neurochirurgie** **20**:599-608, 1974
20. VanWagenen WP: Haemorrhage into a pituitary tumor following trauma. **Ann Surg** **95**:625-628, 1932
21. Wright RL, Ojemann RG, Drew JH: Hemorrhage into pituitary adenomata. Report of two cases with spontaneous recovery. **Arch Neurol** **12**:326-331, 1965
22. Zervas NT, Mendelson G: Treatment of acute haemorrhage of pituitary tumours. **Lancet** **1**:604-605, 1975

Address reprint requests to: Thomas J. Rosenbaum, M.D., Department of Neurologic Surgery, Mayo Clinic, Rochester, Minnesota 55901.