

Paradoxical Cerebral Air Embolism From a Hemodialysis Catheter

Alan S.L. Yu, MB, BChir, and Elliott Levy, MD

● Air embolism is a rare complication of the use of central venous catheters as vascular access for hemodialysis. We report a patient with an intracardiac shunt who had a paradoxical air embolism following manipulation of her hemodialysis catheter that resulted in transient hemiplegia. This case illustrates the potentially devastating consequences of even a small air leak into the circulation if it gains access to the arterial system.

© 1997 by the National Kidney Foundation, Inc.

INDEX WORDS: Air embolus; hemodialysis; venous access.

TUNNELED, double-lumen central venous catheters are frequently used for semipermanent vascular access for hemodialysis. During dialysis, the air detector on the dialysis machine protects the patient from inadvertent air embolization. However, use of the catheter outside of hemodialysis may pose a potential source of air entry. We report a case of paradoxical air embolism resulting from the use of a central venous hemodialysis catheter to draw blood.

CASE REPORT

A 45-year-old white woman was admitted with dizziness. She had end-stage renal disease secondary to chronic pyelonephritis, had two previous failed cadaveric renal allografts, and was on chronic hemodialysis, using a tunneled Medcomp Tesio catheter in the right subclavian vein with its tip in the right atrium. She had also undergone bilateral nephrectomies resulting in chronic hypotension refractory to medical therapy, and suffered from frequent orthostatic dizziness, particularly after dialysis. She presented after a typical episode of dizziness and near-syncope occurring following an uneventful dialysis. The initial examination was remarkable only for a systolic blood pressure of 45 mm Hg. The symptoms improved and the systolic blood pressure increased to the patient's usual baseline of 50 to 60 mm Hg after intravenous infusion of 250 mL of isotonic saline.

In the emergency department, blood was drawn from the dialysis catheter for routine laboratory tests because no peripheral venous access could be obtained. Approximately 1 hour later, the patient noticed paralysis of her left arm and leg when attempting to move from the stretcher. She also complained of a left frontal headache, blurred vision, nausea, and paresthesias of the entire left side. On physical examination, the patient had flexor posturing of her left upper extremity, which had one sixth motor strength in all muscle groups, and complete paresis of the left lower extremity. Sensation to light touch and pinprick were diminished on the left trunk and extremities. Deep tendon reflexes were exaggerated on the left, and there was a left-sided extensor plantar reflex. There was no impairment of visual acuity, speech, thought clarity, or consciousness. Immediate computed tomography without intravenous contrast showed an area of decreased attenuation in the right superior frontal lobe of the cerebral cortex suspicious for an acute infarction, and also the presence of focal air deposits, indicating cerebral air emboli (Fig 1). On re-examination 1 hour later, motor strength had almost

returned to normal. Left-sided ataxia and hyperreflexia persisted for several hours, and the headache and paresthesias resolved over the next 3 weeks.

Careful inspection of the subclavian catheter revealed no cracks, the caps were appropriately tightened, and subsequent use of the catheter for hemodialysis was uneventful. Trans-thoracic echocardiography with bubble study revealed a patent foramen ovale with marked right-to-left shunting. Right heart catheterization was performed and the foramen was closed with a catheter-deployed button device.

DISCUSSION

This patient exhibited symptoms and signs of transient cerebral ischemia together with radiologic evidence of cerebral air emboli. The proximate temporal association of this neurologic event with manipulation of the patient's dialysis catheter, and the subsequent demonstration of a significant intracardiac right-to-left shunt, strongly suggest that air entry occurred during catheter manipulation, with subsequent paradoxical embolization.

Central venous catheters are commonly used for both temporary and semipermanent vascular access for hemodialysis. During dialysis, air detectors prevent air from being pumped into the venous system. At other times, air can potentially leak in during manipulation of the catheter, as well as if it becomes cracked, is capped improperly, or becomes inadvertently disconnected from a line. However, air embolism in such situations is rarely clinically significant because in the ab-

From the Renal Division, Department of Medicine, Brigham & Women's Hospital and Harvard Medical School, Boston, MA.

Received August 16, 1996; accepted in revised form October 29, 1996.

Address reprint requests to Alan S.L. Yu, MB, BChir, Renal Division, Department of Medicine, Brigham & Women's Hospital and Harvard Medical School, 75 Francis St, Boston, MA 02115.

*© 1997 by the National Kidney Foundation, Inc.
0272-6386/97/2903-0018\$3.00/0*

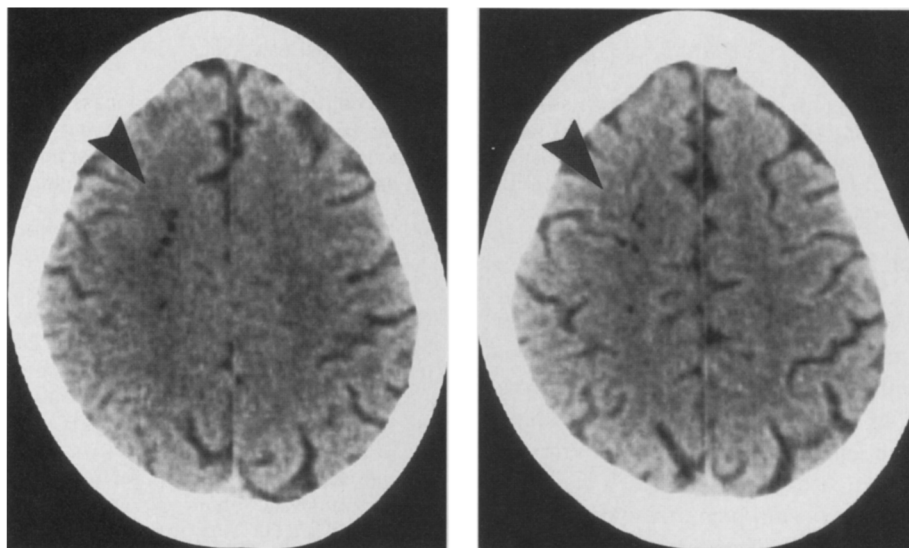


Fig 1. Noncontrast, computed tomography scan of the head. Serial 5-mm axial images at the level of the cerebral convexity show the presence of air deposits (indicated by arrowheads) in the right superior frontal lobe.

sence of a blood pump or pressurized infusion only a small amount of air is likely to enter the patient's veins, and is usually confined to the venous circulation. Animal studies have shown that at least 3 to 8 mL air/kg body weight is necessary to produce death from venous air embolism.¹⁻³

In contrast, minute amounts of air in the arterial system can have catastrophic consequences. For instance, the entry of 0.05 mL of air into the coronary artery of a dog can be fatal.² Venous air emboli can paradoxically enter the arterial circulation, most commonly through probe-patent foramen ovale, which can be found in at least 25% of the general population.⁴ The patent foramen ovale are anatomically patent but usually functionally closed, unless right atrial pressures exceed left atrial pressures, allowing right-to-left shunting. In the case reported, marked interatrial shunting was observed, presumably because pressures in the left heart chambers were abnormally low due to systemic hypotension. Paradoxical air emboli also have been rarely reported in the absence of any intracardiac septal defect.⁵⁻⁷ In such cases, transpulmonary shunting, by overcoming the finite capacity of the lung to filter air bubbles, has been postulated as the mechanism.

Paradoxical air embolism has been frequently

reported during surgical procedures performed in the sitting position, most notably during neurosurgery^{5,6,8} and hip surgery.⁹ However, only four cases of paradoxical air embolism from central venous catheters are reported in the literature. The causes of air embolism were disconnection of an administration set during intravenous fluid infusion in two of the cases,^{10,11} a crack in a micropore filter in one case,¹² and failure to replace the obturator in an introducer sheath in one case.⁷ In none of the cases was the catheters used for hemodialysis. The paucity of cases of paradoxical air emboli from dialysis catheters likely reflects the care exercised by dialysis staff in manipulation of these catheters because of their heightened awareness of air embolization, as well as an almost universal policy of avoiding use of such catheters for nondialysis purposes.

This case serves as a reminder to clinicians to exercise caution each time a central venous catheter is accessed. The policy at our institution is to not allow routine blood drawing through dialysis catheters, except by dialysis staff or in an emergency. If such a catheter needs to be accessed, the patient should be placed supine and the lines clamped firmly before opening the caps; Luer lock-type syringes should be used for the blood draw. In a patient with a central venous catheter, the occurrence of a sudden, focal neuro-

logic event should raise the suspicion of a paradoxical air embolus, particularly if they have a documented intracardiac septal defect, pulmonary hypertension, or profound systemic hypotension. Computed tomography of the head may be useful in making the diagnosis of cerebral air emboli. No specific treatment is available, but administration of 100% oxygen would seem prudent. While hyperbaric oxygen is useful in venous air embolism,¹³ its role in the treatment of cerebral air emboli is unknown.

REFERENCES

1. Harkins HN, Harmon PH: Embolism by air and oxygen: Comparative studies. *Proc Soc Exp Biol Med* 32:178-181, 1934
2. Durant TM, Long J, Oppenheimer MJ: Pulmonary (venous) air embolism. *Am Heart J* 33:269-281, 1947
3. Holt EP, Webb WR, Cook WA, Unal MO: Air embolism: Hemodynamics and therapy. *Ann Thorac Surg* 2:551-560, 1966
4. Hagen PT, Scholz DG, Edwards WD: Incidence and size of patent foramen ovale during the first 10 decades of life: An autopsy study of 965 normal hearts. *Mayo Clin Proc* 59:17-20, 1984
5. Clayton DG, Evans P, Williams C, Thurlow AC: Paradoxical air embolism during neurosurgery. *Anaesthesia* 40:981-989, 1985
6. Harrison GR: Paradoxical air embolus. *Anaesthesia* 41:763-764, 1986
7. Black M, Calvin J, Chan KL, Walley VM: Paradoxical air embolism in the absence of an intracardiac defect. *Chest* 99:754-755, 1991
8. Gronert GA, Messick JM, Cucchiara RF, Michenfelder JD: Paradoxical air embolism from a patent foramen ovale. *Anesthesiology* 50:548-549, 1979
9. Young C, Wright DJ: Paradoxical air embolism during hip surgery. *Anaesthesia* 41:1162-1163, 1986
10. Ponsky JL, Pories WJ: Paradoxical cerebral air embolism. *N Engl J Med* 284:985, 1971
11. Michel L, Poskanzer DC, McKusick KA, Nardi GL, Malt RA: Fatal paradoxical air embolism to the brain: Complication of central venous catheterization. *JPEN J Parenter Enteral Nutr* 6:68-70, 1982
12. Jacobsen WK, Briggs BA, Mason LJ: Paradoxical air embolism associated with a central total parenteral nutrition catheter. *Crit Care Med* 11:388-389, 1983
13. Baskin SE, Wozniak RF: Hyperbaric oxygenation in the treatment of hemodialysis-associated air embolism. *N Engl J Med* 293:184-185, 1975