

Frank W. Drislane  
Ay-Ming Wang

## Multifocal cerebral hemorrhage in eclampsia and severe pre-eclampsia

Received: 29 May 1996  
Received in revised form:  
10 September 1996  
Accepted: 26 September 1996

Presented in part at the annual meeting  
of the European Neurological Society,  
Barcelona, Spain, 25–29 June 1994

F. W. Drislane (✉)  
Department of Neurology, KS-479,  
Beth Israel Hospital,  
330 Brookline Avenue,  
Boston, MA 02215, USA  
Tel.: (617) 667-2395,  
Fax: (617) 667-7919

A.-M. Wang  
Department of Diagnostic Radiology,  
William Beaumont Hospital, Royal Oaks,  
Michigan, USA

**Abstract** Eclampsia and severe pre-eclampsia have often been associated with transient cortical blindness and with bilateral occipital CT hypodensities or increased T2-weighted signal abnormalities on MRI. Petechial hemorrhages have been reported pathologically and on MRI, but major hemorrhages have been infrequent. Symptoms and radiologic findings are usually reversible and the prognosis good. We reviewed the clinical and radiologic findings in four patients with eclampsia or severe pre-eclampsia who had multifocal cerebral hemorrhages found acutely on CT. Hemorrhages were usually bilateral and often in posterior areas. Two patients had hemor-

rhages discovered after earlier normal scans. One patient died, and others had prolonged neurologic residua including visuospatial and other cognitive deficits. The posterior CT and MRI abnormalities in eclampsia and severe pre-eclampsia are not always benign and reversible but may precede or include multifocal hemorrhages with long-term neurologic complications. The affected areas suggest an increased posterior circulation vulnerability to the hypertensive vascular disease of eclampsia.

**Key words** Eclampsia · Pregnancy · Computed tomography · Cerebral hemorrhage · Stroke

### Introduction

Cortical blindness and other visual symptoms have been recognized neurologic complications of eclampsia and severe pre-eclampsia for many years [8]. Whether performed for cortical blindness, for evaluation of seizures, or for other symptoms, many CT examinations have revealed hypodensities and MRI has shown areas of increased T2-weighted signal, particularly in occipital and other posterior circulation areas [5, 11, 30]. Hemorrhages have been relatively infrequent and often appear to reflect petechial hemorrhage [5, 11, 28].

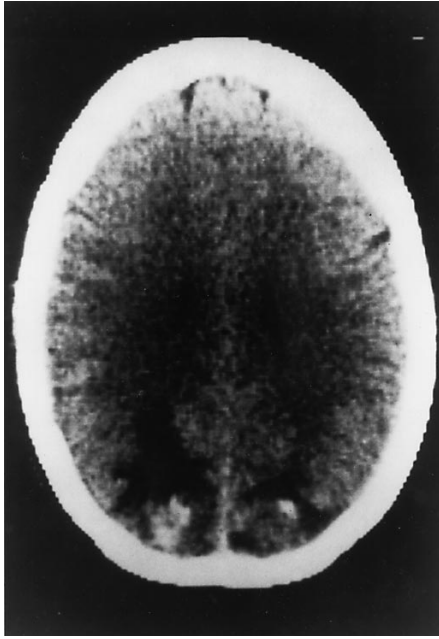
In almost all cases, clinical symptoms and signs, as well as the imaging abnormalities, have been transient [5, 27, 30]. We report four patients with eclampsia or severe pre-eclampsia whose scans showed multifocal hemorrhages, also with a posterior predominance, a group in which resolution of signs and symptoms was less favorable.

### Patients and methods

All abnormal CT scans performed urgently for neurologic complications in women with eclampsia or pre-eclampsia, as diagnosed in standard texts [8], were collected by a neuroradiologist (A.M.W.) over a 4-year period in a large urban teaching hospital with over 5,000 births each year. Five patients were identified. One with headache, blurred vision, and bilateral occipital hypodensities on CT (without hemorrhage) resolved clinically and on scan within a few days and was not included in the current series. Hospital records were reviewed on the other four patients, all of whom had been seen by neurologists during the acute illness.

#### Patient 1

A 28-year-old woman had a therapeutic abortion of her first pregnancy after 22 weeks, because she developed the HELLP syndrome (hemolysis, elevated liver enzymes and low platelets, a variant of pre-eclampsia [39]). She had a history of migraine, with scotomata, some in the previous week. In an emergency room 6 days later because of abdominal pain, she had a left body focal,

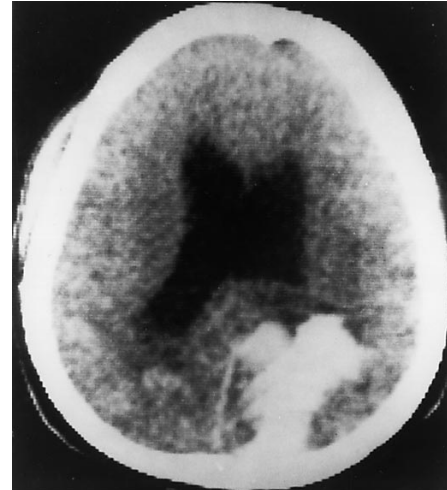


**Fig. 1** Patient 1. Bilateral occipital hemorrhages, right > left. (All photos: left side of brain on right)

and then generalized, seizure. Thereafter, she complained of a headache (completely unlike her previous headaches, she reported) and disturbed vision. The question of a conversion reaction was raised. CT and lumbar CSF were normal, and she was transferred to a referral hospital the next morning. The thrombocytopenia and most liver abnormalities had resolved. She had a blood pressure of 194/110 mmHg. Her optic fundi, pupils and eye movements were normal, but she had poor visual acuity and could not recognize objects in the left visual field. She described visual images as being disorganized, as if they were pieces of a jig-saw puzzle. She drew a clock with all the numbers on the right and could not recognize her error. She could read slowly and write well. CT (Fig. 1) the next day showed bilateral occipital hemorrhages, larger on the right. The visual recognition difficulties resolved after a week. A small, asymptomatic left visual field defect remained after 2 months.

#### Patient 2

A 32-year-old woman, 34 weeks into her fifth pregnancy, was admitted with a severe headache. She had a blood pressure of 200/110 mmHg, hyperreflexia with ankle clonus, and 4+ proteinuria. She had a vaginal delivery that day. The next day she became agitated and then stuporous, with bilateral sixth nerve palsies. No asymmetries were noted on her initial neurologic examination. The platelet count was  $23 \times 10^9/l$  and the bleeding time over 15 min; a fibrinogen level was 5.5 g/l. CT (Fig. 2) showed bilateral parieto-occipital hemorrhages, larger on the left, and ventricular dilatation without intraventricular hemorrhage. After correction of the coagulopathy she received a ventriculo-peritoneal shunt for the hydrocephalus which was thought to contribute to her confusion. Complications in the next month included a shunt replacement because of obstruction, deep vein thrombosis requiring a vena cava filter, and hepatitis thought to be due to phenytoin. After 1 month she was inattentive and confused. She had poor short- and long-term memory and poor insight into her problems. She neglected

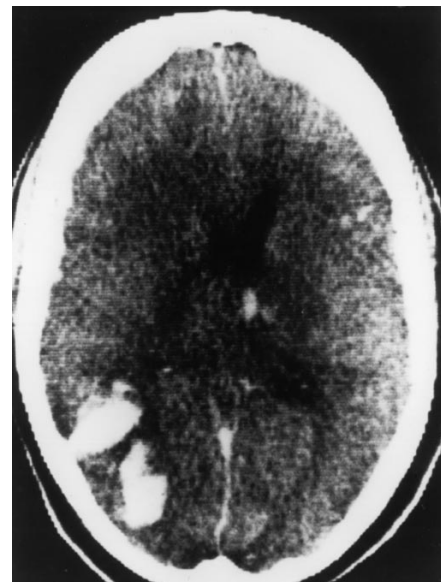

**Fig. 2** Patient 2. Bilateral parieto-occipital hemorrhages, left > right. Ventricular dilatation

objects in the right visual field and neglected somatosensory stimuli on the right. She had a mild right central facial weakness and was ataxic bilaterally, more so on the right. After 3 months, the poor memory, asymmetric ataxia and neglect persisted. She had such severe cognitive and visuospatial deficits that she was unable to care for herself or her children.

#### Patient 3

A 34-year-old woman presented with severe abdominal pain after 34 weeks of an uneventful pregnancy; she had had one earlier child and one therapeutic abortion. She had a blood pressure of 240/140 mmHg, hyperreflexia, and 4+ proteinuria. She had a generalized seizure, and was treated with magnesium and hydralazine. Laboratory studies indicated disseminated intravascular coagulation



**Fig. 3** Patient 3. Right parieto-temporo-occipital, right subdural, and smaller left frontal and subependymal hemorrhages

(DIC). She received cryoprecipitate and platelets. Within 3 h she developed retinal hemorrhages and became comatose. She underwent a cesarean section because of fetal distress. Postoperatively, she remained comatose, flaccid and areflexic, with fixed, dilated pupils and absent corneal reflexes; there was no ocular response to cold caloric stimulation. CT (Fig. 3) showed a large right parietal-temporal-occipital hemorrhage, small left frontal and subependymal hemorrhages, and a right subdural hematoma. Two electroencephalograms showed electrocerebral silence; brain scans showed no cerebral blood flow. Mechanical ventilation was halted, and she was pronounced dead. Autopsy showed acute tubular necrosis plus renal, gastric and subendocardial hemorrhages. She had several small focal subarachnoid hemorrhages (SAH), a large intracerebral hemorrhage in the right occipital, temporal, and parietal lobes, and several smaller hemorrhages. The brain was swollen, with moderate uncal herniation on the right. No thromboses were seen.

#### Patient 4

A 21-year-old woman, 37 weeks into her second pregnancy, had a blood pressure of 140/100 mm Hg and had had edema for 3 weeks. Within hours of an urgent cesarean section (for fetal distress) she had three generalized seizures. She had a blood pressure of 160/110 mm Hg and a left subhyaloid hemorrhage. Except for lethargy, her neurologic examination was normal. CT was normal a few hours after the seizure. A lumbar puncture had an opening pressure of 420 mm water, with  $1600 \times 10^6$  RBC/l and a total protein of 1.8 g/l. Fibrinogen level was 4.7 g/l. Platelet count was  $378 \times 10^9$ /l. A bilateral carotid angiogram the next day showed a possible filling defect suggestive of a thrombosis in the posterior portion of the superior sagittal sinus. CT the following day showed a small left frontal hemorrhage and a small periaxial SAH (not shown). She developed diabetes insipidus, which improved with desmopressin. A week later she was still confused, though better; hemorrhages were no longer evident on CT. Two months later she had bilateral ptosis but was otherwise healthy, and she returned to work.

## Results

All four patients had severe pre-eclampsia, with proteinuria and blood pressure of at least 160/110 mmHg. All had altered mental status or visual symptoms; patients 1 and 2 had headaches. All but patient 2 went on to have seizures and, thus, eclampsia.

All four patients had scans showing at least two sites of hemorrhage, with several hemorrhages in posterior cerebral areas; none had unilateral or solely anterior hemorrhages. Patients 1 and 2 had bilateral occipital or parieto-occipital hemorrhages, and the patient with DIC had the most prominent hemorrhage posteriorly. Two patients (1 and 4) had normal scans initially, with hemorrhages visible on subsequent studies.

Neurologic residua and medical complications were common in these patients. Of the three survivors two had mild neuro-ophthalmologic deficits (ptosis or a visual field loss) even months later. The other patient had several medical complications, persistent confusion and incapacitating cognitive deficits, and prolonged disability.

## Discussion

Pre-eclampsia includes arterial hypertension, proteinuria and edema in the second half of pregnancy; with seizures this becomes eclampsia [8]. Severe pre-eclampsia complicates a small percentage of pregnancies, and eclampsia under 0.1%, but they contribute to a large portion of the cerebrovascular morbidity and mortality in pregnancy [8, 33]. More fleeting morbidity frequently includes cortical blindness, usually resolving after hours to days [3, 9, 22].

There are many reports of CT and MRI abnormalities in pre-eclampsia and eclampsia, not only with cortical blindness but also with seizures and other symptoms [5, 11, 25, 27, 30, 32]. Almost all show CT hypodensities or T2-weighted signal intensities on MRI, without hemorrhage, suggestive of edema [4–6, 27, 32] or ischemia [12, 15, 22]. With angiographic evidence, some ischemic lesions have been attributed to vasospasm [35, 40].

CT and MR findings are similar though abnormalities are better delineated and often more numerous on MRI [27, 32]. MRI may show subtle abnormalities, even with normal CT findings [11]. Still, CT may be more appropriate and available in urgent studies to look for acute intracranial hemorrhage [11, 24]. Our patients had hemorrhages diagnosed by CT alone because they were done urgently.

Interestingly, as MRI is applied to more cases, the small abnormalities interpreted as petechial hemorrhage [11] more closely approximate the initial reports of the pathology in eclampsia [34]. MRI discerns smaller, often asymptomatic, abnormalities, while it is likely that urgent CT shows more dramatic and clinically significant abnormalities when abnormal.

Hemorrhages have been uncommon in these patients, and most have been petechial or other small hemorrhages [11]. One patient with a subependymal hemorrhage had a memory deficit that resolved after 3 months [2]. One with a parenchymal hemorrhage died [5]. Lesser hemorrhages often resolved [40]. Patients with large intraventricular hemorrhages fared worse [25]. Of 43 women with neurologic complications due to eclampsia or severe pre-eclampsia in one series, four of the seven fatal cases were due to hemorrhage, especially intraventricular hemorrhage [28]. Hemorrhage may also lead to hydrocephalus, as in our patient 2, indicating greater need for reassessment and treatment in these patients. Our patients with hemorrhages had more persistent or even permanent neurologic sequelae.

Most scan abnormalities resolve within days [5, 27]. In 31 studies of identifiable CT or MRI abnormalities in patients with eclampsia or pre-eclampsia [2–7, 9–12, 14–16, 18–23, 25–32, 35–37, 40], 63 patients had follow-up detailed; 54 (86%) resolved, and 5 had minimal abnormalities. Two had residual strokes [23, 40], and a few with hemorrhages had persistent deficits or died. Though most scan abnormalities resolve, one report notes typical occip-

ital lesions leading to bilateral cerebral hemorrhages in the same areas within several hours [29]. This seems likely to have been the case in our patient 1, as well. Lesions that are initially ischemic (or inapparent) may become hemorrhagic; concomitant coagulopathies may facilitate such hemorrhagic transformations.

Two of our patients with initially normal scans (1 and 4) went on to have hemorrhages. Thus, particularly for detecting hemorrhagic lesions, repeat scanning should be considered with a change in the clinical condition.

In the 31 reports of CT and MRI abnormalities in patients with eclampsia and severe pre-eclampsia in which the localization of lesions was specified, 138 patients were described and 83 (60%) had primarily posterior circulation abnormalities. These were usually bilateral occipital, posterior parietal, and temporal, and often symmetric. Many scans were prompted by visual symptoms. Even eliminating the 20 patients selected for radiologic studies because of cortical blindness (all of whom had posterior abnormalities) 63 of 118 (53%) had abnormalities predominantly in posterior circulation areas; most of the remainder had multifocal abnormalities or diffuse

white matter changes. Brain stem involvement was also relatively common. Very few had more anterior focal lesions.

All of these studies indicate that the posterior circulation suffers disproportionately in apparently systemic illnesses such as eclampsia and pre-eclampsia. It has been suggested that this is due to a selective increase in blood vessel permeability and loss of autoregulation in the posterior circulation during relative or absolute hypertension [30]. Schwartz et al. [32] detailed the same findings in other hypertensive conditions and noted that the posterior circulation has lesser sympathetic innervation of the vasculature than does the carotid system [13] and that sympathetic innervation protects against the effects of hypertension [1]. Very similar CT and MRI abnormalities are found in patients with hypertensive encephalopathy [17, 32, 38], after seizures [41] and in other illnesses [19]. The clinical and radiologic abnormalities in eclampsia and severe pre-eclampsia, in this and other reports, support a differential vulnerability of posterior circulation blood vessels to hypertension in eclampsia and other vascular diseases.

## References

1. Beausang-Linder M, Bill A (1981) Cerebral circulation in acute arterial hypertension – protective effects of sympathetic nervous activity. *Acta Physiol Scand* 111:193–199
2. Beck DW, Menezes AH (1981) Intracerebral hemorrhage in a patient with eclampsia. *JAMA* 246:1442–1443
3. Beeson JH, Duda EE (1982) Computed axial tomography scan demonstration of cerebral edema in eclampsia preceded by blindness. *Obstet Gynecol* 60:529–532
4. Brown CEL, Purdy P, Cunningham FG (1988) Head computed tomographic scans in women with eclampsia. *Obstet Gynecol* 159:915–920
5. Colosimo C, Fileni A, Moschini M, Guerrini P (1985) CT findings in eclampsia. *Neuroradiology* 27:313–317
6. Coughlin WF, McMurdo SK, Reeves T (1989) MR imaging of postpartum cortical blindness. *J Comput Assist Tomogr* 13:572–576
7. Crawford S, Varner MW, Digre KB, Servais G, Corbett JJ (1987) Cranial magnetic resonance imaging in eclampsia. *Obstet Gynecol* 70:474–477
8. Cunningham FG, MacDonald PC, Gant NF (1989) Hypertensive disorders in pregnancy. In: Williams obstetrics. Appleton & Lange, Norwalk, Conn, pp 653–694
9. Cunningham FG, Fernandez CO, Hernandez C (1995) Blindness associated with preeclampsia and eclampsia. *Am J Obstet Gynecol* 172:1291–1298
10. Dierckx I, Appel B (1989) MR findings in eclampsia. *AJNR* 10:445
11. Digre KB, Varner MW, Osborn AG, Crawford S (1993) Cranial magnetic resonance imaging in severe pre-eclampsia vs eclampsia. *Arch Neurol* 50:399–406
12. Duncan R, Hadley D, Bone I, Symonds EM, Worthington BS, Rubin PC (1989) Blindness in eclampsia: CT and MR imaging. *J Neurol Neurosurg Psychiatry* 52:899–902
13. Edvinsson L, Owman C, Sjoberg N-O (1976) Autonomic nerves, mast cells, and amine receptors in human brain vessels. A histochemical and pharmacological study. *Brain Res* 115:377–393
14. Fredriksson K, Lindvall O, Ingemarsson I, Astedt B, Cronqvist S, Holtas S (1989) Repeated cranial computed tomographic and magnetic resonance imaging scans in two cases of eclampsia. *Stroke* 20:547–553
15. Gaitz JP, Bamford CR (1982) Unusual computed tomographic scan in eclampsia. *Arch Neurol* 39:66
16. Grimes DA, Ekbladh LE, McCartney WH (1980) Cortical blindness in pre-eclampsia. *Int J Gynaecol Obstet* 17: 601–603
17. Hauser RA, Lacey DM, Knight MR (1988) Hypertensive encephalopathy. Magnetic resonance imaging demonstration of reversible cortical and white matter lesions. *Arch Neurol* 45:1078–1083
18. Herzog TJ, Angel OH, Karram MM, Evertson LR (1990) Use of magnetic resonance imaging in the diagnosis of cortical blindness in pregnancy. *Obstet Gynecol* 76:980–982
19. Hinchey J, Chaves C, Appignani B, Breen J, Pao L, Wang A, Pessin MS, Lamy C, Mas J-L, Caplan LR (1996) A reversible posterior leukoencephalopathy syndrome. *N Engl J Med* 334:494–500
20. Horn EH, Filshie M, Kerslake RW, Jaspas T, Worthington BS, Rubin PC (1990) Widespread cerebral ischemia treated with nimodipine in a patient with eclampsia. *BMJ* 301:794
21. Kirby JC, Jaindl JJ (1984) Cerebral CT findings in toxemia of pregnancy. *Radiology* 151:114
22. Lau SPC, Chan FL, Yu YL, Woo E, Huang CY (1987) Cortical blindness in toxemia of pregnancy: findings on computed tomography. *Br J Radiol* 60: 34–349
23. Lewis LK, Hinshaw DB, Will AD, Hasso AN, Thompson JR (1988) CT and angiographic correlation of severe neurologic disease in toxemia of pregnancy. *Neuroradiology* 30:59–64

24. Mattle HP, Edelman RR, Schroth G, O'Reilly GV (1996) Spontaneous and traumatic hemorrhage. In: Edelman RR, Hesselink JR, Zlatkin MB (eds) *Clinical magnetic resonance imaging*. Saunders, Philadelphia, pp 652–702
25. Milliez J, Dahoun A, Boudraa M (1990) Computed tomography of the brain in eclampsia. *Obstet Gynecol* 75:975–980
26. Naheedy MH, Biller J, Schiffer M, Azar-Kia B, Gianopoulos J, Zarandy S (1985) Toxemia of pregnancy: cerebral CT findings. *J Comput Assist Tomogr* 9:497–501
27. Raroque HG, Orrison WW, Rosenberg GA (1990) Neurologic involvement in toxemia of pregnancy: reversible MRI lesions. *Neurology* 40:167–169
28. Richards A, Graham D, Bullock R (1988) Clinicopathological study of neurological complications due to hypertensive disorders of pregnancy. *J Neurol Neurosurg Psychiatry* 51:416–421
29. Salerni A, Wald S, Flanagan M (1988) Relationships among cortical ischemia, infarction, and hemorrhage in eclampsia. *Neurosurgery* 22:408–410
30. Sanders TG, Clayman DA, Sanchez-Ramos L, Vines FS, Russo L (1991) Brain in eclampsia: MR imaging with clinical correlation. *Radiology* 180:475–478
31. Schwaighofer BW, Hesselink JR, Healy ME (1989) MR demonstration of reversible brain abnormalities in eclampsia. *J Comput Assist Tomogr* 13:310–312
32. Schwartz RB, Jones KM, Kalina P, Bajakian RL, Mantello MT, Garada B, Holman BL (1992) Hypertensive encephalopathy: findings on CT, MR imaging, and SPECT imaging in 14 cases. *AJR* 159:379–383
33. Sharshar T, Lamy C, Mas JL for the Stroke in Pregnancy Study Group (1995) Incidence and causes of strokes associated with pregnancy and puerperium. A study in public hospitals of Ile de France. *Stroke* 26:930–936
34. Sheehan HB, Lynch JB (1973) Pathology of toxemia of pregnancy. *Williams and Wilkins, Baltimore*, pp 524–584
35. Trommer BL, Homer D, Mikhael MA (1988) Cerebral vasospasm and eclampsia. *Stroke* 19:326–329
36. Vandenplas O, Dive A, Dooms G, Mahieu P (1990) Magnetic resonance evaluation of severe neurological disorders in eclampsia. *Neuroradiology* 32:47–49
37. Waldron RL, Abbot DC, Vellody D (1985) Computed tomography in preeclampsia-eclampsia syndrome. *AJNR* 6:442–443
38. Weingarten K, Barbut D, Filippi C, Zimmerman RD (1994) Acute hypertensive encephalopathy: findings on spin-echo and gradient-echo MR imaging. *AJR* 162:665–670
39. Weinstein L (1985) Preeclampsia/eclampsia with hemolysis, elevated liver enzymes, and thrombocytopenia. *Obstet Gynecol* 66:657–660
40. Will AD, Lewis KL, Hinshaw DB, Jordan K, Cousins LM, Hasso AN, Thompson JR (1987) Cerebral vasoconstriction in toxemia. *Neurology* 37:1555–1557
41. Yaffe K, Ferriero D, Barkovich AJ, Rowley H (1995) Reversible MRI abnormalities following seizures. *Neurology* 45:104–108