



ELSEVIER

Brain & Development 19 (1997) 148–151



Case report

Acute confusional migraine and migrainous infarction in childhood

Atsuo Nezu^{a,*}, Seiji Kimura^a, Noriyuki Ohtsuki^a, Miyabi Tanaka^a, Shigeo Takebayashi^b

^aDepartment of Pediatrics, Urafune Hospital of Yokohama City University, 3–46 Urafune-cho, Minami-ku, Yokohama 232, Japan

^bDepartment of Radiology, Yokohama City Kowan Hospital, Yokohama, Japan

Received 15 March 1996; accepted 4 September 1996

Abstract

We report two children with acute confusional migraine (ACM) and another with migrainous infarction (MI), aged 7–12 years. There was a family history of migraine in all patients. The patients, who were all right-handed, all manifested sudden onset of consciousness disturbance and other neurological deficits as the first aura in their life. The symptoms in all cases almost completely resolved spontaneously within 24 h, but transient occipital slowing on EEG with laterality corresponding to the side of migrainous origin lasted more than 24 h. In the cases of ACM in the critical phase, although MRI and MR angiography showed no abnormal findings, IMP-SPECT performed within 48 h of migraine attacks revealed a regional change in cerebral blood flow, which in one particular case demonstrated hypoperfusion in the left posterior cerebral artery (PCA) territory. Therefore, although ACM was diagnosed clinically by exclusion, SPECT was thought helpful for the diagnosis of ACM. We speculated that transient hypoperfusion affecting the dominant-sided PCA territory involving the medial temporal structures was responsible for the confusion with amnesia in ACM, in contrast to the lack of confusion or amnesia in the case of MI showing cystic encephalomalacia in the right thalamic and hippocampal regions. © 1997 Elsevier Science B.V.

Keywords: Acute confusional migraine; Migrainous infarction; SPECT; MR angiography

1. Introduction

Transient abrupt alteration of consciousness in childhood is most commonly caused by non-convulsive epileptic status, and is rarely associated with drug intoxication, encephalitis, head trauma, toxic metabolic encephalopathies, or hysteria attack. Acute confusional migraine (ACM), reported by Gascon and Barlow, is considered a much rarer cause in childhood [1–3]. In spite of the relatively high prevalence of migraine in children which ranges from 1.1 to 5.0%, serious auras such as altered consciousness, paresthesias and paresis are rarely seen, since more than 90% of migraine in childhood comprises common migraine [4–6]. Migrainous infarction (MI) is likewise uncommon in children [7,8]. Riikonen and Santavuori reported that migrainous stroke was diagnosed in six of 42 children suffering from arterial stroke [9]. For the diagnosis of MI, it is important to exclude other causes

such as Moyamoya disease, cerebral angiitis, antiphospholipid syndrome, and mitochondrial myopathy, encephalopathy, lactic acidosis and stroke-like episodes (MELAS). In this paper, although ACM was diagnosed by exclusion, the diagnostic value of EEG, MRI, MR angiography (MRA), and single-photon emission computed tomography (SPECT) was evaluated in the critical phase of ACM; the genesis of confusion with amnesia in ACM is also discussed.

2. Methods

EEG was performed with scalp electrodes according to the international 10–20 system. Both MRI and MRA were simultaneously carried out on a Signa 1.5 Tesla system (General Electric, USA) without contrast enhancement. Spin-echo T₁-weighted images (TR 440 ms, TE 15 ms) and T₂-weighted images (TR 2500 ms, TE 110 ms) were obtained in the axial and coronal planes. MRA was performed using both time of flight (TR 28 ms, TE 8 ms) and

* Corresponding author. Tel.: +81 45 2615656; fax: +81 45 2433886.

phase contrast (TR 24 ms, TE 8 ms) methods. SPECT was carried out using Multi-SPECT (Siemens, Germany). A peripheral arm vein was injected with 111 MBq (3 mCi) ^{123}I -iodoamphetamine (IMP), and data acquisition was started 20 min after injection. Images were acquired into a 128×128 matrix with 3.3 mm slice thickness. Images were analyzed qualitatively for defects in IMP uptake.

3. Case reports

3.1. Case 1

A 7-year-old boy complained of minimal pain behind the ears. One hour later, confusion suddenly developed following visual blurring and vomiting, and he was admitted to our hospital. Physical findings on admission consisted of pallor, confusional disorientation, and mild signs of amnesia. Severe pulsating headache in the occipital area developed 3 h after the onset. The next morning, he was completely oriented, and no symptoms other than slight headache were present. EEG on admission revealed posterior slowing with left-sided dominance. MRI and MRA, which were simultaneously performed within 24 h of the onset, revealed no abnormal findings. ^{123}I -IMP-SPECT carried out within 48 h of the onset showed decreased cerebral blood flow (CBF) in the left posterior splenium region (Fig. 1A). No further headache recurred over the following 6 months since starting dihydroergot at a daily dose of 1 mg.

3.2. Case 2

A 12-year-old girl developed abrupt onset of photophobia, confusion, aphasia and right hemiplegia, followed by severe pulsating headache in the left temporal region. Aphasia and right hemiplegia subsided 2 h after the onset. Although she manifested confusion and amnesia on admission, they also improved spontaneously 6 h after the onset. EEG performed the next day demonstrated left occipital slowing (Fig. 2). MRI and MRA performed within 24 h revealed no abnormal findings. She was treated with propranolol at a daily dose of 10 mg. Nevertheless, she experienced two occurrences of aura consisting of numbness of the left hand and left-sided common migraine over the following month. ^{123}I -IMP-SPECT carried out two days after the last attack of common migraine showed hyperperfusion of the left temporal region (Fig. 1B). Dihydroergot was added at a daily dose of 1 mg, and there was no recurrence of migrainous episodes over the next 18 months.

3.3. Case 3

A 7-year-old girl, who continued to suffer from common migraine occurring almost twice a week over 6 months, developed a severe pulsating headache of the right temporal region accompanied by vomiting and drowsiness, starting in the evening. The next morning, she noticed left hemiparesis despite relief of headache. She promptly underwent CT scan of the head (Fig. 3A

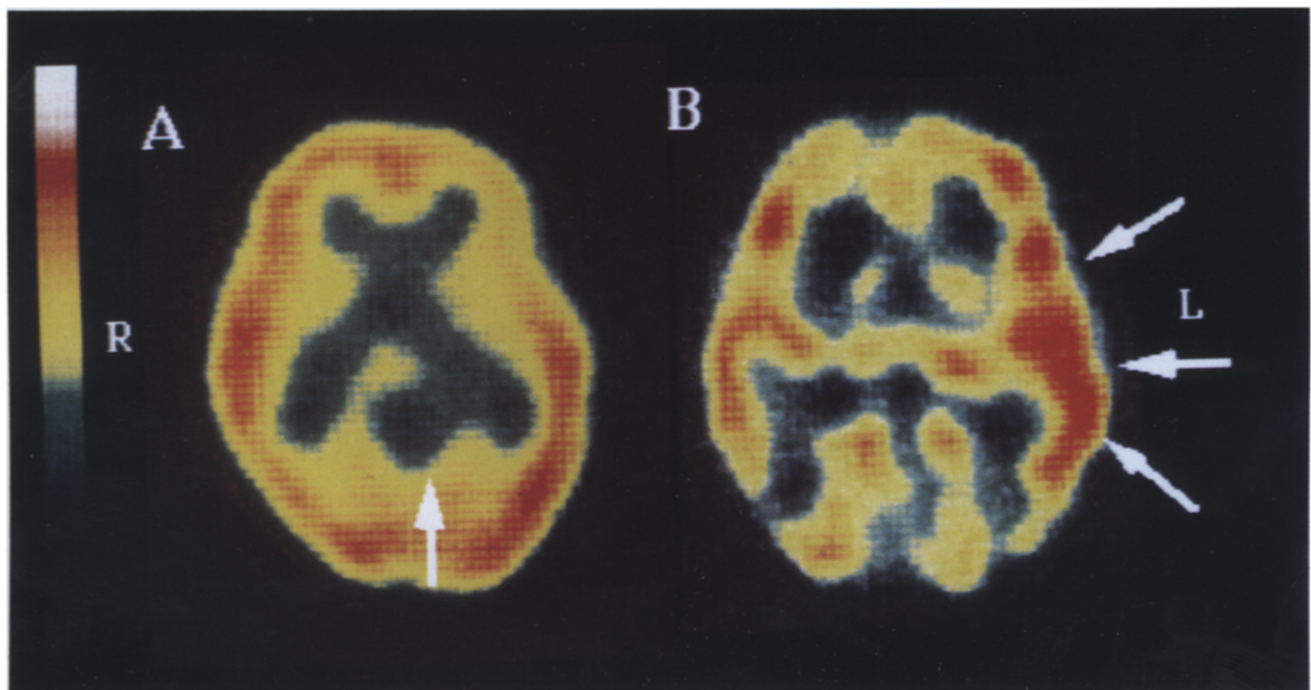


Fig. 1. Early images of ^{123}I -IMP SPECT. A: Case 1 shows decreased cerebral blood flow (CBF) in the left part of the splenium of the corpus callosum (arrow). B: In case 2, CBF is increased in the left temporal region (arrows).

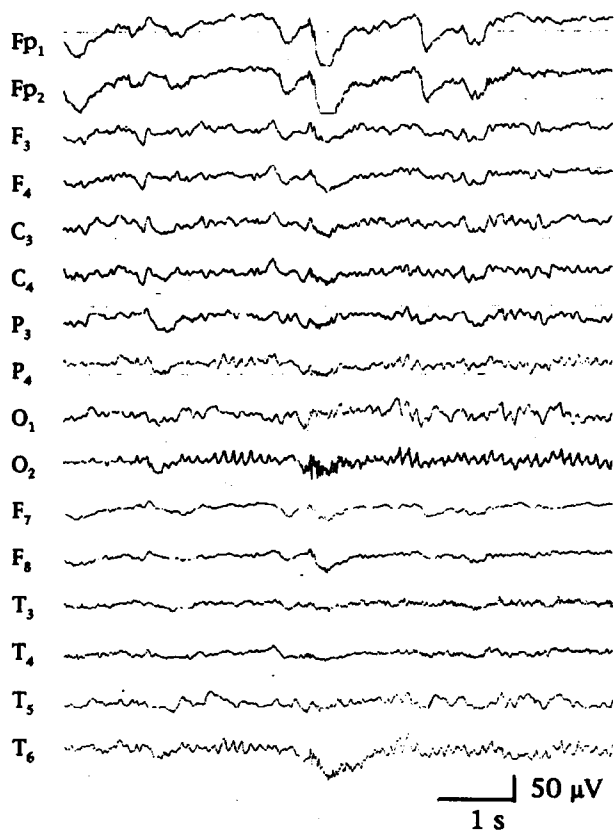


Fig. 2. EEG of case 2 displays slowing activities in the left posterior areas.

and Fig. 3B), but no lesions were detected. Hemiparesthesia abated spontaneously the next day, but numbness on the left hand lasted 2 more days. She was referred to our hospital 3 days after the onset. EEG showed occipital slowing with right-sided dominance. Infarction in the right thalamic and hippocampal regions was detected on MRI performed a week after the onset (Fig. 3C and Fig. 3D). MRA showed no abnormal findings. ^{123}I -IMP-SPECT was also performed a week after the onset and showed reduced CBF in the same areas as the lesions revealed by MRI. She was treated with propranolol at a daily dose of 5 mg, and experienced no recurrence of episodes during the following 12 months.

All cases were right-handed. No cases had previously experienced a transient stroke, or an attack of migraine with aura or epilepsy. There was a family history of migraine in all cases. Blood and urine examinations including levels of lactate, pyruvate and amino acids yielded no abnormal results in all cases. There was no evidence of hypercoagulable state, and anti-cardiolipin antibody was negative.

4. Discussion

The characteristics of migraine attacks in childhood seem to differ somewhat from those in adults. Autonomic

symptoms such as nausea, pallor, and abdominal pain are more pronounced, while auras, especially paresthesias and motor paresis, are rarely seen, since migraine with aura comprises less than 10% of migraine in childhood [5,6,10,11]. On the other hand, although drowsiness is occasionally noted as a manifestation of aura in adults, most patients with ACM characterized by auras of confusion, disorientation, and amnesia are reported to be younger than 21 years of age [2,3]. It was also reported that ACM can occur as the initial episode of aura. Cases 1 and 2, who had no history of migraine, were also admitted with the first auras in their life of confusion and amnesia preceding severe pulsating headache. Although case 3 had suffered from common migraine over the previous 6 months, infarction lesions developed during the initial aura, and a relationship between migraine attack and infarction was strongly suspected. The clinical diagnoses of ACM and MI were made by exclusion after the symptoms resolved spontaneously with sleep within 24 h, since these episodes developed as the initial manifestation of migraine with aura and the criteria of migraine with aura

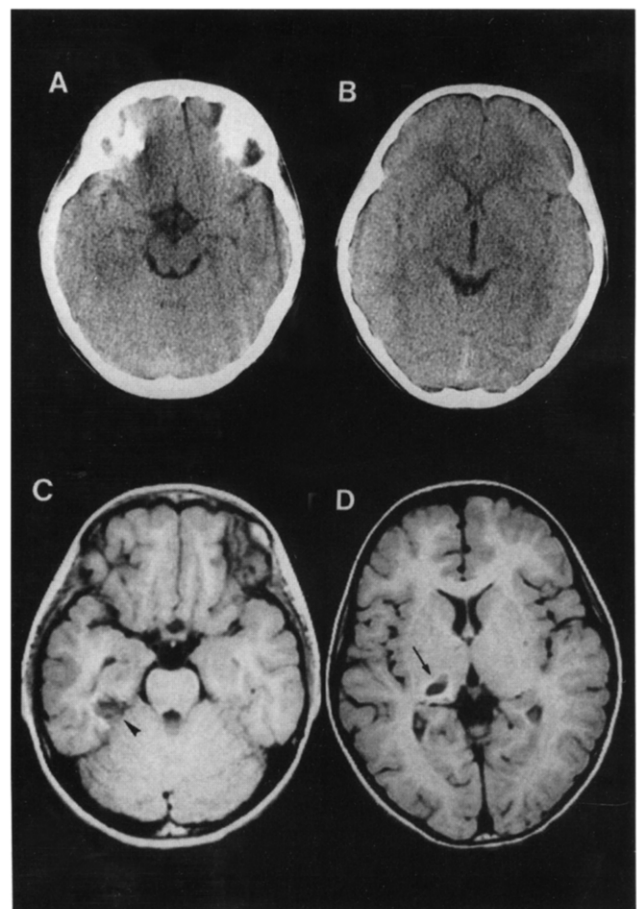


Fig. 3. Axial CT scans in the critical phase and MR images a week after the onset in case 3. The CT scans (A, B) reveal no abnormality. Infarction in the right hippocampal region (C, arrow head) and the right thalamus (D, arrow), both of which were fed by the posterior cerebral artery, is seen in the T₁-weighted, 440/15, axial images.

of the International Headache Society were not completely fulfilled because of the absence of repeated attacks.

MI is defined as cerebral infarction consequently occurring during the course of a prolonged aura. To exclude cerebral infarction due to other causes coexisting with migraine attack, thorough investigation is necessary [7]. Several disorders associated with a hypercoagulable state such as vasculitis, anticoagulant deficiencies, MELAS, Moyamoya disease, fibromuscular dysplasia, and cardiac diseases may be present, although the cause of infarction in childhood is unknown in about 50% of cases [9]. During the postictal phase in case 3, MRA and SPECT showed no additional specific findings, but were helpful for excluding expanding vasculopathies.

In the clinical evaluation of ACM in the critical phase, visual aura and left-sided occipital slowing on EEG associated with migraine attacks, although not specific findings, suggested transient ischemic change in the left posterior cerebral artery (PCA) territory [12,13]. For example, generalized seizures may be followed by transient confusion with amnesia accompanied by occipital slowing. However, in the present cases, the period of continued EEG slowing despite neurological improvement was considered more prolonged than that in patients with epileptic disorders. MRA was not able to detect laterality in the size of the middle or posterior cerebral artery even within 24 h of the onset. SPECT seemed to show the most meaningful findings, although SPECT examinations were unfortunately not performed with a consistent temporal relationship. The finding in case 1 of a regional decrease in CBF in the left part of the splenium of the corpus callosum during the critical phase, which suggested the relationship of ACM with transient focal ischemic change, was more diagnostic than the findings in case 2. The finding in case 2, of hyperperfusion in the left temporal region after an episode not of ACM but of common migraine, was consistent with the findings in common migraine and suggested that case 2 had a migrainous constitution [14–16].

Although the pathogenic mechanism of ACM is inconclusive, Sheth et al. reported the relationship of ACM to transient global amnesia [3]. Since ictal SPECT studies had not been reported in ACM, they speculated that bilateral hypoperfusion affecting the occipital and hippocampal regions is causative. The present cases of ACM also manifested not only confusion but also amnesic syndrome, which is characterized by an inability to acquire new memories and some degree of retrograde amnesia but with adequate intellectual function; ACM in case 1 evaluated with SPECT performed in the critical phase may especially be linked to transient ischemic impairment in the dominant-sided PCA territory involving the medial tem-

poral structures. In contrast, the case of MI showing cystic encephalomalacia in the right thalamic and hippocampal regions had no amnesic syndrome. Since amnesia due to left PCA occlusion is considered to be more commonly accompanied by confusion than that caused by other focal cerebral lesions responsible for transient amnesic syndrome [17], we hypothesized that confusion with amnesia in ACM originated from the involvement of the left PCA territory and not the right PCA territory. All cases were very responsive to low-dose prophylactic treatment. In conclusion, SPECT findings in the critical phase were considered helpful for the diagnosis of ACM.

References

- [1] Gascon G, Barlow C. Juvenile migraine presenting as an acute confusional state. *Pediatrics* 1970; 45: 628–635.
- [2] D'Cruz OF, Walsh DJ. Acute confusional migraine: case series and review of literature. *Wis. Med. J.* 1992; 91: 130–131.
- [3] Sheth RD, Riggs JE, Bodensteiner JB. Acute confusional migraine: variant of transient global amnesia. *Pediatr. Neurol.* 1995; 12: 129–131.
- [4] Wöber BC, Wöber C, Karwautz A et al. Diagnosis of headache in childhood and adolescence: a study in 437 patients. *Cephalalgia* 1995; 15: 13–21.
- [5] Ferrari P, Incorpora G, Cocuzza M et al. Multicenter study of childhood headache. *Childs Nerv. Syst.* 1994; 10: 455–457.
- [6] Lanzi G, Balottin U, Borgatti R. A prospective study of juvenile migraine with aura. *Headache* 1994; 34: 275–278.
- [7] Wöber BC, Wöber C, Karwautz A et al. Migraine and stroke in childhood and adolescence. *Cephalalgia* 1995; 15: 26–30.
- [8] Leboreiro FA, Leboreiro IE, Moura RM. Striatocapsular infarction in childhood. Report of 4 cases. *Arq. Neuropsiquiatr.* 1994; 52: 396–401.
- [9] Riikonen R, Santavuori P. Hereditary and acquired risk factors for childhood stroke. *Neuropediatrics* 1994; 25: 227–233.
- [10] Chu ML, Shinnar S. Headaches in children younger than 7 years of age. *Arch. Neurol.* 1992; 49: 79–82.
- [11] Nevo Y, Kramer U, Rieder GI et al. Clinical categorization of 312 children with chronic headache. *Brain Dev.* 1994; 16: 441–444.
- [12] Farkas V, Kohlheb O, Benninger C et al. Comparison of the EEG background activity of epileptic children and children with migraine. *Epilepsy Res. Suppl.* 1992.
- [13] Seri S, Cerquiglini A, Guidetti V. Computerized EEG topography in childhood migraine between and during attacks. *Cephalalgia* 1993; 13: 53–56.
- [14] Spina A, Damato V, Losito R et al. Brain SPECT and migraine in childhood. *Acta Neurol. (Napoli)* 1992; 14: 10–14.
- [15] Sianard GJ, Milet J, Ghuysen V et al. Increased parasellar activity on gallium SPECT is not specific for active cluster headache. *Cephalalgia* 1994; 14: 132–133.
- [16] Colamussi P, Giganti M, Cittanti C et al. Significance and usefulness of SPECT with Tc-99m HMPAO in the diagnosis of hemisphericity with aura. *Radiol. Med.* 1995; 89: 324–329.
- [17] Benson DF, Marsden CD, Meadows JC. The amnesic syndrome of posterior cerebral artery occlusion. *Acta Neurol. Scand.* 1974; 50: 133–145.