

Cumhur Ertekin
Özgül Ekmekçi
Neşe Çelebisoy

Le fou rire prodromique

Received: 9 July 1996
Received in revised form:
12 November 1996
Accepted: 10 December 1996

Sirs: “Fou rire prodromique” was first described by Féré in 1903 as an attack of uncontrollable laughter, which begins abruptly and is followed after several hours by hemiplegia [2]. This interesting type of stroke onset has rarely been reported [4–7]. On the other hand, pathological laughter and crying, caused by bilateral and or diffuse lesions, is widely recognized as a symptom occurring in various brain disorders such as vascular pseudobulbar palsy, amyotrophic lateral sclerosis and multiple sclerosis [3]. We have had the opportunity to examine and follow up three stroke patients with fou rire prodromique.

Case 1: A 57-year-old man with a history of hypertension and diabetes mellitus was admitted to hospital because of a right-sided weakness, which followed an attack of unmotivated laughter, lasting about an hour. Far from feeling happy he was anxious about what was going on at that time. On admission, he was conscious and fully oriented. There was a mild right hemiparesis without speech disorder. The plantar response was extensor on the right side. The sensory examination was normal and the cranial nerves were intact. MRI revealed an acute left pontine infarct. The hemiparesis on the right side recovered completely in 3 days. Uncontrollable attacks of laughter lasting 15–20 min were repeated a few times in that period. Two weeks after the onset of the stroke, typical pathological laughter and crying attacks

developed, which he could not resist and which were independent of his emotional status. There was no clinical sign of depression. A year later, he was admitted to the neurology clinic for the second time because of a left-sided hemiparesis, again with fou rire prodromique. This time there was a left hemiparesis with bilateral extensor plantar responses. On MRI, a subacute infarct at the head of the caudate nucleus in addition to a left pontine old infarct was detected. During the follow-up period, features of suprabulbar palsy were manifested with continuing attacks of pathological laughter and crying.

Case 2: A 67-year-old man with a history of hypertension was admitted to hospital because of a right-sided weakness, preceded by an attack of irresistible laughter which lasted nearly an hour. Neurological examination revealed a right hemiparesis with an extensor plantar response on the right side. There were no other deficits. A few days later dysphagia in addition to attacks of forced laughter and crying developed. He found the attacks very disturbing as they were completely unmotivated and recurred several times a day. MRI, which was performed on the 1st day and repeated a week later, revealed no pathology. When the patient was seen a month later he was entirely normal.

Case 3: A 85-year-old woman with a history of hypertension was admitted to hospital because of a right-sided weakness that developed after an attack of laughter which had lasted about 15 min and was unmotivated. On examination, there was right hemiparesis with a mild sensory aphasia. The remainder of the examination was normal. CT performed on the 1st day was normal. MRI could not be performed. The hemiparesis began to recover after the 2nd day and the attack of laughter never appeared again. The sensory dysphasia continued when she was discharged a week later.

In our three patients an attack of unmotivated laughter was the initial manifestation. Other neurological signs appeared a few hours after the laughter attack had ceased. In contrast to previous reports, after the acute attack the prodromal laughter in cases 1 and 2 was seen to be transformed into classical pathological laughter and crying. Though previous reports mention a grave clinical picture with death of the patients shortly after the stroke [5, 7], our patients' clinical findings were mild and a good recovery was observed in a short time, especially in cases 1 and 2. However, in both cases pathological laughter and crying was observed after an interval of a few days or weeks, so they were patients in whom “prodromal laughter” seemed to give way to “following hyperemotionalism” [1]. Therefore the prodromal laughter and the pathological laughter and crying seem to have a common mechanism. Poeck [5] proposed that, in fou rire prodromique there would be a loss of the tonic control of laughter whereas in pathological laughter and crying, loss of the phasic control could be the underlying mechanism. Our observations suggest that rather than being due to different mechanisms these two types of neurological signs seem to be a continuum. The exact mechanism of pathological laughter and crying is not clear and merits further study.

References

1. Allman P, Hope RA, Fairburn CG (1990) Emotionalism following brain damage: a complex phenomenon. *Postgrad Med J* 66: 818–821
2. Féré MC (1903) Le fou rire prodromique. *Rev Neurol (Paris)* 11: 353–358
3. Ironside R (1956) Disorders of laughter due to brain lesions. *Brain* 79: 589–609
4. Martin JP (1950) Fits of laughter (sham mirth) in organic cerebral disease. *Brain* 70: 453–464

5. Poeck K (1985) Pathological laughter and crying. In: Vinken PJ, Bruyn GW, Klawans HV (eds) *Handbook of clinical neurology*. Elsevier, Amsterdam, pp 219–225
6. Swash M (1972) Released involuntary laughter after temporal lobe infarction. *J Neurol Neurosurg Psychiatry* 35: 108–113
7. Wali GM (1993) "Fou rire prodromique" heralding a brainstem stroke. *J Neurol Neurosurg Psychiatry* 56: 209–210

C. Ertekin (✉)

Department of Clinical Neurophysiology,
Ege University Faculty of Medicine,
Bornova, TR-35100 Izmir, Turkey
Tel.: +232 3880980,
Fax: +232 3422141

Ö. Ekmekçi · N. Çelebisoy
Department of Neurology,
Ege University Faculty of Medicine,
Bornova, Izmir, Turkey

José M. Borrás
Francisco García Salazar
Francisco Grandas

Oculomotor palsy and contralateral tremor (Benedikt's syndrome) following a stereotactic procedure

Received: 13 September 1996

Accepted: 29 November 1996

Sirs: Benedikt's syndrome is a classical brain stem syndrome characterized by the association of unilateral third nerve palsy and tremor in the contralateral, often paretic, limbs [2]. This syndrome has been attributed to lesions in the midbrain, involving the ipsilateral red nucleus, substantia nigra, oculomotor fibres and the cerebral peduncle [12].

We describe the clinical and neuroimaging findings in a patient who developed tremor with crossed oculomotor paralysis following a stereo-

tactic procedure for aspiration of a colloid cyst of the third ventricle. The surgical procedure caused a small haemorrhage in the upper ventromedial part of the cerebral peduncle. This case illustrates an unusual complication of stereotactic surgery and highlights the role of midbrain structures in the pathophysiology of certain types of tremors.

A 64-year-old man, without previous relevant medical history, was admitted to hospital because of a brief episode of loss of consciousness and a minor head injury. On examination the patient was inattentive, had an unsteady gait and bladder incontinence. No other abnormal neurological findings were observed. Cranial CT showed a hyperdense lesion at the level of the third ventricle with marked obstructive hydrocephalus. MRI disclosed a nodular high-intensity signal in the third ventricle on T1-weighted and a hypointense lesion on T2-weighted images, consistent with a colloid cyst (Fig. 1).

The hydrocephalus was treated by the insertion of a ventriculo-peritoneal shunt with improvement of the patient's neurological status. In a

second stage, puncture and aspiration of the intraventricular colloid cyst was attempted by means of a stereotactic transfrontal approach under local anaesthesia, using a Leksell stereotactic frame. The target coordinates were previously determined from CT images of the lesion. After three attempts to puncture the colloid cyst with a Sedan's needle, the patient began to complain of diplopia and the surgical procedure was stopped. On examination an incomplete left oculomotor palsy, consisting of mydriasis not reacting to light and paresis of adduction, was evident.

Postoperative cranial CT revealed, in addition to the intraventricular colloid cyst, a small haemorrhagic lesion in the rostral midbrain, involving the ventromedial part of the left cerebral peduncle at the level of mesencephalon-diencephalon junction (Fig. 2).

Three weeks after surgery a tremor appeared in the right limbs, more marked in the arm. It had resting, postural and kinetic components, and exhibited medium to large amplitude and a frequency of around 4 Hz. The tremor became more coarse

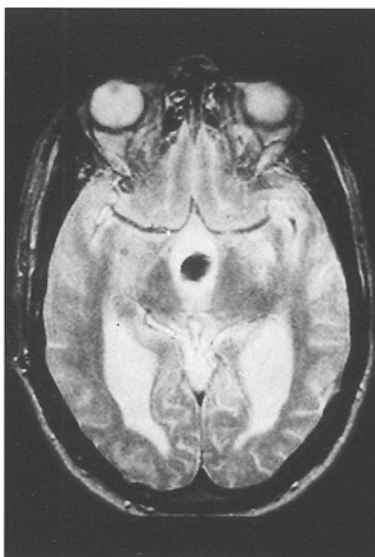


Fig. 1 Brain MRI; T2-weighted image showing a rounded hypointense lesion in the third ventricle, consistent with a colloid cyst

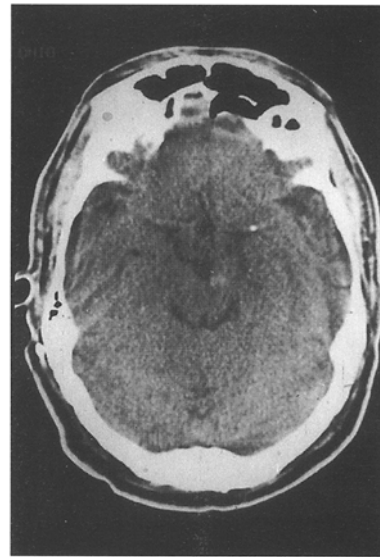


Fig. 2 Postoperative brain CT showing a small haemorrhagic lesion in the ventromedial part of the left cerebral peduncle