

## Brief Communications

### Phenytoin-Related Chorea in Children With Deep Hemispheric Vascular Malformations

Chorea is a known side effect of certain antiepileptic medications. Children have been reported to develop chorea after using carbamazepine, phenobarbital, ethosuximide, and phenytoin.<sup>1</sup> Anticonvulsant-related chorea secondary to phenytoin appears to be more common in children and is seen more often in the presence of pre-existing central nervous system disease or serum toxicity and when used concomitantly with other anticonvulsants.<sup>2,3</sup> Paradoxically, anticonvulsants have also been shown to be effective, at times, in treating this disorder.<sup>1</sup>

We report two children with deep hemispheric malformations, seen after craniotomy procedures, who received phenytoin postoperatively for seizure prophylaxis. They both had choreiform movements that appeared to be exacerbated by phenytoin and were relieved with the use of carbamazepine.

#### Case 1

A previously healthy 8-year-old girl developed unusual left hand movements 1 month before admission. Her family reported these movements as chaotic, at times semipurposeful, and present only while she was awake. After several days, these movements also involved the left leg. Eventually, she had mild difficulty with walking due to the movements. She had no history of group A *Streptococcus* pharyngitis within the previous year. There was no family history of movement disorders. A magnetic resonance imaging

study of the brain showed a deep hemispheric cavernous malformation near the right basal ganglia and the posterior limb of the internal capsule (Figure 1). An angiogram of the cerebral vessels was normal. A right temporal stereotaxic-guided craniotomy with resection of the angiographically occult vascular malformation was performed without complications. She was then started on phenytoin for seizure prophylaxis. After surgery, the patient's movement disorder persisted and even worsened. She was unable to walk due to her choreoathetoid movements. Three days after surgery, neurologic examination showed marked choreoathetoid movements in the left arm and leg, with intermittent ballismus. Serum phenytoin concentration was 16.9  $\mu\text{g/mL}$ . Phenytoin was discontinued, and carbamazepine was started. Within 1 day, the patient's movements markedly improved, and she was able to ambulate. She continued to show improvement on carbamazepine, and after several months, the medication was successfully discontinued without recurrence of abnormal movements.

#### Case 2

A 16-year-old girl had been well until age 12 years, when she presented with sudden onset of severe headache, obtundation, left homonymous hemianopia, and a left hemiparesis. A cranial computed tomographic scan showed a deep right-sided intracranial hemorrhage. An angiogram revealed an arteriovenous malformation that was fed from the anterior and posterior choroidal vessels in the right basal ganglia and pulvinar area. She recovered from all of her neurologic deficits over the next 2 months. However, she continued to have severe recurring headaches. At 13 years of age, she underwent gamma-knife radiosurgery resulting in a reduction in size of the malformation. At 16 years of age, she again developed severe headaches. An initial neurologic examination was entirely normal. Magnetic resonance imaging revealed a large arteriovenous malformation involving almost the entire right

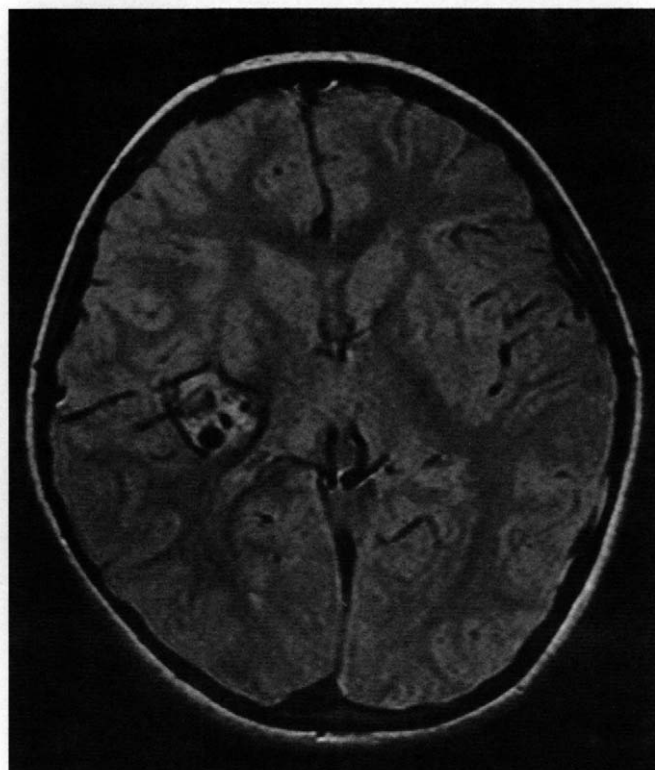


Figure 1. Case 1. Axial, proton-density magnetic resonance image illustrating deep right basal ganglia arteriovenous malformation.

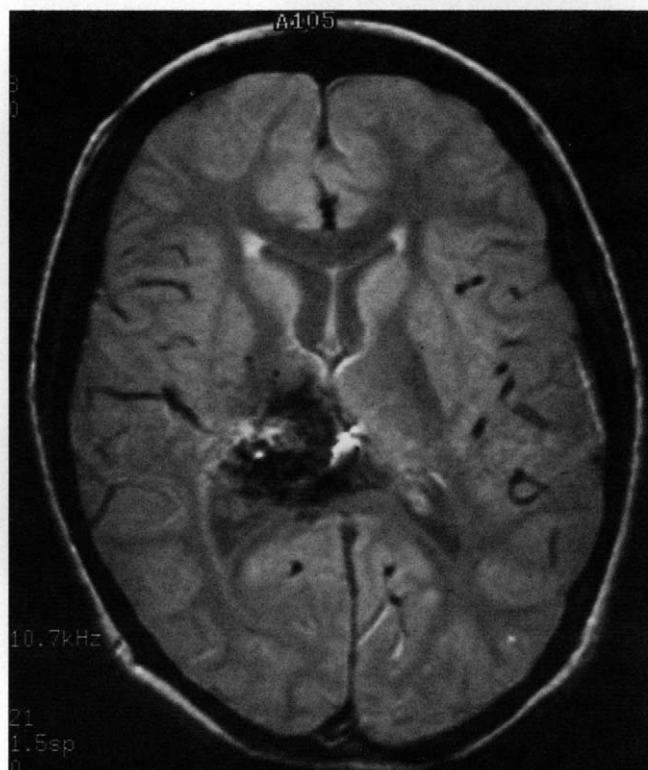


Figure 2. Case 2. Axial, proton-density magnetic resonance image illustrating deep right thalamic arteriovenous malformation.

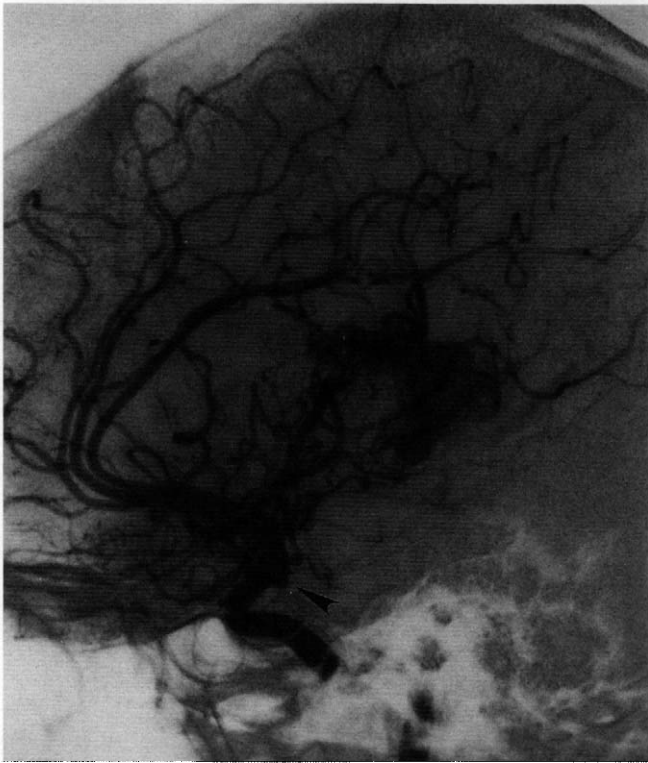

Figure 3. Case 2. Digital-subtraction, arterial phase, internal carotid cerebral angiogram illustrating arteriovenous malformation and posterior communicating artery aneurysm (arrowhead).

thalamus (Figure 2). On coronal images, there was extension into the subthalamic region. A cerebral angiogram showed a 4-mm aneurysm of the right posterior communicating artery (Figure 3) in addition to the arteriovenous malformation. She then underwent a right craniotomy with aneurysm clipping without complications. Postoperatively, she was started on phenytoin for seizure prophylaxis. On the fourth postoperative day, a neurologic consultation was obtained for new involuntary movements of her left hand. She reported that these movements were arrhythmic, not suppressible with restraint, and could occur any time during wakefulness. Examination showed mild chorea involving only the left hand and fingers, most prevalent while lightly grasping the examiner's fingers. She was unable to voluntarily suppress these movements. Serum phenytoin concentration was 18.0  $\mu\text{g/mL}$ . Phenytoin was discontinued, and carbamazepine was started. The abnormal movements improved within 1 day of this medication change. The movements subsided after discharge, and the medication was eventually discontinued.

### Discussion

Phenytoin-related chorea has been frequently reported, with the majority of cases occurring in children.<sup>3</sup> An association has been recognized with underlying central nervous system damage and the onset of this condition. The association of chorea with the administration of other anticonvulsants, such as carbamazepine, phenobarbital, and ethosuximide, appears to be much less common.<sup>4</sup> Various agents have been used in the treatment of childhood chorea, including dopamine blocking or reuptake agents and, paradoxically, various anticonvulsants including phenytoin, carbamazepine, phenobarbital, primidone, chlorpromazine, and valproic acid.<sup>1,5,6</sup>

Both children described here exhibited chorea contralateral to deep hemispheric vascular malformations located near the basal

ganglia. The first patient developed choreoathetosis preoperatively, before initiation of phenytoin. She showed an exacerbation of movements in the postoperative period while on phenytoin. The second patient developed postoperative chorea after phenytoin had been started for seizure prophylaxis. Interestingly, both patients showed marked improvement within 1 day after discontinuation of phenytoin and initiation of carbamazepine. It is reasonable to suggest that these patients were predisposed to the development of chorea given the proximity of the underlying vascular malformations to the basal ganglia (including the subthalamic nuclei) and their anatomic connections. The use of phenytoin in these cases may have had a synergistic effect in producing a movement disorder. The divergence in the effects of phenytoin and carbamazepine on choreoathetosis is remarkable in these cases.

We conclude that the use of phenytoin as a postoperative anticonvulsant may precipitate or exacerbate choreoathetosis in some children, especially in those with lesions near the basal ganglia. Furthermore, given the significantly higher association of childhood chorea associated with this medication when compared with other antiepileptic drugs, we also suggest that other anticonvulsants, such as carbamazepine may be more appropriate for the use of seizure prophylaxis and may even be helpful in alleviating these movements in such patients.

Mark W. Koukkari, MD

Marc A. Vanefsky, MD

Gary K. Steinberg, MD, PhD

Jin S. Hahn, MD

*Departments of Neurology and Neurosurgery  
Stanford Stroke Center and  
Stanford University School of Medicine  
Stanford, California*

Received August 2, 1995. Received revised Oct 11 and Oct 12, 1995. Accepted for publication Oct 25, 1995.

This work was first presented in part on October 2, 1994, at the Conjoint Meeting of the Child Neurology Society and the International Child Neurology Association, San Francisco, CA.

### Acknowledgments

This work was supported in part by a grant from the William Randolph Hearst Foundation (G.K.S.).

### References

1. Klawans HL, Brandabur MM: Chorea in childhood. *Pediatr Ann* 1993;22:41-50.
2. Filloux F, Thompson JA: Transient chorea induced by phenytoin. *J Pediatr* 1987;110:639-641.
3. Harrison MB, Lyons GR, Landow ER: Phenytoin and dyskinesias: A report of two cases and review of the literature. *Mov Disord* 1993;8:19-27.
4. Levy RH, Dreifuss FE, Mattson RH, et al: *Antiepileptic Drugs*, 3rd ed. New York, Raven Press, 1989.
5. Roig M, Montserrat L, Gallart A: Carbamazepine: An alternative drug for the treatment of nonhereditary chorea. *Pediatrics* 1988;82:492-495.
6. Roulet E, Deonna T: Successful treatment of hereditary dominant chorea with carbamazepine. *Pediatrics* 1989;83:1077.