

Benedikt G. H. Schoser
Christoph Heesen
Bernd Eckert
Andreas Thie

Cerebral hyperperfusion injury after percutaneous transluminal angioplasty of extracranial arteries

Received: 8 May 1996
Received in revised form: 23 July 1996
Accepted: 25 July 1996

B. G. H. Schoser (✉) · C. Heesen
A. Thie
Department of Neurology,
University of Hamburg,
University Hospital Hamburg-Eppendorf,
Martinistrasse 52,
D-20246 Hamburg, Germany
Tel.: 49-40-4717-3771,
Fax: 49-40-4717-5086

B. Eckert
Department of Neuroradiology,
University Hospital Hamburg-Eppendorf,
Hamburg, Germany

Abstract Cerebral hyperperfusion syndrome after carotid endarterectomy (CEA) is a rare but well-known phenomenon. Percutaneous transluminal angioplasty (PTA) is being widely evaluated for treatment of selected stenoses of the extracranial arteries. Its benefits and risks still need to be established. Hyperperfusion injury (HI) after PTA of cerebral arteries has not been reported. We describe two patients with severe HI, one with a small putaminal haemorrhage and the other with diffuse basal subarachnoid haemorrhage. In both cases, a typical clinical hyperperfusion syndrome with headache, confusion, vomiting and seizures occurred. Patient 1 underwent PTA of

the left carotid artery, both subclavian arteries and proximal vertebral arteries, patient 2 had carotid angioplasty only. Transcranial Doppler ultrasound displayed markedly elevated blood-flow velocities. HI may occur after PTA of extracranial arteries. The pathogenesis might be similar to reperfusion injury after CEA. Our findings suggest that: (1) HI may occur after PTA; (2) patients should be monitored after PTA for HI; (3) further risk factors for HI need to be identified.

Key words Hyperperfusion syndrome · Reperfusion injury · Angioplasty

Introduction

Percutaneous transluminal angioplasty (PTA) is increasingly used for treatment of stenosis of extracranial arteries on an experimental basis [2, 4–6, 12, 16, 23, 24, 26]. Experience with risks and complications of this procedure is still accumulating [1]. There have been three major categories of complications: embolism associated with intravascular manipulation, haemodynamic compromise during balloon inflation, and early restenosis or occlusion [1, 2, 4–6, 12, 16, 23, 24, 26]. There have been no reports of reperfusion injury after successful PTA, similar to that encountered after carotid endarterectomy (CEA) [3, 7, 8, 11, 14, 17–19, 21, 22]. We report here two cases of reperfusion injury with subarachnoid haemorrhage (SAH) and intracerebral haemorrhage (ICH) from our series of 86 patients treated with PTA of extracranial arteries from 1989 to 1995 [5].

Case reports

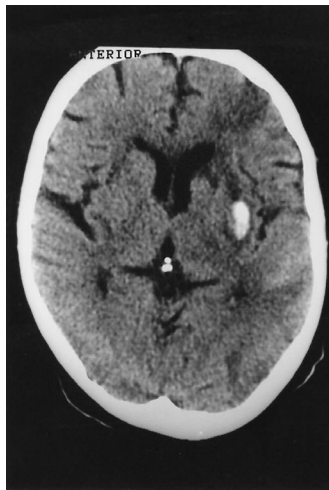
Case 1

A 49-year-old right-handed man was admitted to our hospital for PTA of multiple extracranial artery stenoses. He gave a history of acute transient left-sided sensorimotor hemiparesis 6 weeks before. On admission, neurological examination was completely normal. CT of the brain showed left-sided borderzone infarction. Selective digital subtraction arteriography revealed high-grade stenosis of the left internal carotid artery (ICA), both subclavian arteries (SA) and both proximal vertebral arteries (VA). He underwent PTA with dilatation of the left ICA and both VA and stent insertion into the right SA. Immediately after PTA, he developed occipital headache, vomiting, mild confusion and increased arterial blood pressure (160/90 mmHg), but no neurological deficit. Sixteen hours after the intervention, he suddenly developed arterial hypertension (240/100 mmHg), severe coma, tonic seizures, bilateral dilated unresponsive pupils, and decorticate posturing. CT revealed diffuse basal SAH, swelling of the brainstem and acute hydrocephalus (Fig. 1). Transcranial Doppler sonography (TCD)

Fig. 1 Diffuse basal SAH with swelling of the brainstem and acute hydrocephalus

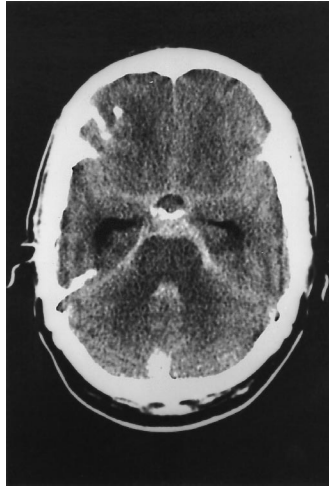

Fig. 2 Left-sided putaminal ICH with left-sided borderzone infarction and subcortical oedema



showed marked increase of mean blood flow velocities in the VA and basilar artery (120–160 cm/s, pulsatility index (PI) 1.7; pre-PTA 40–60 cm/s, PI 0.7). Aggressive treatment of elevated intracranial pressure did not prevent neurological deterioration. The patient died with upward transtentorial herniation within 20 h. Necropsy was not performed.

Case 2

A 59-year-old woman with a history of minor depression for several years was admitted to our hospital for PTA of a high-grade stenosis of the left ICA. On examination, she exhibited a mild right-sided sensorimotor hemiparesis. CT of the brain showed a left-sided borderzone infarction. Three days after left carotid PTA, she developed left-sided temporal headache, vomiting, confusion, and arterial hypertension (240/100 mmHg). Within 7 h, she rapidly developed right-sided hemiplegia, global aphasia and simple partial seizures on the right. CT disclosed a small left-sided putaminal ICH and subcortical oedema (Fig. 2). TCD showed an increase of mean blood flow velocity and pulsatility index in the left middle cerebral artery (150 cm/s, PI 2.2; pre-PTA 50–70 cm/s, PI 0.6), but normal mean blood flow velocities in the right middle cerebral artery (80 cm/s, PI 0.8). The patient recovered with a mild right upper limb paresis.

Discussion

To our knowledge, this is the first report of cerebral reperfusion injury after PTA of extracranial arteries. Our two patients became symptomatic with severe localized headache, vomiting, confusion, seizures, and arterial hypertension. These symptoms are typical of the hyperperfusion syndrome after CEA and commonly occur prior to intracranial bleeding [3, 7, 8, 11, 14, 15, 17–19, 21, 22]. Four-vessel angiography in our patients did not reveal any aneurysm or vascular malformation. The mechanism of impaired autoregulation in the hyperperfusion syndrome after CEA might relate to: (1) damage of carotid baroreceptors, resulting in carotid baroreceptor insensitivity; (2) secondary arterial hypertension after a short period of bradycardia and hypotension immediately after CEA [8]; (3) increased expression of metabolic factors, e.g. lactic acid, adenosine, free oxygen radicals and vasoactive neuropeptides from perivascular nerve endings, e.g. calcitonin gene-related peptide, which are known to contribute hyperperfusion [15] and (4) long-lasting hypoperfusion distal to the tight stenosis resulting in maximal vasodilatation [10]. Impaired autoregulation [3, 7, 8, 10, 11, 14, 17–19, 21, 22] combined with hyperperfusion, as suggested by increased mean blood flow velocities and pulsatility indices on ultrasound [9–11, 21], might contribute to high-pressure autoregulatory failure in which very high perfusion pressure overwhelms arteriolar vasoconstriction ability. Finally, capillaries may leak through disruption of tight junctions of capillary endothelial cells with extravasation of protein and fluid, causing cerebral oedema and haemorrhage [3, 10]. There are no reports in the literature of SAH as a reperfusion injury after CEA. In patient 1, although ultrasonic evaluation and four-vessel angiography were normal, we cannot exclude an intracranial dissection or a vertebral or basilar arterial aneurysm. However, the reperfusion injury after transluminal recanalisation of the vertebrobasilar territory combined with the autoregulatory failure and hyperperfusion as a result of simultaneous transluminal carotid recanalisation may also cause SAH by overwhelming the existing weakness of the arterial wall. Thus, SAH as a reperfusion injury after multiple angioplasties might be a distinct entity, which needs further evaluation and discussion. The mechanisms of complications and clinical similarities of the hyperperfusion syndrome after PTA and CEA are obvious. Therefore, like the reported hyperperfusion syndrome after CEA, we can describe a hyperperfusion syndrome after PTA as consisting of localized headache, vomiting, confusion and seizures.

To ensure adequate post-interventional management, observation in an intensive care unit for at least 24 h with monitoring of arterial blood pressure, treatment of hypertension and seizures, and access to ultrasonic, electroencephalographic and CT examination is necessary. Medical treatment after PTA commonly includes full-dose antico-

agulation for 24 h and antiplatelet therapy to avoid embolism. Because of the above-mentioned possible complications, careful control of arterial blood pressure is highly recommended. Detection of increased mean flow velocity and PI on ultrasound and clinical signs suggestive of HI should lead to increased intensive care monitoring for HI. Whether full-dose anticoagulation in this phase might be better avoided should be studied in larger series [10]. New management strategies of the hyperperfusion syndrome, e.g. by blocking perivasular sensory nerve fibres, have not yet been evaluated [15]. Like others [8, 20], we use clonidine for treatment of arterial hypertension after PTA in order to reduce the sympathoneural outflow associated with injured baroreceptors after PTA. Multiple angioplasties of vessels supplying the brain in one session may also predispose to reperfusion injury.

To summarise, reperfusion injury after PTA is a very rare, but serious complication. The frequency of intracerebral haemorrhage after CEA ranges from 0.3% to 1.2% [3]. Reperfusion injury with intracerebral haemorrhage or SAH after PTA might be in the same range; therefore, in addition to the above-mentioned risk factors, distinct new risk factors of autoregulation failure will have to be determined. The detection of subcortical oedema by early CT might be helpful in future [3]. The predictive power of elevated blood flow velocities and PI on TCD to discriminate between simple hyperaemia and harmful reperfusion injury needs to be further evaluated [10]. Future studies combining transcranial ultrasound [10], magnetic resonance flow quantification [25] and near-infrared spectroscopy [13] could prove useful in detecting reperfusion injury after both PTA and CEA.

References

1. Beeb HG, Archie JP, Baker WH, Barnes RW, Becker GJ, Bernstein EF, Brener B, Clagett GP, Clowes AW, Cooke JP, Creager MA, Cronenwett JL, Dake M, DeWeese JA, Fogarty TJ, Freischlag JA, Goldstone J, Greenfield LJ, Hertzner NR, Hobson RW, Joyce JW, Katzen BT, LoGerfo FW, Mohr JP, Moore WS, Najafi H, Ricotta JJ, Riles TS, Ring EJ, Robertson J, Rutherford RB, Sos T, Stanley JC, Strandness DE, Sumner DS, Toole J, Towne JB, Veith FJ, Whittemore AD, Yao JST, Zarins CK (1996) Concern about safety of carotid angioplasty. *Stroke* 27: 197–198
2. Bockenheimer S, Mathias K (1983) Percutaneous transluminal angioplasty in arteriosclerotic internal carotid artery stenosis. *Am J Neuroradiol* 4: 791–792
3. Breen JC, Caplan LR, DeWitt LD, Belkin M, Mackey WC, O'Donnell TP (1996) Brain edema after carotid surgery. *Neurology* 46: 175–181
4. Brown MM (1992) Balloon angioplasty for cerebrovascular disease. *Neurol Res* 14: 159–163
5. Eckert B, Zanella FE, Thie A, Steinmetz J, Zeumer H (1996) Angioplasty of internal carotid artery: Results, complications and follow-up in 61 cases. *Cerebrovasc Dis* 6: 97–105
6. Freitag G, Freitag J, Koch RD (1987) Transluminal angioplasty for the treatment of carotid artery stenosis. *Vasa* 16: 67–71
7. George SM, Klamer TW, Lambert GE (1993) Cerebral hyperperfusion syndrome: an etiology of seizures following carotid endarterectomy. *J Ky Med Assoc* 91: 451–453
8. Ille O, Woimant F, Pruna A, Corabianu O, Idatte JM, Haguenu M (1995) Hypertensive encephalopathy after bilateral carotid endarterectomy. *Stroke* 26: 488–491
9. Jansen C, Ramos LMP, Heereswijk JPM van, Moll FL, Gijn J van, Akerstaff RGA (1994) Impact of microembolism and hemodynamic changes in the brain during carotid endarterectomy. *Stroke* 25: 992–997
10. Jansen C, Sprengers AM, Moll FI, Vermeulen FEE, Hamerlijnck RPHM, Gijn J van, Akerstaff RGA (1994) Prediction of intracerebral haemorrhage after carotid endarterectomy by clinical criteria and intraoperative transcranial doppler monitoring. *Eur J Vasc Surg* 8: 303–308
11. Jorgensen LG, Schroeder TV (1993) Defective cerebrovascular autoregulation after carotid endarterectomy. *Eur J Vasc Surg* 7: 370–379
12. Kachel R, Basche S, Heerklotz I, Grossmann K, Endler S (1991) Percutaneous transluminal angioplasty of supra-aortic arteries especially the internal carotid artery. *Neuroradiology* 33: 191–194
13. Kirkpatrick PJ, Smielewski P, Whitfield PC, Czornyka M, Menon D, Pickard JD (1995) An observational study of near infrared spectroscopy during carotid endarterectomy. *J Neurosurg* 82: 756–763
14. Magee TR, Davies AH, Horrocks M (1994) Transcranial Doppler evaluation of cerebral hyperperfusion syndrome after carotid endarterectomy. *Eur J Vasc Surg* 8: 104–106
15. McFarlane R, Moskowitz MA, Sakas DE, Tasdemiroglu E, Wie EP, Kontos HA (1991) The role of neuroeffector mechanisms in cerebral hyperperfusion syndromes. *J Neurosurg* 75: 845–855
16. Munari LM, Belloni G, Perretti A, Ghia F, Moschini L, Porta M (1992) Carotid percutaneous angioplasty. *Neurol Res* 14: 156–158
17. Nielsen TG, Sillesen H, Schroeder TV (1995) Seizures following carotid endarterectomy in patients with severely compromised cerebral circulation. *Eur J Endovasc Surg* 9: 53–57
18. Penn AA, Schomer DF, Steinberg GK (1995) Imaging studies of cerebral hyperperfusion after carotid endarterectomy – case report. *J Neurosurg* 83: 133–137
19. Reigle MM, Hollier LH, Sundt TM, Piegras DG, Sharbrough AU, Cherry KJ (1987) Cerebral hyperperfusion syndrome: a cause of neurologic dysfunction after carotid endarterectomy. *J Vasc Surg* 5: 628–634
20. Robertson D, Hollister AS, Biaggioni I, Netterville JL, Mosqueda-Garcia R, Robertson RM (1993) The diagnosis and treatment of baroreceptor failure. *N Engl J Med* 329: 1449–1455
21. Schroeder TV, Sillesen H, Sorensen O, Engell HC (1987) Cerebral hyperperfusion following carotid endarterectomy. *J Neurosurg* 66: 824–829
22. Solomon RA, Loftus CM, Quest DO, Correll JW (1986) Incidence and etiology of intracerebral hemorrhage following carotid endarterectomy. *J Neurosurg* 64: 29–34

-
23. Theron J (1992) Angioplasty of brachiocephalic vessels. In: Vinuela F, Halbach VV, Dion JE (eds) *Interventional neuroradiology: endovascular therapy of the central nervous system*. Raven Press, New York, pp 167–180
24. Tsai FY, Higashida R., Meoli C (1992) Percutaneous transluminal angioplasty of extracranial and intracranial arterial stenosis in the head and neck. *Neuroimaging Clin North Am* 2: 371–384
25. Vanninen R, Koivisto K, Tulla H, Manninen H, Partanen K (1995) Hemodynamic effects of carotid endarterectomy by magnetic resonance flow quantification. *Stroke* 26: 84–89
26. Wiggli U, Gratzl O (1983) Transluminal angioplasty of stenotic carotid arteries: case reports and protocol. *Am J Neuroradiol* 4: 793–795