

catheters or other permanent medical devices. It can cause peritonitis, osteomyelitis, and meningitis.<sup>3,5</sup> On the basis of in vitro testing, ciprofloxacin, trimethoprim-sulfamethoxazole, aminoglycosides, and imipenem are reasonable therapeutic choices, although no drug is uniformly effective against all reported isolates. *Ochrobactrum anthropi* should be considered as a cause of endogenous endophthalmitis in debilitated patients with indwelling medical devices.

#### REFERENCES

1. Ezzedine H, Mourad M, Van Ossel C, et al. An outbreak of *Ochrobactrum anthropi* bacteremia in five organ transplant patients. *J Hosp Infect* 1994;27:35-42.
2. Braun M, Jonas JB, Schonherr U, Naumann GOH. *Ochrobactrum anthropi* endophthalmitis after uncomplicated cataract surgery. *Am J Ophthalmol* 1996;122:272-273.
3. Chang HJ, Christenson JC, Pavia AT, et al. *Ochrobactrum anthropi* meningitis in pediatric pericardial allograft transplant recipients. *J Infect Dis* 1996;173:656-660.
4. Kern WV, Oethinger M, Kaufhold A, Rozdzinski E, Marre R. *Ochrobactrum anthropi* bacteremia: report of four cases and short review. *Infection* 1993;5:306-310.
5. Cieslak TJ, Robb ML, Drabick CJ, Fischer GW. Catheter-associated sepsis caused by *Ochrobactrum anthropi*: report of a case and review of related nonfermentative bacteria. *Clin Infect Dis* 1992;14:902-907.

## Horner Syndrome as an Isolated Manifestation of an Intrapetrous Internal Carotid Artery Dissection

Rafael Bilbao, MD, Sonia Amoros, MD, and Juan Murube, MD

**PURPOSE:** To describe the atypical localization and unusual clinical manifestation of an internal carotid artery dissection.

**METHODS:** We examined a 43-year-old woman who had sudden onset of left ptosis and miosis with vague dysesthesia around her eye.

**RESULTS:** Her examination showed an intrapetrous carotid artery dissection.

**CONCLUSIONS:** The intrapetrous segment is an extremely rare localization for an internal carotid artery dissection. The differential diagnosis of acute Horner syndrome should include carotid dissection, which is usually accompanied by other neurologic manifestations.

WE EXAMINED A 43-YEAR-OLD WOMAN WITH SUDDEN left-sided ptosis and mild discomfort and tenderness around her eye that had lasted 3 days. There were no other ocular or systemic symptoms. She reported no previous episodes of head or neck trauma. Corrected visual acuity, extraocular motility, and slit-lamp and fundus examination were all unremarkable. External examination disclosed a 2-mm left ptosis. Pupils measured RE, 5 mm and LE, 3 mm in room lighting; anisocoria was more perceptible in dim illumination, with pupils measuring RE, 8 mm and LE, 4 mm. Pupillary reaction to light and near stimulus was normal. Hemifacial anhidrosis was absent, and left trigeminal sensitivity was normal. Neurologic examination, chest x-ray, contrast brain and neck computed tomographic scan, magnetic resonance imaging, and supra-aortic Doppler ultrasound were all unremarkable.

To localize the site of the sympathetic deficit, we performed a phenylephrine 1% test (hydroxyamphetamine drops were not available). Fifteen minutes after phenylephrine 1% instillation in each eye, there was greater mydriasis in the left eye (Figure 1), providing evidence of a postganglionic lesion (presumably left denervation hypersensitivity). Finally, carotid angiography showed a narrowing area at the intrapetrous segment of the carotid siphon, with a mild poststenotic dilation because of a subintimal dissection in the resolution phase (Figure 2). The patient began anticoagulation with heparin and then warfarin sodium for a suggested duration of 6 months. Five months after its onset, Horner syndrome had not recovered, but the patient was otherwise asymptomatic.

Horner syndrome is present in up to 58% of internal carotid artery dissections<sup>1</sup> but usually manifests with other focal neurologic deficits because of local compression in the area of the dissection or, more commonly, thrombotic embolization from the dissected wall. Most patients experience neck, facial, or head pain ipsilateral to the lesion because of ischemia or stretching of the trigeminal pain fibers surrounding the carotid artery. Other associated manifestations may include transient monocular

Accepted for publication Nov 11, 1996.

Ophthalmology Department, Hospital Ramón y Cajal.  
Inquiries to Rafael Bilbao, Mauricio Legendre, 13, Madrid 28046, Spain; fax: 1-5622974.

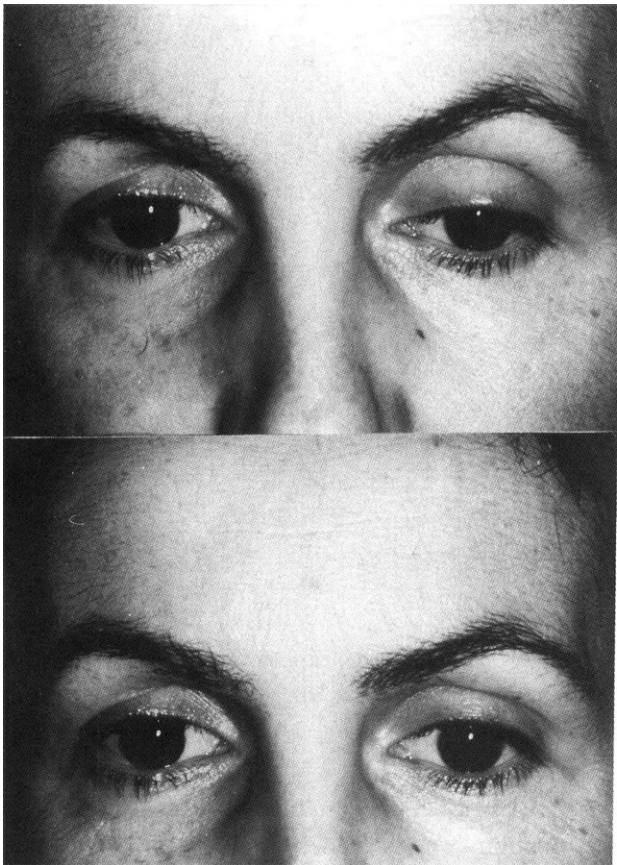


Figure 1. (Top) The patient before the phenylephrine 1% test, with ptosis and miosis of the left eye. (Bottom) Fifteen minutes after the instillation, the patient experienced greater mydriasis and palpebral retraction in the left eye because of a denervation hypersensitivity in a postganglionic lesion.

blindness, central retinal artery occlusion, cranial nerve palsies, syncope, and neck swelling, as well as contralateral focal sensory and motor deficits.<sup>2</sup> In the literature, we found only two cases with intrapetrous dissection; one manifested with intolerable pulsatile tinnitus and the other with cerebral infarction. Neither showed evidence of Horner syndrome.<sup>3</sup>

Carotid dissections are either spontaneous or traumatic. Some authors have emphasized that antecedent trauma may be minimal. Fibromuscular dysplasia, cystic medial necrosis, Marfan and Ehlers-Danlos syndromes, and large-vessel vasculitides have been reported to cause internal carotid artery dissection. However, in the majority of patients, as in our patient,

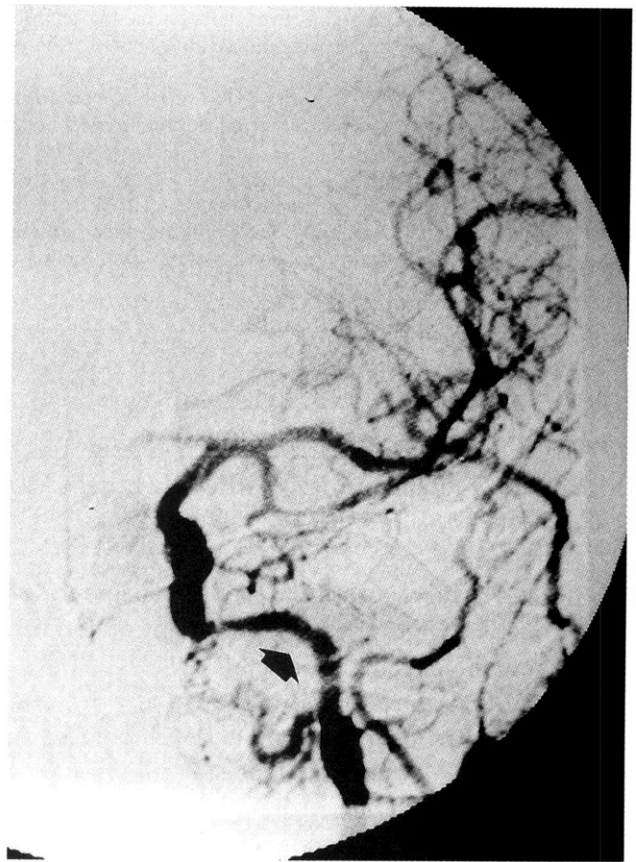


Figure 2. Cerebral angiography showing stenosis of the intrapetrous segment into the temporal bone (arrow) and poststenotic dilation.

the cause is unknown. The origin of the dissection is usually 2 to 3 cm distal to the carotid bulb and seldom extends beyond the base of the skull; the dissection is rarely located in the intrapetrous segment.<sup>4</sup>

Carotid dissection must be ruled out as the cause of acute Horner syndrome, especially when painful, after a postganglionic location has been determined.<sup>5</sup> Because the extracranial Doppler examination can be normal if the localization is above the angle of the jaw, magnetic resonance angiography or traditional cerebral angiography should be performed when previous examinations are negative.

#### REFERENCES

1. Bogousslavsky J, Despland PA, Regli F. Spontaneous carotid dissection with acute stroke. *Arch Neurol* 1987;44:479-482.

- Cullom RD, Cullom ME. Two neurophthalmic episodes separated in time and space. *Surv Ophthalmol* 1995;40:217-224.
- Saeed SR, Hinton AE, Ramsden RT, Lye RH. Spontaneous dissection of the intrapetrous internal carotid artery. *J Laryngol Otol* 1990;4:491-493.
- Van Damme H, Martin D, Stassen MP, et al. Dissections spontanées de la carotide interne. *J Mal Vasc* 1990;15:14-22.
- Kline LB, Vitek JJ, Raymon BC. Painful Horner's syndrome due to spontaneous carotid artery dissection. *Ophthalmology* 1987;94:226-230.

## Mucoepidermoid Carcinoma of the Caruncle

Richard C. Rodman, MD, Bartley R. Frueh, MD, and Victor M. Elnor, MD, PhD

**PURPOSE:** To report a case of mucoepidermoid carcinoma, a highly aggressive variant of conjunctival squamous cell carcinoma.

**METHODS:** We examined and treated a 57-year-old man with mucoepidermoid carcinoma of the caruncle, a highly unusual site for this tumor.

**RESULTS:** In the past, simple excision of this tumor has been followed by rapid recurrence. Our patient underwent wide surgical excision of the tumor and has shown no evidence of recurrence after 16 months of follow-up.

**CONCLUSION:** Mucoepidermoid carcinoma may first manifest in the caruncle. Histologically verified, tumor-free surgical margins are necessary for complete excision.

**M**UCOEPIDERMOID CARCINOMA IS A RARE CONJUNCTIVAL tumor that tends to occur near the corneoscleral limbus of elderly patients. This tumor is considered a highly invasive variant of squamous cell carcinoma, in which rapid recurrence is the rule after simple excision.<sup>1</sup> Therefore, early detection and wide local excision yield optimal results. We report a 57-year-old man with mucoepidermoid carcinoma of the caruncle.

A 57-year-old man was referred to the W. K.

Accepted for publication Nov 18, 1996.

W. K. Kellogg Eye Center, Department of Ophthalmology, University of Michigan.

Inquiries to Richard Rodman, MD, Wills Eye Hospital Cornea Service, 900 Walnut St, Philadelphia, PA 19107-5598; fax: (215) 928-3854.

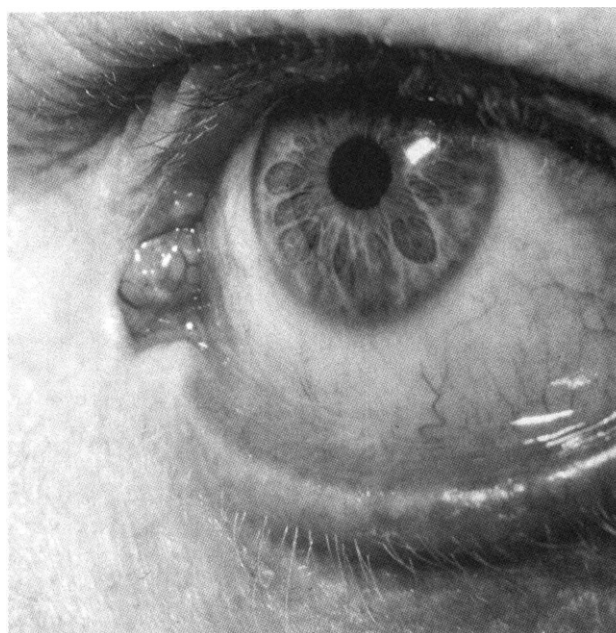

Figure 1. Biomicroscopic appearance of mucoepidermoid carcinoma of the caruncle.

Kellogg Eye Center, University of Michigan, for evaluation of epiphora secondary to cicatricial ectropion. He had undergone excision of a recurrent basal cell carcinoma of the left lower eyelid 13 years previously. Complete ophthalmic examination disclosed a cicatricial ectropion of the left lower eyelid and a fleshy, 2.5 × 3.5 × 2.0-mm vascular mass replacing the left caruncle (Figure 1). This mass was adherent to underlying medial canthal tissues. The upper and lower canalicular systems were patent. A biopsy was performed on the caruncular tumor, and histopathologic examination showed the lesion to be mucoepidermoid carcinoma.

The patient returned 3 weeks later for complete excision of the tumor of the left caruncle. After initial excision of remaining tumor, including surrounding areas of normal-appearing tissue, frozen sections disclosed margins positive for tumor (Figure 2). Additional excision of deeper tissue was also positive for mucoepidermoid carcinoma. Ultimately, deep resection of medial canthal tissue, as well as of the superior and inferior canaliculi, was required to achieve tumor-free margins. Sixteen months after wide excision of the mucoepidermoid carcinoma, our patient has shown no evidence of tumor recurrence.