

Crossed Mixed Transcortical Aphasia with Hypernomia

Toshikatsu Fujii^a, Atsushi Yamadori^a, Reiko Fukatsu^b,
Tatsuji Ogawa^c, Kyoko Suzuki^a

^aSection of Neuropsychology, Division of Disability Science,
Tohoku University Graduate School of Medicine, Sendai.

^bDepartment of Neurology, Miyagi National Hospital, Miyagi.

^cDepartment of Neurology, Sendai City Hospital, Sendai, Japan

Mixed transcortical aphasia is a syndrome characterized by reduced speech, severe comprehension deficits, preserved ability of repetition and naming difficulty [1]. We report here a patient with crossed mixed transcortical aphasia who showed preserved naming and unique naming behavior.

The patient was a 75-year-old, strongly right-handed [2] housewife with an eighth-grade education. She had no left-handed relatives. She suddenly developed left hemiplegia and aphasia. Neurological examination on day 27 revealed left homonymous hemianopsia with intact remaining cranial-nerve functions. She had a hemiplegia, hyperreflexia and pathological reflexes on the left side. We could not obtain reliable data of sensory function because of the patients' poor comprehension. CT scan on day 60 revealed a large infarct in the territory of the right middle cerebral artery (fig. 1). EEG on day 67 showed generalized slowing throughout the right hemisphere.

On neuropsychological examination, she was alert, but disoriented to time and place. She showed mild left unilateral neglect and constructional impairment. On testing of apraxia, she could not understand the examiner's commands. She seldom spoke spontaneously and tended to speak only when she was spoken to. Furthermore, when she spoke, she utilized the speech which had been spoken to her. She showed completion phenomenon. Her speech was fluent with normal rhythm but lacked affective elements. She repeated words perfectly and sentences fairly well with normal intonation. She showed occasional omitting of postpositional particles and verbal paraphasia. She showed little evidence of comprehending conversational speech and simple commands. Contrary to poor comprehension, her naming ability was quite good. Whenever objects, pictures or color tokens were presented, she started naming these stimuli one after another without waiting for the examiner's instructions. She named most of these stimuli correctly. Some errors were mainly semantic paraphasic without category specificity. Naming on definition and generating words (verbal fluency) was not feasible because of the patient's extremely poor comprehension. Reading aloud was excellent but reading comprehension was poor. She correctly wrote 3 names out of 8 visually presented stimuli in kanji on first examination, and 5 out of 5 on second examination. On both occasions, she never wrote in kana despite our commands. On writing to dictation, she could write words in kanji but never in kana. However, on another occasion, she wrote down sentences correctly mixing kanji and kana scripts. The Standard Language Test of Aphasia [3] was administered twice. Table 1 summarizes the results.

The most interesting feature of this crossed mixed transcortical aphasia was a preserved naming ability and its compulsive nature. There have been a few reports regarding spared naming without comprehension [4, 5]. These cases including ours have a theoretical importance. The fact that both auditory and reading comprehension were impaired, with preserved repetition, writing to dictation and

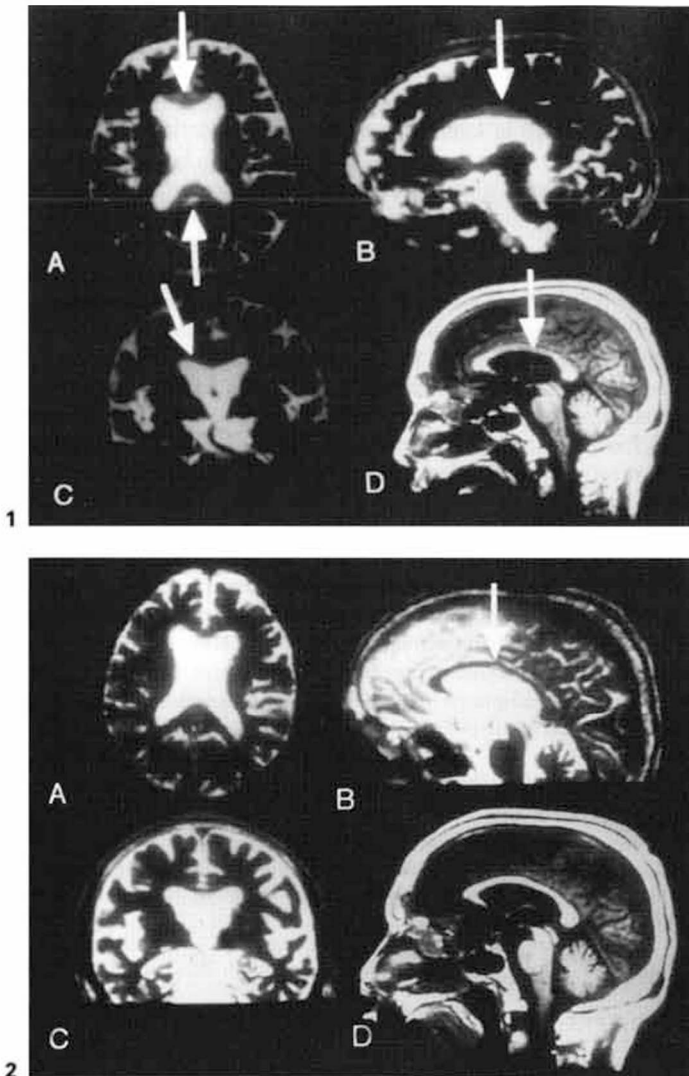


Fig. 1. Cranial MRI on March 3, 1994. A T2-weighted MRI in the axial (A), the sagittal (B), and the coronal image (C) revealing hyperintensity of the corpus callosum. A T1-weighted MRI in the sagittal plane demonstrating hypointensity of the middle portion of the corpus callosum, the genu and splenium (D).

Fig. 2. A-D Cranial MRI on May 9, 1994. Slight hyperintensity on T2WI in the sagittal image was observed at the middle portion of the corpus callosum (B).

- 3 Truffert A, Dumas J-J, Dandelot J-B: Dysconnexion interhémisphérique syndrome de Balint et troubles arthritiques persistants: maladie de Marchiafava-Bignami avec hémorragie de la substance blanche. *Rev Neurol (Paris)* 1996;152:174-180.
- 4 Bottomley P, Hart HR Jr, Edelstein WA, Schenck JF, Smith LS, Leue WM, Mueller OM, Redington RW: Anatomy and metabolism of the normal human brain studied by magnetic resonance at 1.5 tesla. *Radiology* 1984; 150:441-446.

Kazuya Yamashita, Third Department of Internal Medicine,
Shimane Medical University, 89-1, Enya-cho, Izumo, Shimane (Japan)

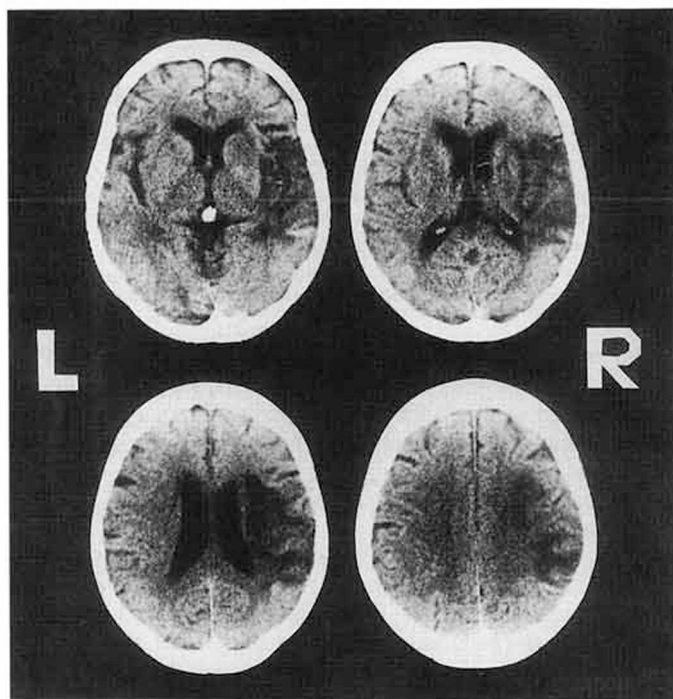


Fig. 1. CT scan obtained on day 60 showing a large infarct in the territory of the right middle cerebral artery.

Table 1. Results on subtests of SLTA

		Day 27 ~ 34	Day 49 ~ 56
Auditory comprehension	Words	0 ¹	0 ¹
	Sentences	NE	NE
Repetition	Words	10/10 (100)	10/10 (100)
	Sentences	6/10 (60)	7/10 (70)
Naming of visually presented stimuli		18/20 (90)	16/20 (80)
Reading aloud	Kana words	10/10 (100)	10/10 (100)
	Kanji words	10/10 (100)	10/10 (100)
	Sentences	4/5 (80)	5/5 (100)
Reading comprehension	Kana words	0 ¹	0 ¹
	Kanji words	0 ¹	0 ¹
	Sentences	NE	NE
Writing the name of visually presented stimuli	Kana words	0 ²	0 ²
	Kanji words	3/8 (37.5)	5/5 (100)
Writing to dictation	Kana words	0 ²	0 ²
	Kanji words	2/5 (40)	5/5 (100)
	Sentences	2/5 (40)	3/5 (60)

SLTA: Standard Language Test of Aphasia; NE: not examined; Kana: Japanese characters for syllabic writing; Kanji: Chinese characters used in Japanese writing. Percentages in parentheses.

¹ The patient could not understand the task and named all the pictures.

² We asked the patient to write with Kana character, but the patient continued writing with Kanji.

reading aloud, indicate that the phonological and orthographic word form systems were intact, but could only activate the phonological and orthographic output systems and not gain access to the semantics. On the contrary, she could name and write the names of visually presented stimuli in kanji, suggesting that the visual form system remained accessible to the phonological and orthographic output systems. This patient's profile provides evidence supporting the multiple semantic systems hypothesis or the direct visual-lexicon route hypothesis [6].

She started naming without any command whenever objects, pictures or color tokens were presented to her. We propose using the term 'hypernomia' for this compulsive and indiscriminate naming behavior. Like our patient, Heilman et al. [4] reported a case of mixed transcortical aphasia with intact naming who spontaneously named objects. Jacome [7] reported a mixed transcortical aphasic who showed repetitive, spontaneous whistling, and whistling in response to questions. He speculated that the symptom resulted from the release of the nondominant musical function by damage to the dominant hemisphere. Yamadori et al. [8, 9] described two symptoms they termed 'hypergraphia' and 'hyperlalia' as a right hemisphere syndrome. They hypothesized that the exaggerated writing and talking activity might result from disinhibition of the left hemisphere speech area from the right hemisphere. Hypernomia seen in the present case may be explained by a similar disinhibition hypothesis because she had a large right hemisphere infarct which might have released the left hemisphere activity.

References

- Benson DF, Ardila A: Aphasia: A Clinical Perspective. Oxford, Oxford University Press, 1996.
- Oller-Daurella L, Maso-Subirana E: Semiologia clinica y EEG de la lateralidad preferencial. 8th Congr Nacional Neuro-Psiquiatr Madrid. Libro de Ponencias, 1965.
- Takeda K: Standard Language Test of Aphasia (SLTA): Detailed description of construction of aphasia test in Japanese (in Japanese). *Neurol Sci (Tokyo)* 1977;21:1002-1013.
- Heilman KM, Tucker DM, Valenstein E: A case of mixed transcortical aphasia with intact naming. *Brain* 1976;99:415-426.
- Kremin H: Naming and its disorders; in Boller F, Grafman J (eds): *Handbook of Neuropsychology*. Amsterdam, Elsevier, 1988, vol 1, pp 307-328.
- Shuren J, Geldmacher D, Heilman KM: Nonoptic aphasia: Aphasia with preserved confrontation naming in Alzheimer's disease. *Neurology* 1993; 43:1900-1907.
- Jacome DE: Aphasia with elation, hypermusia, musicophilia and compulsive whistling. *J Neurol Neurosurg Psychiatry* 1984;47:308-310.
- Yamadori A, Mori E, Tabuchi M, Kudo Y, Mitani Y: Hypergraphia: A right hemisphere syndrome. *J Neurol Neurosurg Psychiatry* 1986;49: 1160-1164.
- Yamadori A, Osumi Y, Tabuchi M, Mori E, Yoshida T, Ohkawa S, Yoneda Y: Hyperlalia: A right cerebral hemisphere syndrome. *Behav Neurol* 1990; 3:143-151.

Toshikatsu Fujii, MD, Section of Neuropsychology, Division of Disability Science, Tohoku University Graduate School of Medicine, 1-1, Seiryomachi, Aoba-ku, Sendai 980-77 (Japan)
Phone: +81-22-717-7357, Fax: +81-22-717-7360
e-mail: fujii@mail.cc.tohoku.ac.jp