

Unusual Cause of Dysarthria in a Patient With Cerebrovascular Disease

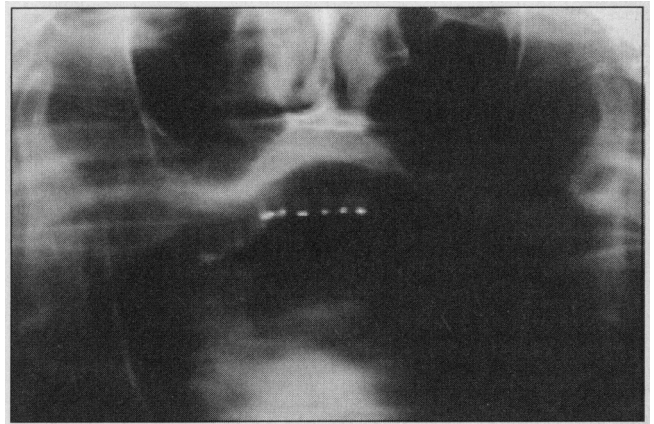
Motor difficulty in speech with impaired articulation and pronunciation has been termed *dysarthria*. Although the list of neurological causes of dysarthria is long, an elderly patient with acute dysarthria associated with myocardial infarction would often be presumed to have had a stroke. We were asked to evaluate a patient with stroke who had an unexpected mechanical cause for dysarthria.

A 67-year-old woman with diabetes awoke with jaw pain, right arm pain and numbness, and difficulty speaking and swallowing. She wrote a barely legible note saying "take me to the hospital." Five days earlier she had a brief episode of headache and right arm numbness associated with difficulty finding the right word and speaking intelligibly.

Electrocardiogram showed acute myocardial infarction and she was treated with tissue-type plasminogen activator. The pain in the right arm and in the jaw, as well as the right arm numbness, resolved, but her speech and swallowing difficulties persisted.

She was alert and followed 3-step commands. Speech was slurred and poorly articulated, although her tongue had normal strength and mobility. She was able to repeat phrases and had no difficulty finding words. Her jaw hung open and she was unable to close her mouth, nor could it be closed by the examiner, and the mandible appeared to have an unusual configuration. Other cranial nerve function appeared normal. She had good strength in all extremities except for questionable slight weakness in the right arm. The muscle stretch reflexes were present and symmetric in the upper extremities, but absent in the lower extremities. She had an extensor response on the right to plantar stimulation. Coordination was normal.

Computed tomography of the brain showed a non-acute left putamen lacunar infarct. Angiography showed moderate stenosis of the left internal carotid artery. Electroencephalogram showed slight slowing over the left hemisphere. Panorex view of the mandible showed bilateral anterior condylar dislocation (**Figure**). Reduc-



Panorex view of the mandible shows bilateral condylar dislocation without fracture.

tion of the mandibular dislocation resulted in complete resolution of the dysarthria.

The clinical characteristics of acute anterior mandibular dislocation include dysarthria, dysphagia, drooling, pain anterior to the ear, inability to close the mouth, jaw protrusion, and inability to approximate the teeth anteriorly.¹⁻³ Mandibular dislocation may be caused by trauma or by extreme mouth opening (mandibular hyperextension), such as during dental or anesthetic procedures, laughing, oral sex, yawning, vomiting, or taking a large bite of food.^{1,4} It may occur during an epileptic seizure or from abnormal jaw movements in movement disorders or dystonic drug reactions.^{5,6} Diagnosis is easily accomplished by a panoramic view of the mandible.

This patient had no history of trauma and had no idea how her jaw became dislocated. The initial clinical impression of symptomatic cerebrovascular disease was correct, but did not explain her dysarthria. Dysarthria and dysphagia are not usually found in anterior circulation ischemic events unless the infarct is very large, and their presence typically suggests brain-stem dysfunction. However, she had no other signs or symptoms of brain-stem dysfunction to suggest a posterior circulation event, nor evidence for cortical language disturbance. Although the dysphagia and dysarthria were typical for mandibular dislocation, the presentation was misleading, especially the

absence of a known precipitating event and lack of pain as a prominent feature, resulting in delayed diagnosis and treatment. Clinicians must keep in mind that dysarthria and dysphagia may result from mechanical or traumatic causes, as well as the anticipated or usual acute and chronic neurological disorders.

Cynthia L. Coulter, MD
Department of Neurology
Creighton University Medical School
601 N 30th St
Suite 5300
Omaha, NE 68131
Alan M. Kaneshige, MD
Tulsa, Okla
William M. Wyatt, DDS
Omaha

1. Luyk NH, Larsen PE. The diagnosis and treatment of the dislocated mandible. *Am J Emerg Med.* 1989;7:329-335.
2. Meldon SW, Bonadio WA. An unusual cause of acute dysphagia and trismus in a child. *Pediatr Emerg Care.* 1994;10:163-165.
3. Cope MR, Lawlor MG. An unusual mandibular dislocation. *Br J Oral Maxillofac Surg.* 1985;23:112-117.
4. Sosis M, Lazar S. Jaw dislocation during general anaesthesia. *Can J Anaesth.* 1987;34:407-408.
5. Bradshaw RB. Perphenazine dystonia presenting as recurrent dislocation of the jaw. *J Laryngol Otol.* 1969;83:79-82.
6. Merrill RG. Habitual subluxation and recurrent dislocation in a patient with Parkinson's disease: report of case. *J Oral Surg.* 1968;26:473-477.

Physician-Assisted Suicide

Physician-assisted suicide goes against the traditional healing role of the physician and, as pointed out by Bernat,¹ is likely to undermine the patient-physician relationship. It is clear that physicians, as a group, are divided in their willingness to assist suicide: 375 (40%) of 938 physicians in Washington State were willing to assist a patient to commit suicide, but 366 (39%) of 938 held that assisted suicide is never ethically justified.² With the reports³ from the Netherlands that involuntary euthanasia has followed the legalization of voluntary euthanasia, concern will increase among patients as to what would happen to them if they became too ill to participate in end-of-life decisions. Physicians are unlikely to discuss their ethical views with patients, but patients will increasingly want to know their physicians' stand on euthanasia and assisted suicide.

One way to address this is for physicians to document their stand on euthanasia and assisted suicide and have this accessible for public review. I have set up a Web site to determine whether physicians who are against assisted suicide and euthanasia are interested in jointly documenting their position on these issues (<http://www.wp.com/JMV/Anti-Euthanasia>).

Patrick Pullicino, MD, PhD
Department of Neurology
Buffalo General Hospital
100 High St
Buffalo, NY 14203

1. Bernat JL. Physician-assisted suicide should not be legalized. *Arch Neurol.* 1996; 53:1183-1184.

2. Cohen JS, Fihn SD, Boyko EJ, Jonsen AR, Wood RW. Attitudes toward assisted suicide and euthanasia among physicians in Washington State. *N Engl J Med.* 1994;331:89-94.
3. van der Maas PJ, van der Wal G, Haverkate I, et al. Euthanasia, physician-assisted suicide, and other medical practices involving the end of life in the Netherlands, 1990-1995. *N Engl J Med.* 1996;335:1699-1705.

To Be or Not to Be? That Is the Question Facing Many Neurology Residency Programs

Less than half of neurology residency positions are currently filled by graduates of US medical schools. The clinical emphasis in neurology has switched from the inpatient to the outpatient arena. Most hospitals are experiencing strong financial pressures to reduce residency positions. Recent changes in federal health care requirements for payments to teaching physicians have decreased the advantage of seeing patients with residents. These factors may evoke a sense of pessimism regarding the future of academic neurology and should make many neurology residency programs question the necessity for and viability of their existence.

Indeed, many graduate medical education programs in neurology are unlikely to survive long into the 21st century unless some change occurs. The magnitude of change necessary to allow the survival of many of these programs may be smaller than expected. First, any notion regarding a critical mass of neurology residents should be discarded. Quality, not quantity, should be the "gold standard" for residency review committees making accreditation decisions. A residency program that produces 1 quality neurologist every 2 or 3 years should be considered adequate. Second, neurology residency programs with limited numbers of neurology residents must be allowed to give up their inpatient ward service without risk of losing their accreditation. Appropriate resident coverage of neurology inpatient beds is not possible when there might only be 1 or 2 residents in an entire program at any particular time. Neurology residents can learn the appropriate and necessary clinical skills in the outpatient clinics and on an inpatient neurology consult service. These 2 changes would allow the 50% to 75% less competitive neurology residency programs to survive. Without these 2 changes, many neurology residency programs will die.

Should less competitive neurology residency programs survive? Absolutely. Neurology residents are an essential ingredient in maintaining a true academic spirit within neurology departments at university medical centers. The loss of a large number of academic departments of neurology at many of this nation's university medical centers would ultimately have a significant detrimental impact on the patient populations that they serve. The downsizing of many neurology residency programs is necessary in our current health care environment, should be encouraged