

SHORT REPORT

## Cerebellar mutism with subsequent dysarthria in an adult: case report

G. W. DUNWOODY, Z. S. ALSAGOFF & S. Y. YUAN

*Division of Neurosurgery, National University Hospital, Singapore*

### Abstract

An adult case of mutism and subsequent dysarthria after posterior fossa surgery is presented. An EEG performed during the mute phase showed widespread left hemisphere abnormality although the CT findings were normal. The possible mechanisms underlying this syndrome are discussed.

**Key words:** EEG abnormality, mutism, posterior fossa surgery

### Introduction

Transient mutism has been reported in children undergoing posterior fossa surgery for excision of intrinsic tumours.<sup>1,2</sup> Typically, the child develops mutism several hours to a few days after surgery, and seems apathetic and withdrawn. Gradually, speech returns, but initially it is dysarthric and eventually recovers to normal over 3-8 weeks. This syndrome is usually associated with surgery for excision of midline intrinsic tumours, typically medulloblastoma.<sup>1</sup> Mutism with subsequent dysarthria (MSD) has rarely been reported in adults.<sup>3,4</sup> We describe a case and discuss the possible mechanisms underlying this syndrome.

### Case report

A 53-year-old Chinese male presented with acute onset of headache, vomiting and slurred speech. He had a past history of hypertension. On admission he had mild right-sided cerebellar ataxia and some slight slurring of speech. CT performed on admission and MRI subsequently (Fig. 1) showed an intracerebellar haematoma in the vermis and bilateral paravermian region particularly on the right. Angiography showed an arteriovenous malformation (AVM) arising from a distal branch of the superior cerebellar artery on the right (Fig. 2).

The patient required a VP shunt for hydrocephalus 4 days after admission, but was well enough to undergo definitive excision of the AVM

on day 19 at which time speech was slurred, but otherwise normal. At operation an AVM involving the superior third of the right side of the cerebellar vermis was excised without complication. The procedure was prolonged and postoperatively the patient was electively ventilated. After weaning from the ventilator the next day he was noted to be mute although he understood commands. In addition he had severe weakness of the right arm.

The initial clinical impression was of a left hemisphere cerebral vascular accident (CVA). However, CT performed post operatively (Fig. 3) did not show any evidence of infarction. Within 3 days the arm began to recover and rapidly regained normal strength although it was very ataxic. However, he remained mute for 3 weeks and when his speech returned it was very dysarthric and staccato in nature. This took some weeks to recover but when reviewed 2 months postoperatively it had returned to normal. He remained, however, moderately ataxic. An EEG performed during this prolonged mute phase showed widespread abnormality in the left frontal and temporal region with widespread left hemisphere slow waves (Fig. 4).

Postoperative angiography confirmed complete excision of the AVM.

### Discussion

This patient displayed the clinical features of what has been described as cerebellar mutism with subsequent dysarthria (MSD) syndrome.<sup>1-5</sup>

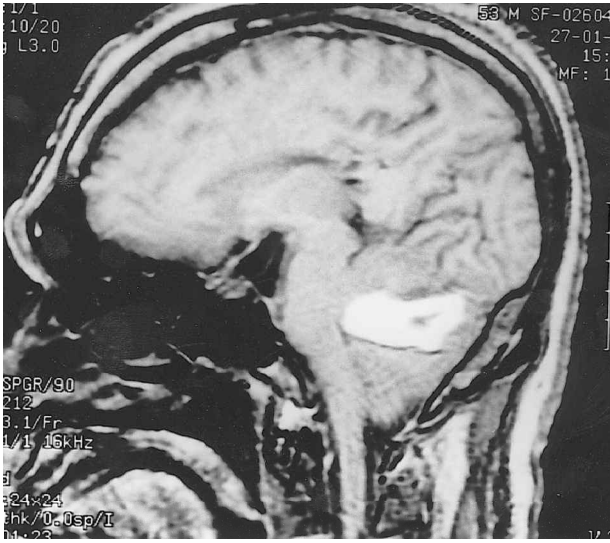


FIG. 1. MRI scan showing haematoma in superior cerebellar vermis.

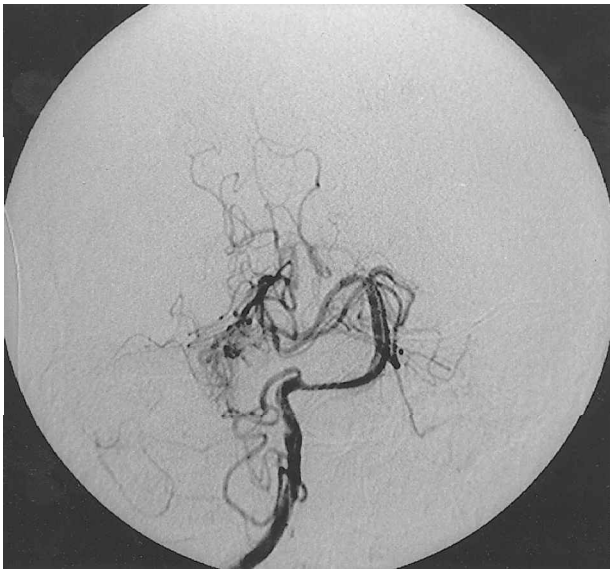

FIG. 2 Angiography showing AVM of distal superior cerebellar artery.

The mechanism of production of this syndrome is not clearly understood. The role of the cerebellum in speech has long been recognized; Gordon Holmes described lesions of the cerebellar vermis associated with dysarthria in 1922.<sup>6</sup> The superior vermis has been particularly implicated in the production of dysarthria.<sup>7</sup> However, mutism is also described after surgical lesions of the pons<sup>8</sup> and of the dentate nucleus after bilateral stereotactic lesions.<sup>9</sup>

A patient described by Silveri *et al.*<sup>10</sup> had a right cerebellar infarct which was heralded at onset with mutism for several hours followed by dysarthria, but associated with agrammatic speech suggesting a lesion more commonly associated with Broca's area. This patient had a SPECT scan showing decreased perfusion throughout the whole left hemisphere. Previous reports of MSD have predominantly been

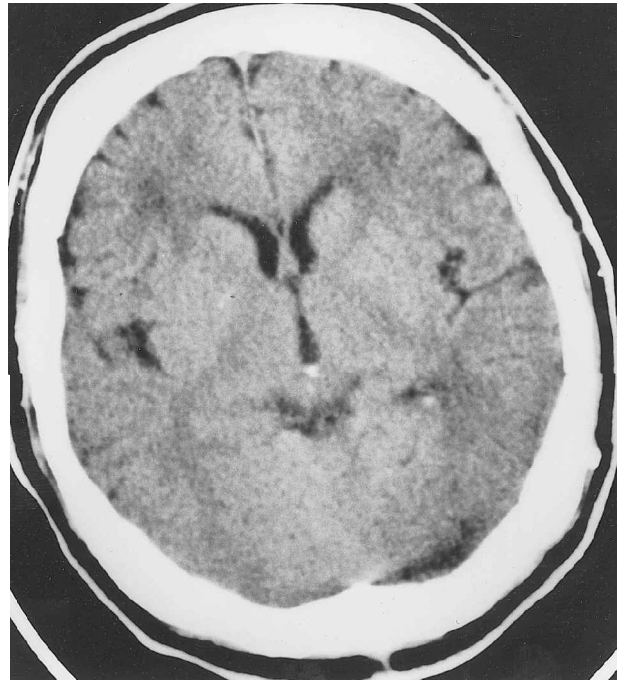


FIG. 3. Plain CT obtained during mute phase.

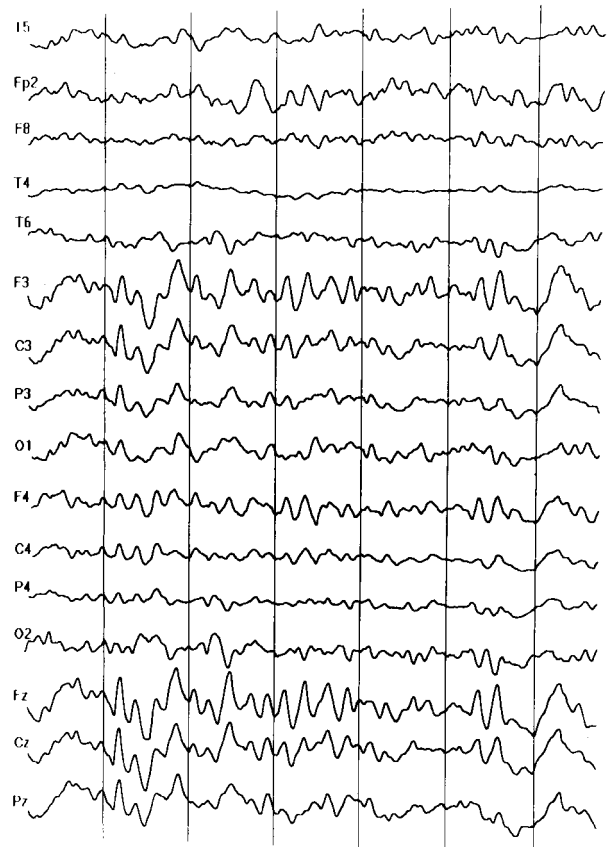


FIG. 4. EEG performed during mute phase showing widespread left hemisphere slow waves.

in childhood. Van Dongen *et al.*<sup>1</sup> describe five cases of MSD after excision of intrinsic posterior fossa tumour and refer to 36 other cases in the literature. Interestingly, all five of their c

bellar and pyramidal signs in limbs and trunk after surgery, having been normal beforehand. These tumours were all medial in position and four of five were medulloblastomas.

Van Dongen *et al.* suggested that a ventricular location, presumably the roof of the 4th ventricle, and adherence to the dorsal brainstem were necessary for MSD to occur, that it occurs in association with a spectrum of severe neurological deficits and that it may be due to bilateral dysfunction of the denticulothalamic fibre bundles or their cells of origin.

The time course of onset of this syndrome is described as a few hours to a few days after surgery.<sup>12</sup> Our patient was electively ventilated post-operatively, thus we are unable to say if a period of normal speech intervened before the onset of mutism. The EEG finding suggests that in our case the syndrome was produced not solely from local injury to the cerebellum (although an anatomical site of injury in the superior vermis or along the cerebellar dentothalamocortical pathway may be a prerequisite for production of the abnormality), but from some distant hemispheric disturbance provoked by the injury. The time course for developing the syndrome suggests an abnormality due to either oedema or some disturbance in cerebral blood flow as might be seen in vasospasm. The condition, however, is much more prolonged in its clinical course than is seen in vasospasm after subarachnoid haemorrhage and appears anatomically confined to one vascular territory.

With evidence of disturbed blood flows in the left hemisphere after surgery to the superior cerebellum it is interesting to speculate whether pretreating patients about to undergo surgery such as ours with nimodopine might ameliorate or prevent the development of the condition.

Diaschisis or transient contralateral hypo-

metabolism of the cerebellum after lesions of the cerebral hemisphere is well documented with PET studies.<sup>11</sup> Whether this phenomenon occurs in reverse, that is transient hypometabolism of the contralateral cerebral hemisphere after lesions of the cerebellum, is not known.

## References

- 1 Van Dogen HR, Catsman-Berrevoets CE, Van Mourik M. The syndrome of cerebellar mutism and subsequent dysarthria. *Neurology* 1994;44:204–6.
- 2 Ferrante L, Mastronardi L, Acqui M, Fortuna A. Mutism after posterior fossa surgery in children—report of 3 cases. *J Neurosurgery* 1997;72:959–63.
- 3 Cakir Y, Karakisi D, Kocanaogullari O. Cerebellar mutism in an adult: case report. *Surg Neurol* 1994;41:342–4.
- 4 Salvati M, Missori P, Lunard P, Orlando R. Transient cerebellar mutism after posterior fossa cranial surgery in an adult. Case report and review of the literature. *Clin Neurol Neurosurg* 1991;93:313–16.
- 5 Cole M. The foreign policy of the cerebellum. *Neurology* 1994;44:2001–5.
- 6 Holmes G. The Croonian Lecture: the clinical symptoms of cerebellar disease and their interpretation. *Lancet* 1922;ii:59–65.
- 7 Barth A, Bogousslavsky J, Regti F. The clinical and topographic spectrum of cerebellar infarction; a clinical—magnetic imaging correlation study. *Ann Neurol* 1993;33:451–6.
- 8 Frim DM, Ogilvy CS. Mutism and cerebellar dysarthria after brain stem surgery. Case report. *Neurosurgery* 1995;36:854–7.
- 9 Fraioli B, Guidetti B. Effects of stereotactic lesions of the dentate nucleus of the cerebellum in man. *Appl Neurophysiol* 1975;38:81–90.
- 10 Silveri MC, Leggio MG, Molinari M. The cerebellum contributes to linguistic production; a case of agrammatic speech following a right cerebellar lesion. *Neurology* 1994;44:240–6.
- 11 Pantano P, Baron JC, Samson Y, Bousser MG, Derouesne C, Comar D. Crossed cerebellar diaschisis. Further studies. *Brain* 1986;109:677–94.