



## Clonic Perseveration Following Thalamofrontal Disconnection: A Distinctive Movement Disorder

Victor S. C. Fung, John G. L. Morris, †Jonathan Leicester, \*Y. S. Soo, and †Llewelyn Davies

*Department of Neurology and \*Radiology, Westmead Hospital, and †Department of Neurology, Royal Prince Alfred Hospital, Sydney, New South Wales, Australia*

**Summary:** We describe four patients who developed asymmetrical, rhythmic, stereotyped, and repetitive movements of the upper and lower limbs hours to days after infarction that involved the thalamus and/or basal ganglia. The movements appeared to occur spontaneously and were initially labeled as focal motor seizures, ballism, or tremor; they could, however, be induced by passive movement of the limbs. The movements most commonly observed were scratching or rubbing movements of the hands that were of such persistence as to cause trauma to the skin; in the lower limbs, the heel was run up and down the bed sheet, often until it bled. The movements were part of a syndrome characterised initially by a reduced level of consciousness and followed by aspostaneity, usually with mutism and

frontal release signs. One patient who had relatively preserved cognition and language repeated words or phrases again and again when encouraged to speak, but had no difficulty changing responses appropriately to different cues. In drawing, he overwrote each figure but could change the figure on command. The distinctive movement disorder in these patients was due to clonic perseveration. We suggest that clonic perseveration results from disconnection of prefrontal cortico–basal ganglia–thalamo–cortical loops that are important for the termination of motor plans. Clonic perseveration should be recognised as a movement disorder following thalamic lesions. **Key Words:** Clonic perseveration—Thalamus—Basal ganglia—Disconnection syndrome.

We describe four patients who developed a distinctive movement disorder following thalamic with (one case) or without (three cases) basal ganglia infarction. The movements were mistakenly categorised as focal motor seizures, tremor, or ballism by different observers. Evidence is presented that the movements were due to clonic perseveration, a motor disorder first recognised by Liepmann in 1905 (1). Cases 1 and 2 have been reported previously (2).

### CASE REPORTS

#### Case 1

A 62-year-old man presented with the acute onset of headache, drowsiness, and unsteadiness of gait.

Over 24 h he developed dysarthria, a left homonymous hemianopia, paralysis of all eye movements except abduction of the left eye, a fixed, dilated pupil and complete ptosis on the right, and ataxia of the left upper and lower limbs with mild hemiparesis and hyperreflexia. Basilar artery thrombosis with distal embolism was diagnosed and anticoagulation with heparin instituted. A cerebral computed tomographic (CT) scan performed on the day of admission showed infarction involving the dorsomedial and ventral posterolateral nuclei of the right thalamus and the right occipital lobe (Fig. 1a).

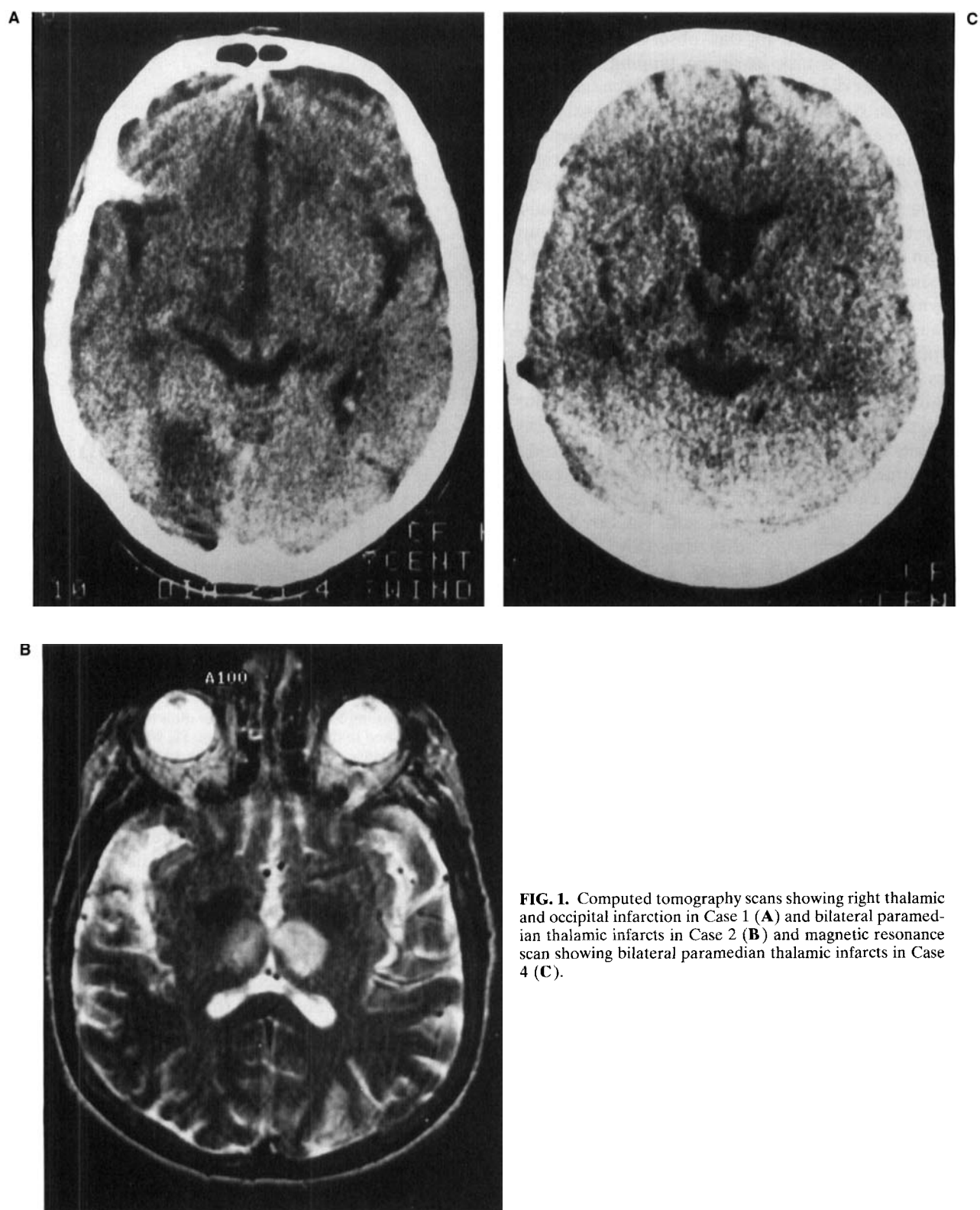
In the first week after presentation, his level of consciousness returned to normal. He was oriented, knew the name of the head of state, and was able to recognise friends and relatives. He said little unless prompted. He developed rhythmic, stereotyped, repetitive movements of the limbs that persisted for most of his waking hours. Much to the annoyance of fellow patients, he rubbed his right heel violently and noisily against the sheets. He rhythmically flexed and extended his right elbow. Similar but less vigorous

A videotape accompanies this article.

Received April 16, 1996, and in revised form August 1, 1996.  
Accepted September 7, 1996.

Address correspondence and reprint requests to Prof. J. G. L. Morris at Department of Neurology, Westmead Hospital, Sydney, NSW 2145, Australia.

This work was presented in abstract form at the 4th International Congress of Movement Disorders, Vienna, Austria, 1996.



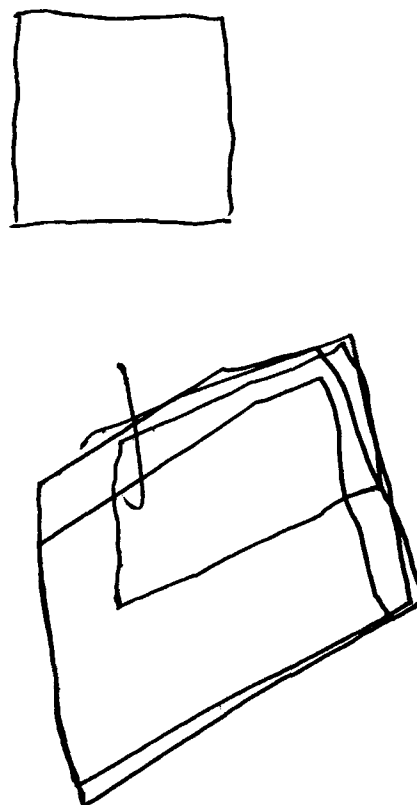
**FIG. 1.** Computed tomography scans showing right thalamic and occipital infarction in Case 1 (**A**) and bilateral paramedian thalamic infarcts in Case 2 (**B**) and magnetic resonance scan showing bilateral paramedian thalamic infarcts in Case 4 (**C**).

movements were observed on the left side. The movements were described by one observer as ballism. Asked to copy a task involving tapping the table three times, he did so, but then repeated the sequence many times. Asked to tap twice, he did so, again and again. Repetitive movements could be induced by passive movement of a limb. Moving his left or right heel up and down the bed induced heel rubbing on the right side. Flexing and extending the thumb would induce thumb movement that would persist for up to 2 min. In marked contrast to the constant repetitive movements, there was an absence of goal-directed behaviour. Grasping and groping were absent. The tendency to repeat actions was present in all modalities of motor output. There was a paucity of spontaneous speech, but he repeated words and phrases inappropriately. For example, when asked to recite the days of the week, he did so six times in the correct sequence. In answer to: "What do you notice wrong with yourself?" he replied, "Can't coordinate, can't coordinate, can't coordinate." Reading aloud the sentence "A boy had a dog," he said, "A boy had, a boy, a boy had dog . . . dog, dog, dog, dog, dog, a boy had dog, a boy had dog." At times, the patient attempted to rationalise his problem. When asked "Why do you keep repeating yourself?" he replied "So you can hear, so you can hear, so you can hear. . . ." On drawing tasks, he copied simple shapes correctly but would draw over the outline of each figure many times before proceeding to the next (Fig. 2). When offered \$0.20 for each figure that was not overdrawn, he was able to largely suppress this. Having done six figures correctly, he was given \$1.20; as he put the money in his pocket, he said, "Thank you, thank you, thank you, thank you."

### Case 2

A 48-year-old woman was admitted with subarachnoid hemorrhage from an aneurysm at the bifurcation of the basilar artery unaccompanied by neurological deficit. Following clipping of the aneurysm, the patient was drowsy and mute but moved all four limbs to command. Bilateral complete third nerve palsies were present. Her level of consciousness returned to normal over 1 week, but she made little attempt to speak and spent much of her time moaning. There was left-sided limb ataxia and decreased sensation to all modalities. She required assistance to walk.

Ten days after the operation, violent, rhythmic movements of the right arm and leg appeared. She was prescribed phenytoin because the movements



### COPY

**FIG. 2.** An example of clonic perseveration in drawing by Case 1. He was asked to draw a single square. He was unable to terminate the sequence after four penstrokes and continued to draw squares over the original figure.

were mistaken for focal motor seizures. On one occasion she scratched her nose as though it were itching; she then went on making scratching movements with the hand, eventually making no contact with her nose, for several minutes. Repetitive scratching resulted in ulceration of skin over the abdomen and lips, and her hand had to be placed in a mitten. The right heel was rubbed vigorously and rhythmically against the bed sheet, causing it to bleed. Another movement consisted of rubbing the dorsum of the right foot with the sole of the left foot. Passive movement of either leg tended to trigger the movements in the right leg. A grasp reflex and forced groping were present on the right. No abnormal motor behaviour on the left side was noted.

The movements disappeared gradually over 2 months. The patient was left with a profound short-term memory deficit and disinhibition. A cerebral CT scan performed 3 months postoperatively showed

discrete bilateral paramedian thalamic infarcts (Fig. 1b).

### Case 3

A 54-year-old right-handed woman with a previous history of left middle cerebral artery territory infarction was admitted following sudden collapse accompanied by jerking movements of the right upper and lower limbs. She had a depressed level of consciousness with a Glasgow Coma Score of 8. Pupillary size and reaction were normal, but her eyes were conjugately deviated to the right. She had spontaneous movements on the right accompanied by hypertonia and hyperreflexia; there was a flaccid left hemiplegia. Bilateral Babinski responses were present. In the emergency department, the patient was treated with intravenous phenytoin on the assumption that the movements were focal motor seizures.

Seven days later, her level of consciousness had improved significantly; she was easily rousable to voice, poorly attentive, but able to nod to command. There was no recognisable speech, but she moaned constantly. The limb movements were still present. The most prominent was a rhythmic 2- to 3-Hz incomplete opening and closing action of the right hand with the fingers and thumb extended, associated with intermittent flexion/extension of the elbow through a 45° arc. Movements of the right arm were accompanied by dystonic posturing and were initially described as tremor or choreoballism. The position of the arm varied so that at times the hand appeared to be picking noisily at the bedclothes, scratching her chest or her left forearm. The movements were of such violence and persistence that the skin over the chest and forearm became bruised and ulcerated; the hand was gloved and restrained. All abnormal movements disappeared during sleep. There was mild upper motor neurone weakness of the arms and legs, more marked on the left. Tone was increased bilaterally and *gegenhalten* in character (the more the limb was moved, the greater the resistance became). Fine finger movements and rapid alternating movements of the wrist were performed to command bilaterally, but were slow. At this stage, there was no repetition during performance of motor tasks to command; instead, when her attention wandered during the motor examination, she tended to recommence movements of the right arm as described already. She had bilateral grasp reflexes and forced groping.

Two weeks later, the patient had vigorous repetitive rubbing movements of the right hand, predomi-

nantly over the chest and forearm. The left hand usually remained still, but at times was used (unsuccessfully) in an attempt to restrain the right. Vigorous and rhythmic rubbing of the right heel against the bed sheets or dorsum of the left foot resulted in ulceration of the skin. At other times, the predominant movement in the lower limbs was alternating flexion and extension of the foot, more often on the right than the left. Varying combinations of these movements punctuated every waking hour. During this stage of her illness, it was possible to induce continuous repetitive movements with passive movement of a limb. Passive flexion and extension of the right elbow, moving the right hand to touch three points on her body in sequence, or passive flexion/extension of the left hip and knee all produced continuing cycles of the passive movement. Several cycles of a passive movement were necessary to induce the patient to continue an action. Given an object in her right hand and told to tap it twice on a board, she continued to tap a two-beat rhythm, although eventually she returned to rubbing movements over the chest.

Over the course of the next 3 weeks, the amplitude and persistence of spontaneous movements decreased. Repetition of passive movements could no longer be induced. Mentation improved with increased alertness and ability to follow commands. The patient has remained mute.

An initial cerebral CT showed old left middle cerebral artery territory infarction affecting the left frontoparietal cortex, head of the caudate nucleus, and ventral anterior nucleus of the thalamus. A repeat cerebral CT on day 6 showed recent extensive infarction of the right corona radiata, putamen, and globus pallidus. An electroencephalogram during the movements demonstrated left frontotemporal slowing but no epileptiform activity. Examination of the cerebrospinal fluid was normal.

### Case 4

A 65-year-old woman presented with headache and photophobia due to subarachnoid haemorrhage. During cannulation of the right subclavian artery for cerebral angiography, she became comatose with a left hemiplegia. The hemiplegia recovered in 20 min, and her level of consciousness improved over 2 h, but she remained confused and agitated.

Three days later, she was first noted to have abnormal movements. The patient was drowsy but easily rousable and able to obey single-step commands.

There was no spontaneous speech. Gaze was deviated upwards with limited downgaze. She exhibited an abnormal sleep/wake pattern, with periods of wakefulness, spontaneous eye opening, and irregular breathing lasting ~1 min interspersed with periods of sleep preceded by episodes of apnoea. During sleep, the patient was still. However, whenever aroused, she developed spontaneous movements. She rubbed both heels against the bed sheet in a bicycling motion. This was so persistent that protective padding over the heels was required to prevent injury to the underlying skin. She rubbed the left hand against the chest and epigastrium. Movements were under a degree of voluntary control and temporarily ceased on request.

During the following 2 weeks, the patient's level of consciousness improved further. She exhibited asponaneity with little spontaneous speech. Perseveration occurred during naming tasks. Vertical gaze remained restricted, but there were no other focal signs. She was able to walk with assistance. Abnormal leg movements were still present, but were suppressed upon command.

A cerebral CT performed on day 3 showed bilateral thalamic infarction, and cerebral magnetic resonance imaging on day 5 showed discrete bilateral paramedian thalamic and left occipital and cerebellar infarction (Fig. 1c).

## DISCUSSION

These patients had a distinctive clinical syndrome with the following characteristics:

1. There was the sudden onset of abnormal limb movements in the setting of thalamic or basal ganglia infarction.

2. The movements were rhythmic, stereotyped, and repetitive; they appeared to occur spontaneously, dominated the clinical picture, and were sometimes so violent and persistent as to cause self-injury. The commonest movements consisted of rubbing/scratching movements of the upper limb and heel or foot rubbing in the lower limb. They were often more prominent on one side and at times affected one limb, at other times another. The pattern of movement varied over intervals of minutes to days.

3. The movements could be induced by passively moving the patients' limbs, the ongoing movement always reflecting the characteristics of the passive movement. In asymmetrical cases, passive movement of the limb on the hemiparetic or ataxic side some-

times elicited a similar movement in the contralateral limb.

4. The movement disorder occurred in a setting of asponaneity usually with mutism and grasp reflexes.

5. When speech was spared, there was inappropriate repetition of words and phrases in response to a cue, with no difficulty changing the response to a new cue (although the new response would also be repeated). Similarly, figures were overdrawn repeatedly, with preservation of the ability to change the figure in response to a new command.

In each case, experienced clinicians had difficulty categorising the movements. Two patients were initially thought to have focal motor seizures. The presence of spontaneous and persistent abnormal movements in the setting of lesions of the thalamus/basal ganglia raised the possibility that the movements were tremor, ballism, or dystonia. The movements were often rhythmical and could therefore be described as tremor. A 4- to 6-Hz tremor, characterised by alternating flexion and extension at the metacarpophalangeal joints, has been described following thalamic strokes (3,4) and bears some similarities to the movements observed in Case 3. The violence and unilaterality (at times) of the movements were reminiscent of hemiballismus. In a review of 40 patients with thalamic infarction, delayed abnormal movements developed only following paramedian lesions and were postulated to be due to involvement of the subthalamic nucleus (5). The purposeful, coordinated quality of the movements in our patients and the fact that they could be induced differentiated them from focal motor seizures, tremor, or ballism. The abnormal movements were not associated with abnormal posturing suggestive of dystonia except in Case 3, who had extensive bilateral lesions of the basal ganglia. Another label that might be considered is that of stereotypy. Stereotypies are often repetitive, rhythmic, and seemingly purposeful and ritualistic, but are not triggered by external cues (6). They usually occur in the setting of autism, cerebral palsy, and syndromes causing mental retardation (7). The term has, however, been used to describe a movement disorder following right putaminal infarction (8); there are similarities between the movement disorder of our patients and stereotypy.

We believe that the movements in our patients were a form of perseveration. Perseveration was a term used by Neisser (9) to describe abnormal repetitive activity. It can be defined as the inappropriate persistence of word, thought, or action in response

to a given stimulus. Liepmann (1) recognised three types: In intentional perseveration, a previous response is repeated when, and only when, a new response is intended; in other words, it occurs only in response to a new cue. One of his patients, having blown out a candle, made a blowing action each time he was presented with a different object. Clonic perseveration describes the inappropriate repetition of an action, once initiated, in the absence of an ongoing cue; the ability to change in response to a new cue is preserved. His patient, at the end of writing a sentence, continued to write the same words over and over again. Tonic perseveration refers to persistence of a muscle contraction once initiated; Liepmann described a patient who was unable to throw away a used match. The key feature underlying much of the behaviour in our patients was the repetition of every action, both apparently spontaneous and in response to an external cue, with preservation of the ability to change the response to a new cue. Their behaviour thus conforms to Liepmann's description of clonic perseveration.

The movements we observed usually involved scratching or rubbing. It is possible that a sensation of itch or ache, common to any patient confined to bed, may have cued these movements. Once initiated, the movements continued because of the perseverative tendency. This was most apparent in Case 2 who scratched her nose as if it itched but then continued the movement even when she was no longer making contact with her face (see videotape segment 2). A striking feature was that passively moving the patients' limbs also set off the perseveration. It was usually necessary to put the limb through a sequence of movement several times before the behaviour was induced; it is possible that, after the first cycle or two, the patient "assisted" us, converting it to an active movement. Whatever the mechanism, we find the ability to induce repetition of novel movements a useful diagnostic tool for determining whether an apparently involuntary movement disorder is due to clonic perseveration. This is of particular use in patients who are mute or unable to cooperate fully with other tests of perseveration.

Since Liepmann's classification of clonic perseveration (1), a number of different terms have been applied to similar perseverative motor phenomena, including "efferent motor perseveration" (10), "hyperkinesia-like motor perseveration" (11), and "continuous perseveration" (12). Luria (10) suggested that efferent motor perseveration was usually observed with "massive injury to the frontal lobes,

extending to the subcortical motor ganglia." The thalamus was involved in all of our patients, and in three, basal ganglia or frontal pathology was absent. In the fourth patient (Case 3), perseveration was most prominent on the side contralateral to the old thalamic lesion, but ipsilateral to the recent basal ganglia infarct. To our knowledge, clonic perseveration has not been ascribed previously to thalamic lesions.

Only one group of patients has been reported with features similar to our own. In a recent comprehensive review of 62 cases of movement disorders following thalamic or subthalamic lesions (13), 5 patients with unusual movements following paramedian thalamic infarction were identified, all of whom were reported by the same authors (14). As with three of our patients, there was accompanying disturbance in level of consciousness and signs of midbrain pathology. The movements appeared after a delay of 3 weeks to 9 months. Interestingly, in four of the cases, they were described as "repetitive clonic or slow . . . movements mainly affecting one or both arms" and in the other as "clonic movements of the head and eyes" (13). Patient 3 (14) had "rhythmic flexion-extension movements of the feet." Patient 13, some days after an acute vascular insult, "began to mutter and incessantly repeat the same fragment of prayers; . . . over the succeeding months some movement returned, but it was limited and stereotyped." It seems likely that the basis of the movement disorder in some of these patients was clonic perseveration.

Why did our patients develop clonic perseveration following thalamic or basal ganglia lesions? Motor programming abnormalities usually occur as part of the dorsolateral frontal syndrome (15). Current theories of basal ganglia function postulate that there are parallel circuits that form cortico-basal ganglia-thalamo-cortical loops (16,17). The major thalamic relays of the dorsolateral prefrontal loop are the ventral anterior and medial dorsal nuclei. Interruption of dorsolateral prefrontal projections at the thalamic level may have been the basis for clonic perseveration in our patients. Aspontaneity and mutism, features more characteristic of lesions involving the limbic (anterior cingulate) rather than dorsolateral cortex (15), were also prominent features in our patients. However, this is not surprising as the medial dorsal nuclei also form part of the limbic loop; discrete syndromes corresponding to those seen with cortical lesions do not occur following frontal disconnection resulting from thalamic lesions (15). Of note is that bilateral signs or pathology were present in all our

patients; this may be a prerequisite for the development of clonic perseveration.

Various authors have studied perseveration and speculated on the underlying mechanisms (1,10,18–24), but its physiological basis remains unknown. Marsden and Obeso (25) have recently reviewed the functions of the basal ganglia and suggested that the pallidum/substantia nigra may be a site where inputs from both motor and nonmotor corticostriatal pathways interact as part of normal motor control. Neuronal systems that are involved in terminating movement have been described. Brochie et al. (26) have identified cells in the globus pallidus that exhibit phasic bursting 200–300 ms prior to the end of single or sequential wrist movements. They suggested that this activity was “appropriately timed to terminate sustained neuronal activity in the [supplementary motor area] and allow the next movement in the sequence to be executed” and that “phasic activity in pallidal cells may be the internal cue used by the motor system to switch between motor programs.” The precise cortical innervation of these pallidal cells is not known. We postulate that failure of internal cues used to terminate more complex motor plans, as opposed to individual components of a movement, may be the basis of clonic perseveration. Preservation of the ability to switch tasks may relate to retention of the capacity to utilise external cues to generate new motor programs.

In summary, a distinctive movement disorder in the setting of mutism and frontal release signs is described in patients following infarction of the thalamus. The movements may be induced by passive movement and can be considered to be a form of perseveration.

**Acknowledgment:** Dr. Fung is the recipient of a Medical Postgraduate Scholarship from the National Health and Medical Research Council of Australia. We thank Susan Morris for her assistance in preparing this manuscript and Dr. Con Yiannikas for allowing us to study his patient.

### LEGENDS TO VIDEOTAPE

**Segment 1. Case 2.** Spontaneous movements in the right upper and lower limbs and continuous moaning. Note that (a) the movements temporarily cease when her hand is held gently and (b) the phenomenology of the movements varies from minute to minute.

**Segment 2. Case 2.** The patient is initially scratching her nose, but the scratching movements continue even though her fingers are no longer in contact with her skin; the ongoing movement could easily be mis-

interpreted as tremor. Note the healing wound on her left upper lip where persistent scratching had traumatised the skin.

**Segment 3. Case 2.** The patient had been rubbing the dorsum of her right foot against the sole of her left; passive rubbing of her right heel against the bed sheet induced ongoing heel rubbing, although she was given no instruction to continue the movement. Passive movement of her ataxic left lower limb induced repetitive movements in her contralateral limb.

**Segment 4. Case 1.** Motor perseveration induced by passive movement of a limb, drawing, and tapping.

### REFERENCES

1. Liepmann H. Die perseveration. In: Liepmann H, ed. *Ueber Storungen des Handelns bei Gehirnkrankeiten*. Berlin: Karger, 1905:115–27.
2. Morris JGL, Leicester J. Clonic perseveration. *Clin Exp Neurol* 1987;23:39–45.
3. Kim JS. Delayed onset hand tremor caused by cerebral infarction. *Stroke* 1992;23:292–4.
4. Ferbert A, Gerwig M. Tremor due to stroke. *Mov Disord* 1993;8:179–82.
5. Bogousslavsky J, Regli F, Uske A. Thalamic infarcts: clinical syndromes, etiology, and prognosis [published erratum appears in *Neurology* 1988;38:1335]. *Neurology* 1988;38:837–48.
6. Lees AJ. *Tics and related disorders*. 1st ed. Edinburgh: Churchill Livingstone, 1985:122.
7. Jankovic J. Stereotypies. In: Marsden CD, Fahn S, eds. *Movement disorders 3*. Oxford: Butterworth-Heinemann, 1994: 503–17.
8. Maraganore DM, Lees AJ, Marsden CD. Complex stereotypies after right putaminal infarction: a case report. *Mov Disord* 1991;6:358–61.
9. Neisser A. Krankenvorstellung (Fall von ‘Asymbole’). *Allg Z Psychiatr* 1895;51:1016–21.
10. Luria AR. Two kinds of motor perseveration in massive injury of the frontal lobes. *Brain* 1964;88:1–10.
11. Goldberg E, Tucker D. Motor perseveration and long-term memory for visual forms. *J Clin Neuropsychol* 1979;1:273–88.
12. Sandson J, Albert M. Varieties of perseveration. *Neuropsychologia* 1984;22:715–32.
13. Lee MS, Marsden CD. Movement disorders following lesions of the thalamus or subthalamic region. *Mov Disord* 1994;9:493–507.
14. Castaigne P, Lhermitte F, Buge A, Escourolle R, Hauw JJ, Lyon-Caen O. Paramedian thalamic and midbrain infarcts: clinical and neuropathological study. *Ann Neurol* 1981; 10:127–48.
15. Cummings JL. Frontal-subcortical circuits and human behavior. *Arch Neurol* 1993;50:873–80.
16. Alexander GE, DeLong MR, Strick PL. Parallel organisation of functionally segregated circuits linking basal ganglia and cortex. *Annu Rev Neurosci* 1986;9:357–81.
17. Alexander GE, Crutcher MD. Functional architecture of basal ganglia circuits: neural substrates of parallel processing. *Trends Neurosci* 1990;13:266–71.
18. Jasper HH. Is perseveration a functional unit participating in all behaviour processes? *J Soc Psychol* 1931;2:28–51.

19. Goldberg E. Varieties of perseveration: a comparison of two taxonomies. *J Clin Exp Neuropsych* 1986;8:710–26.
20. Sandson J, Albert ML. Perseveration in behavioural neurology. *Neurology* 1987;37:1736–41.
21. Wilson SAK, Walshe FMR. The phenomenon of “tonic innervation” and its relation to motor apraxia. *Brain* 1914;37:199–246.
22. Shahani B, Burrows P, Whitty CWM. The grasp reflex and perseveration. *Brain* 1970;93:181–92.
23. Freeman T, Gathercole CE. Perseveration. The clinical symptoms in chronic schizophrenia and organic dementia. *Br J Psychiatry* 1966;112:27–32.
24. Hudson AJ. Perseveration. *Brain* 1968;91:571–82.
25. Marsden CD, Obeso JA. The functions of the basal ganglia and the paradox of stereotaxic surgery in Parkinson's disease. *Brain* 1994;117:877–97.
26. Brotchie P, Iansek R, Horne MK. Motor function of the monkey globus pallidus. 2. Cognitive aspects of movement and phasic neuronal activity. *Brain* 1991;114:1685–702.