

Y.-T. Cheng, C.-T. Huang, H. S. Leu, J.-S. Chen, M.-C. Kiu

Central Nervous System Infection due to *Clostridium septicum*: A Case Report and Review of the Literature

Summary: A patient with end stage breast cancer was admitted to hospital due to fever, chills, multiply eroded discharging wounds, and sudden onset of left hemiparesis. *Clostridium septicum* bacteremia and brain abscess were diagnosed. The patient was treated successfully with intravenous penicillin and clindamycin and stereotactic aspiration of the abscess. Eleven cases of *C. septicum* central nervous system infection are reviewed. They showed an extremely fulminant course and high fatality. Nevertheless, some relationship seems to exist between outcome and type of brain lesion. Hemolytic-uremic syndrome associated with central nervous system infection is also discussed, because all these cases in the literature were due to this organism. Early diagnosis and aggressive treatment, including surgical drainage and appropriate antibiotics, are the key to improving the prognosis. A long-term prophylactic oral antimicrobial agent is suggested for patients who survive this infection.

Introduction

Clostridium septicum, an anaerobic gram-positive rod commonly associated with gas gangrene and malignancy, is a rare cause of central nervous system (CNS) infection. We present a case of breast cancer with *C. septicum* bacteremia and brain abscess which has never been reported before, and review 11 previous case reports of this infection.

Case Report

A 40-year-old female was treated with modified radical mastectomy in 1990 for left breast cancer. Metastatic lymph nodes developed over the left neck and right axillary regions 6 months later. Two courses of chemotherapy (cyclophosphamide, mitomycin and 5-FU) and local radiotherapy were performed. Recurrent metastatic lymph nodes of the left neck and multiple cutaneous nodules of the left anterior chest wall were noted in January 1994. Three courses of chemotherapy and palliative local radiotherapy to the left side of the neck and bilateral anterior chest wall were performed. Painful swelling and perforation of the left neck mass occurred after radiotherapy.

Sudden onset of left side weakness with fever and chills occurred on 8 October 1994. On physical examination, the patient was oriented and alert, but febrile (38.5°C) and tachypneic (24 times/min). Her neck was supple, but with a very large eroded discharging left neck lymph node (about 5×6 cm² in size). Besides, two big and deep ulcerated wounds, surrounded by multiple small cutaneous nodules, were noted over the right anterior chest wall with foul purulent discharge. Neurological examination revealed right central facial palsy and hemiparesis. Her white cell count was 9,500/mm³ (94% segments and 1% band forms), hematocrit was 37% and platelet count was 22,900/mm³. Further laboratory tests, including liver and renal function, were normal.

Computerized tomography (CT) of the brain showed a white matter swelling over the left frontal-parietal region (Figure 1). Suspecting brain metastasis, lumbar puncture was not carried out. After two sets of blood cultures were drawn, she was treated empirically with cephalothin and gentamicin intravenously

for probable sepsis. Intravenous penicillin was added later due to persistent fever and probable aspiration pneumonia suggested by chest X-ray. Magnetic resonance imaging (MRI) of the brain, performed on day 5 after admission, revealed a space occupying lesion over the left frontal-parietal region (Figure 2). On day 7 after admission, *C. septicum* was isolated from the blood cultures which was susceptible to ticarcillin, chloramphenicol, cephalothin, erythromycin, clindamycin, piperacillin, moxalactam, penicillin, tetracycline and metronidazole. Treatment was changed to combination therapy with penicillin and clindamycin, but the patient was still febrile after 6 days of the combination therapy. A neurosurgeon was consulted and stereotactic biopsy of the brain lesion was performed on 21 October 1994, day 13 after admission. Twenty ml of brisk pus-like fluid was aspirated and the result of culture also showed *C. septicum* with the same susceptibility test as blood culture.

After stereotactic aspiration, fever subsided gradually. A total of 6 weeks of combination antibiotic therapy was completed, and the follow-up computerized tomography of the brain showed resolution of the brain abscess. The patient was discharged on 29 November 1994, day 53 after admission, in a stable condition but with mild left side hemiparesis.

Two months later, she was admitted again due to superior vena cava syndrome and severe dyspnea. Despite treatment with two courses of NLF (mitoxanthrone, leucovorin and 5-Fu) with intravenous dexamethasone, her condition deteriorated rapidly. She was discharged in a critical state against advice on 23 March 1995 and died at home on the same day.

Received: 1 July 1996/Revision accepted: 25 September 1996

Y.-T. Cheng, M. D., C.-T. Huang, M. D., H.-S. Leu, M. D., Div. of Infectious Diseases; J.-S. Chen, M. D., M.-C. Kiu, M. D., Div. of Oncology, Dept. of Internal Medicine, Chang Gung Memorial Hospital, 199 Tun Hwa North Road, Taipei, Taiwan, Republic of China.

Reprint requests to: Dr. H.-S. Leu.

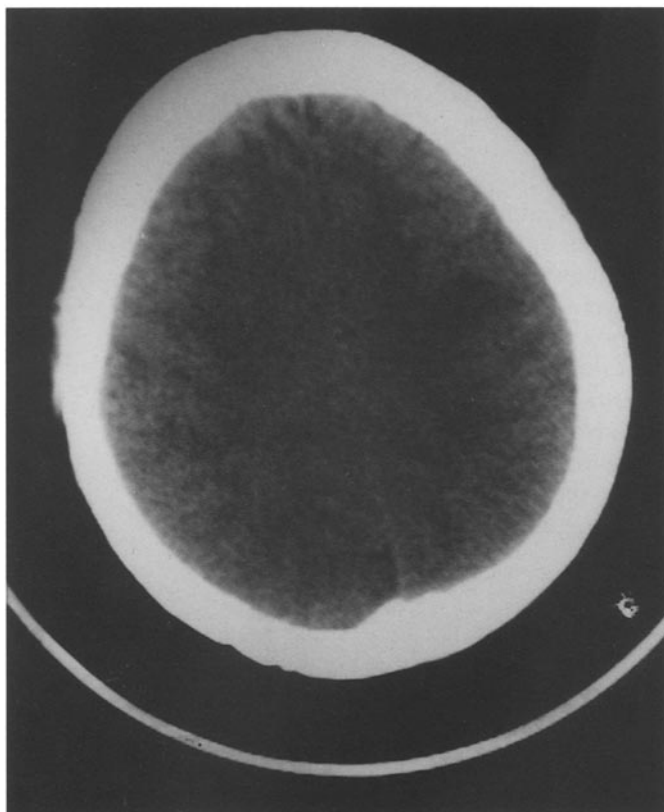


Figure 1: Brain CT showing white matter swelling over left frontal-parietal region.

Discussion

C. septicum, first isolated by Louis Pasteur 100 years ago [1], is an exotoxin-producing, strictly anaerobic, and spore-forming gram-positive bacillus. The major toxin produced by *C. septicum* is alpha toxin, which is lethal, necrotizing, hemolytic and possibly leukocidic [2]. Invasive infections due to *C. septicum* include muscular necrosis and abscess formation in solid organs [3]. Such infections are usually fulminant and spontaneous without obvious infectious focus. Malignancies, including colonic adenocarcinoma and leukemia, or non-malignant hemotologic disorder were reported to be associated closely with *C. septicum* infection [4–6]. Damage of the bowel wall, particularly in the distal ileum or ascending colon, was presumed to be the portal of entry of *C. septicum* [7, 8]. The antibiotic most widely used for this infection was penicillin, but cephalothin, carbencillin, chloramphenicol, clindamycin and metronidazole have been used alternatively [9]. Due to the high risk of recurrent infection, life-long prophylactic oral penicillin was suggested [10]. The mortality rate was as high as 50 to 70% [7].

With the improved techniques for identifying anaerobic pathogens, *C. septicum* infection has been recognized more often in recent years. However, CNS infection due to this organism is still rare. In our literature review, only 12 patients were retrieved (Table 1). Their ages ranged from 16 months to 85 years. Eight were males and three

were females. Among these 12 patients, six (50%) were associated with malignant diseases and the other six cases had non-malignant hematologic disorders. Three of 12 (25%) patients had occult colonic adenocarcinoma. The clinical manifestations were fever, chills, pain in the extremities, and variable neurological symptoms, including facial twitching, seizure, hemiparesis, and confusion. There were two types of CNS lesion in these 12 cases: four (33%) brain abscesses and eight (67%) hemorrhagic, necrotizing, and gas-forming cerebritis. A high rate of positive blood cultures is noted. The antibiotics used were varied. Penicillin, combined with various antibiotics, was most common. Eight of 12 (67%) died directly due to this infection, and the other four (33%) survived. The mean duration from the onset of symptoms to mortality was 77 h. Colorectal lesions were found in eight of nine (89%) patients who were examined by autopsy.

Hemolytic-uremic syndrome (HUS) is a clinical entity consisting of acute microangiopathic hemolytic anemia, thrombocytopenia, and oligouric renal failure. Complications in the gastrointestinal tract (emesis, diarrhea and cramping abdominal pain) and CNS (seizure, stroke and cerebral hemorrhage) are common and considered to be due to systemic vasculopathy [3, 7, 11]. HUS-associated CNS infection is extremely rare. In our literature review, four cases were reported, all of which were due to *C. septicum* (as presented in Table 1) [3, 7, 9, 11]. HUS-related colitis is presumed to play a key role in the entity [3, 7, 11]. Frequent neurologic manifestations related to HUS make it difficult to find *C. septicum* CNS infection early. Therefore, when neurologic symptoms develop in HUS, CNS infection due to *C. septicum* should be considered.

In the review of the literature, we found a close relationship between the outcome and the type of CNS lesion. The patients with documented cerebritis or meningoencephalitis presented an extremely fulminant course. All of them died within 3 days, some even within several hours. On the other hand, four patients with brain abscess formation exhibited a relatively benign course and had the chance to receive surgical therapy.

Bacteremia and CNS infection due to *C. septicum* associated with breast cancer is reported for the first time in this article. The possibility of CNS metastasis often causes confusion and makes early diagnosis impossible. However, for a cure, we should remain highly suspicious of *C. septicum* CNS infection when neurologic symptoms develop in patients with underlying malignant diseases.

According to the literature, penicillin is the preferred antibiotic for this infection, and its minimal inhibition concentration is among the lowest [9]. Combination therapy with gentamicin, cephalothin, clindamycin or metronidazole was common. The suggested length of antibiotic therapy was 4–6 weeks [10, 11]. However, the effectiveness of combination therapy is still uncertain. Further study is needed on this issue.

In conclusion, when infections associated with neurological symptoms and signs develop in a patient with malign-

Table 1: Summary of patients with CNS infections due to *Clostridium septicum*.

Case	Age	Sex	Underlying condition	Clinical condition	Type of CNS lesion	Blood culture	Therapy	Outcome	Duration of therapy	Colonic lesions (demonstrated by autopsy)
1 [4]	32 years	M	Myelogenous leukemia	Fever, N/V and abdominal pain	Meningitis (?)	Pos	P, C, M	Survived	(?)	None
2 [12]	73 years	F	Colonic carcinoma	Fever and right hemiparesis	Cerebritis with gas	Pos	G, CTZ	Died	4 h	Ulceration and necrotizing polyps
3 [6]	33 years	M	Splenectomized for aplastic anemia	Fever, right leg myonecrosis	Cerebritis with gas	Pos	To, E	Died	36 h	None
4 [6]	76 years	M	Occult colonic carcinoma	Fever, diarrhea and mental confusion	Cerebritis with gas	Pos	AM	Died	14 h	Perforation with pericolic abscess
5 [9]	16 months	M	HUS	Bloody diarrhea, fever and seizure	Cerebritis with gas	(?)	AM, G, CC	Died	1 day	Massive necrosis
6 [13]	67 years	F	Occult rectal carcinoma	Fever, diarrhea and confusion	Meningoencephalitis with gas	Pos	(?)	Died	several h	Necrotic rectal tumor
7 [10]	71 years	M	MDS	Fever, confusion and myonecrosis	Brain abscess	Pos	P, CTZ, CC	Survived	6 weeks	None
8 [14]	85 years	M	Occult carcinoma of the caecum	Fever, left weakness and confusion	Brain abscess	Pos	P, MET, aspiration	Died	16 days	Multiple tumors
9 [3]	4 years	M	HUS	Bloody diarrhea, seizure and coma	Meningoencephalitis with gas	Pos	(?)	Died	70 h	Microangiopathy with necrosis
10 [7]	2 years	F	HUS	Fever, vomiting, diarrhea and seizure	Cerebritis and meningitis	Pos	P, MET	Died	6 h	Transmural inflammation and necrosis
11 [11]	2 years	M	HUS	Bloody diarrhea and facial twitching	Brain abscess	(?)	P, MET, aspiration	Survived	6 weeks	None
**12	40 years	F	Breast cancer	Fever and left hemiparesis	Brain abscess	Pos	P, CC	Survived	6 weeks	None

HUS: hemolytic-uremic syndrome; MDS: myelodysplastic syndrome; N/V: nausea and/or vomiting; Pos: positive; P: penicillin; C: cephalothin; M: methicillin; G: gentamicin; CTZ: ceftazidime; To: tobramycin; E: erythromycin; AM: ampicillin; CC: clindamycin; MET: metronidazole; *: died 4 months later due to recurrent septicemia without residual brain lesion by autopsy; **: our presented case.

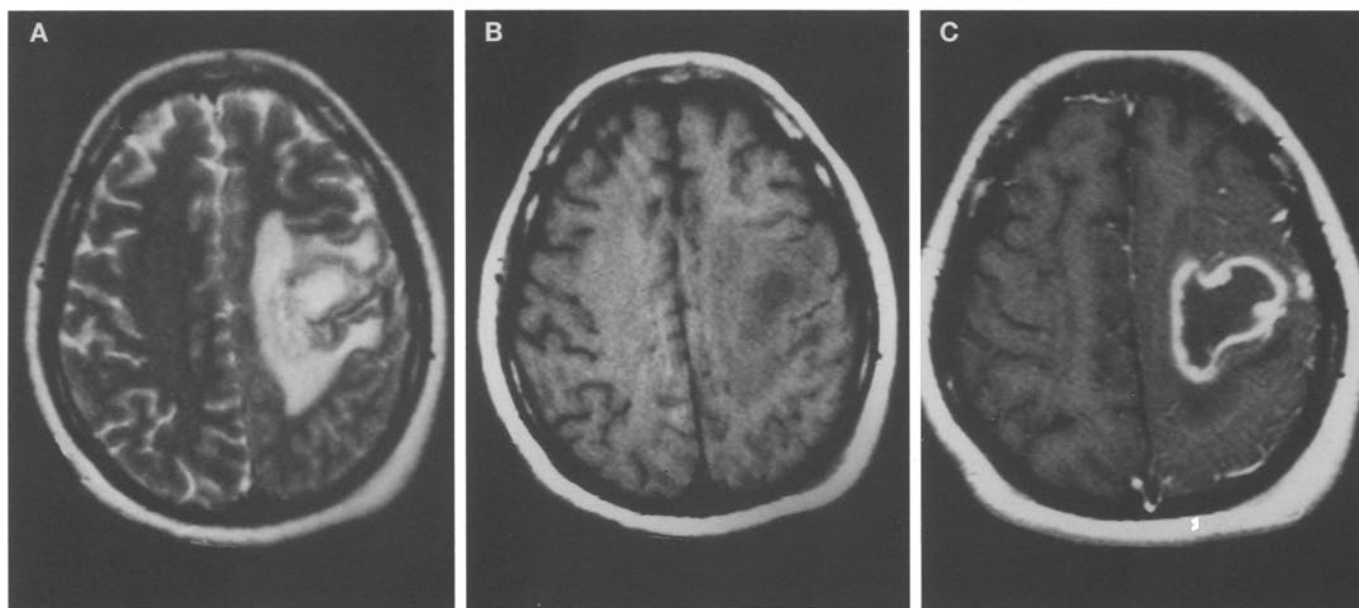


Figure 2: MRI revealing a space-taking lesion over left frontal-parietal lobe in T1 (A) and T2 (B) images and ring-like contrast enhancement with perifocal edema (C).

nancy or non-malignant hematologic disorder, *C. septicum* CNS infection should be considered. The prognosis is poor, but it may be improved by early diagnosis. The natural course of disease depends on the types of CNS lesion.

Penicillin combined with various antibiotics is the preferred medical therapy at present. If patients survive this infection, long-term prophylactic oral penicillin is indicated because of the high risk of recurrence.

References

1. MacLennan, J. D.: The histotoxic clostridial infections of man. *Bact. Rev.* 26 (1962) 177–276.
2. Johnson, S., Driks, M. R., Tweten, R. K., Ballard, J., Stevens, D. L., Anderson, D. L., Janoff, E. N.: Clinical course of seven survivors of *Clostridium septicum* infection and their immunologic response to alpha toxin. *Clin. Infect. Dis.* 19 (1994) 761–764.
3. Randall, J. M., Hall, K., Coulthard, M. G.: Diffuse pneumocephalus due to *Clostridium* cerebritis in hemolytic uremic syndrome: CT demonstration. *Neuroradiology* 35 (1993) 218–220.
4. Alpern, R. J., Dowell, V. R. Jr.: *Clostridium septicum* infections and malignancy. *JAMA* 209 (1969) 386–388.
5. Kornbluth, A. A., Danzig, J. B., Bernstein, L. H.: *Clostridium septicum* infection and associated malignancy: report of 2 cases and review of the literature. *Medicine* 68 (1989) 30–37.
6. Gorse, G. J., Slater, L. M., Sobol, E., Kim, R. C., Wishnow, R. M., Cesario, T. C.: CNS infection and bacteremia due to *Clostridium septicum*. *Arch. Neurol.* 41 (1984) 882–884.
7. Broughton, R. A., Lee, E. Y.: *Clostridium septicum* sepsis and meningitis as a complication of the hemolytic-uremic syndrome. *Clin. Pediatr.* 32 (1993) 750–752.
8. Kirchner, J. T.: *Clostridium septicum* infection. *Postgrad. Med.* 90 (1991) 157–160.
9. Riccio, J. A., Oberkircher, O. R.: *Clostridium septicum* sepsis and cerebritis: a rare complication of the hemolytic-uremic syndrome. *Pediatr. Infect. Dis. J.* 7 (1988) 342–345.
10. Kolbeinson, M. W., Holder, W. D., Aziz, S.: Recognition, management, and prevention of *Clostridium septicum* abscess in immunosuppressed patients. *Arch. Surg.* 126 (1991) 642–645.
11. Chiang, V., Adelson, P. D., Poussaint, T. Y., Hand, M., Churchwell, K. B.: Brain abscess caused by *Clostridium septicum* as a complication of hemolytic-uremic syndrome. *Pediatr. Infect. Dis. J.* 14 (1995) 72–74.
12. Roeltgen, D., Shugar, G., Towfighi, J.: Cerebritis due to *Clostridium septicum*. *Neurology* 30 (1980) 1314–1316.
13. Ragland, R. L., Knorr, J. R., Lee, G. M., DeGirolami, U., Gelber, N. D.: *Clostridium septicum* meningoencephalitis: an usual presentation of occult rectal carcinoma. *AJNR* 13 (1991) 1487–1488.
14. Marangou, A. G., Joske, R. A., Kaard, A. O., Thomas, W.: Cerebral abscess due to *Clostridium septicum*. *J. R. Soc. Med.* 85 (1992) 641.