

Treatment of adrenoleukodystrophy with bone marrow transplantation

G Malm¹, O Ringdén², M Anvret³, U von Döbeln⁴, L Hagenfeldt⁴, B Isberg⁵, S Knuutila⁶, I Nennesmo⁷, J Winiarski¹ and C Marcus¹

Departments of Paediatrics¹, Clinical Immunology and Transplantation Surgery², Clinical Chemistry⁴, Radiology⁵ and Pathology⁷, Huddinge University Hospital, Huddinge; Departments of Clinical Genetics and Clinical Neuroscience³, Karolinska Hospital, Stockholm, Sweden; and the Department of Medical Genetics⁶, Haartman Institute, Helsinki, Finland

Malm G, Ringdén O, Anvret M, von Döbeln U, Hagenfeldt L, Isberg B, Knuutila S, Nennesmo I, Winiarski J, Marcus C. Treatment of adrenoleukodystrophy with bone marrow transplantation. *Acta Paediatr* 1997; 86: 484–92. Stockholm. ISSN 0803–5253

Three children with adrenoleukodystrophy (ALD) underwent allogeneic bone marrow transplantation (BMT) between 1992 and 1993. The first boy had attention deficits, marked neuropsychological deficits and widespread demyelination in the frontal lobes on MRI before transplantation. Four years later he has mentally deteriorated and the demyelination on MRI has progressed. The second boy had no symptoms but had white matter lesions on MRI when diagnosed. He was regularly followed with MRI and neuropsychological investigations until BMT 18 months later. A progress of the lesions was noted on the initial MRI investigations, and 4 months before BMT a worsening of deficits in attention and kinaesthetic praxis could be observed. He rapidly deteriorated after the transplantation and died 18 months later. Both PCR and *in situ* hybridization confirmed the presence of donor cells in the brain. The third boy had no symptoms but white matter lesions on MRI when diagnosed. The neuropsychological tests remained normal but a slight progress was observed on MRI just before transplantation. This boy is still healthy 3.5 years after BMT. BMT as treatment for ALD has to be considered very early, even in a child without symptoms but signs of demyelination on MRI, if a suitable donor is available. □ *Adrenoleukodystrophy, bone marrow transplantation, CNS*

G Malm, Department of Paediatrics, Huddinge University Hospital, 14186 Huddinge, Sweden

Adrenoleukodystrophy (ALD) is an X-linked, peroxisomal disorder, associated with a deficient degradation and accumulation of very long-chain fatty acids (VLCFA) in body fluids and tissues, primarily the brain and the adrenals, and may lead to progressive neurological symptoms and adrenal hormone insufficiency (1, 2). The brain damage is characterized by an inflammatory demyelination in the white matter (1, 2), possibly involving an immunopathogenic mechanism. A gene responsible for ALD coding for a transport protein in the peroxisomal membrane, has been identified (3). Different phenotypes causing a wide variety of symptoms may occur even within the same family (1–2, 4), and may be due to the influence of an autosomal modifier gene (4, 5). About one-third to half of the males with the ALD genotype (31–57%) develop the rapidly progressive childhood or adolescent cerebral form of ALD (1–2, 4–6). One-quarter or more (25–46%) may develop the form with slowly progressive paraparesis in young men, adrenomyeloneuropathy (AMN) (1–2, 4–6). The adult cerebral forms of ALD (3%), or merely adrenal insufficiency (10%) or asymptomatic forms constitute the rest (1, 2, 6). It is not yet possible to predict the phenotype in a biochemically diagnosed and asymptomatic child without MRI findings, or in a child with abnormal MRI findings but no neuropsychological or neurological deficits (1, 2, 5). Various therapeutic approaches to prevent the

occurrence of the most severe childhood cerebral form of ALD have been tried, but hitherto trials with diet, glycerol trioleate and trierucate oils (GTO and GTE oils), anti-inflammatory therapy and γ -globulin have had no definite effect on clinical symptoms (7–11). During the last decade, BMT has been used to treat various genetic metabolic, mostly lysosomal disorders. The production of the deficient enzyme by healthy haematopoietic cells from the donor has been demonstrated in animal experiments (12) as well as in human lysosomal disorders, such as Gaucher's disease (13). The hypothesis indicating that BMT may be beneficial is based on the observation that microglial cells in the brain, derived from the haematopoietic cells of the donor, may provide sufficient enzyme to the neighbouring cells to arrest the demyelination process (5). The finding of microglial cells from the donor, demonstrated in the brain of patients in other diseases six months after transplantation (14), support this hypothesis.

Nevertheless, the underlying mechanisms are not yet fully understood in the lysosomal disorders and even less in the peroxisomal disorder ALD (15). Yet in recent years, successful BMT treatment of the childhood cerebral form of ALD, based on clinical data, has been reported (16–21), and stabilization or improvement of MRI findings (20) and even normalization (16) are described in clinically recovered children. However, it is still not known at what stage it

is too late to arrest the disease. If the demyelination process has advanced too far, the BMT seems to accelerate the demyelination process (4). Thus, BMT must be performed very early when the symptoms of ALD are mild (2, 5, 19, 21), however, what is a mild brain involvement is difficult to define. On the other hand, the ethical justification for transplanting a child with MRI lesions but no clinical involvement, and who may not develop the childhood cerebral form, must also be considered. In this report we describe our experience of three boys who received bone marrow transplants during 1992–93 at Huddinge University Hospital, and of another boy given diet and oils at an early age.

Material and Methods

Patients

Four boys, three of them brothers, were diagnosed with ALD aged between 2.5 and 10 years. The diagnosis was confirmed by a marked elevation of VLCFA in serum (C25:0 > 2.1 $\mu\text{mol/l}$; C26:0 > 1.9 $\mu\text{mol/l}$). Both mothers were carriers of ALD, based on elevated levels of VLCFA.

After diagnosis, the boys followed a diet providing 30% of the calories as fat; 10% being low in VLCFA and 20% as GTO/GTE oils (2–3 ml/kg body weight of a 4:1 mixture of GTO and GTE oils). The diet was supplemented with safflower oil.

Clinical, laboratory and neuroradiological investigations

Before and after transplantation, the boys had follow-ups involving neurological assessments, including fine and gross motor function, videotaping, standardized neuropsychological assessments, electroencephalography (EEG), visual-evoked potentials (VEP), brain stem auditory-evoked potentials (BAEP), electromyography (EMG), nerve velocity rates (NVR) and neuroradiological investigations (MRI). The lesions found on MRI were scored using a scoring method defined by Loes et al. (22). VLCFAs were regularly followed before and after BMT.

Sections from the brain, bone marrow, heart, liver and lymph nodes, were analysed by PCR-amplification of a CA repeat in *DP 1* gene, locus *D5S 346*, to identify donor cells. *In situ* hybridizing was performed on 5 μm paraffin-embedded brain tissue sections, according to the procedure described in detail elsewhere (23). The donor or recipient origin of the cells was determined using an X-cosmid Y-repeat probe cocktail (Integrated Genetics, Framingham, MA, USA), which allows simultaneous identification in both the X and the Y chromosomes (24).

Biochemical assays

Plasma VLCFAs were measured by capillary gas chromatography and selected ion monitoring mass spectrometry. The fatty acids were extracted and hydrolysed as described by Aubourg et al. (25) and converted to methyl esters.

C19:0 and C27:0 were used as internal standards. The molecular ions of the methyl esters were monitored for quantitation.

Neuropsychological investigation

Standardized IQ and neuropsychological tests appropriate for age, were used before and after BMT to evaluate cognitive ability, language, auditory and spatial processing, memory and attention (Table 1). The results of IQ-tests (WISC) are given as stanine-scores, in which the mean is 5 and standard deviation 2. The neuropsychological tests are given as Z-scores, in which the mean is 0 and standard deviation 1.

Transplantation procedure

All donors were HLA, -A -B and -DR identical unrelated donors. Genomical HLA class II typing was used. The children were prepared with busulfan, 80 mg/m² (16–20 mg/kg) divided into four daily doses, for 4 days, followed by cyclophosphamide, 2 g/m² (240–300 mg/kg), given over 4 days. In addition, anti-thymocyte globulin, 2–5 mg/kg/day, was given for 5 days prior to BMT. Bone marrows were not T-cell-depleted. As prophylaxis against GVHD, cyclosporin A was combined with a short course of i.v. methotrexate. The children were kept in reverse isolation during the pancytopenic phase. Details regarding supportive care have been published elsewhere (26).

No signs of mixed chimerism were seen in any of the patients by blood group serology and sex chromosome analysis.

Results

Patient characteristics

Patient 1. Pre-transplantation course. Patient 1 is the youngest of three brothers of non-consanguineous parents. The eldest brother had a very mild spastic paraparesis, diagnosed as adrenomyeloneuropathy (AMN) after Patient 1 had been diagnosed. When Patient 1 was 9.5 years old a personality change seemed to occur. An attention deficit and learning disability was observed at school (Table 2), and on CT scan large, symmetric low-density frontal lesions were seen. The diagnosis of ALD was confirmed by elevated levels of VLCFA (C25:0 6.0 $\mu\text{mol/l}$; C 26:0 4.4 $\mu\text{mol/l}$) when he was 10 years old. The ACTH stimulation test gave a normal cortisol response. The EEG showed a diffuse abnormality. The VEP, BAEP and the NVRs were all within normal limits.

In the neuropsychological evaluation he showed deficits in attention, planning and strategy. The search for a donor started immediately when the diagnosis was confirmed. The neurological examination just before BMT revealed no paresis, but some clumsiness. His tonus, deep tendon reflexes and cranial nerve functions were all normal. The

Table 1. Neuropsychological tests used at examination.

1	General developmental level Wechsler Intelligence Scale for Children (28)
2	General developmental level Griffith mental developmental scale II (29)
3	NEPSY (first published in 1990, used from 1991) (30) Orientation, attention, strategy Language tests —Comprehension of instructions —The Token test Motor and sensory tests —Kinesthetic praxis-imitation of complex finger positions —Dynamic praxis-imitation of sequencing of hand movements —Kinesthetic feedback-proprioception —Tactile perception of forms —Manual speed Visuo-spatial tests —MVPT motor-free-visual-perception test —VMI visuo-motor-integration test —VGA visual gestalt ability Memory tests —Digit span —Word span —Memory of story —Visual memory
4	Trail-making test (Kiddie version) Visuo-motor speed and cognitive flexibility
5	Spiq (Understanding of words)

attention deficits and lack of initiative were marked. He was grafted 5 months after the diagnosis in December 1992, when he was 10.5 years old.

Post-transplantation course. In the post-transplant period, this patient developed a grade I GVHD of the skin and a limited haemorrhagic cystitis. One year later, he developed haemolytic anaemia, erythroblastopenia and thrombocytopenia. He required red cell and platelet transfusions, intravenous γ -globulin and steroid treatment. All treatment was tapered without recurrence of the cytopenias. His mental abilities have slowly deteriorated since the transplantation (Table 2). He has also developed feeding difficulties and is fed via a gastrostomy. Four years after BMT dementia is obvious; he understands only simple sentences and words and has marked difficulty in following instructions, and the personality change related to the frontal lobe lesions are obvious. He has no paresis but clumsiness and difficulties in coordination. He can only walk a few steps without support and needs help with all daily activities. The white matter lesions have become extensive on MRI 3 years after BMT.

Patient 2. Pre-transplantation course. Patient 2 was the eldest of three brothers (Patients 3 and 4) of non-consanguineous parents. When he was 6 years old, Addison's disease was diagnosed. Six months later, ALD was confirmed biochemically (C25:0 6.0 $\mu\text{mol/l}$ and C26:0 6.7 $\mu\text{mol/l}$). At this time, white matter lesions were

visualized in the parieto-occipital region on MRI. The EEG was slightly abnormal and the VEP, BAEP and NVRs were all normal. The neurological examination was normal. In mental assessments, he performed within normal limits. The search for a donor started immediately after diagnosis when he was 6.5 years old, and 6 months later, a suitable donor was found. However, the BMT was initially postponed, since his clinical condition was stable. He was followed every third month with an EEG, VEP and BAEP and every sixth month with MRI and neuropsychological tests. A progress of the lesions in the white matter could be seen on the first two following MRI (Figure 1). Four months before BMT the VEP became abnormal. At the same time he declined in his school performances, and in the neuropsychological tests deficits in attention and kinaesthetic dyspraxia had worsened. According to previous recommendations (4) a decision for BMT was not taken until some clinical or neuropsychological symptoms had developed (2, 19, 21). In the neurological examination just before BMT, he showed a slight coordination deficit, mild clumsiness and dyspraxia and had some difficulty in understanding verbal instructions. The muscular tonus was normal, but the patellar and Achilles tendon reflexes were depressed. He was grafted when he was 8 years old, in October 1992.

Post-transplantation course. The patient's transplantation course passed without any major complications. His neurological symptoms worsened in conjunction with BMT and in the post-transplant period he had obvious difficulty in perceiving and understanding spoken words and in interpreting visual stimuli. Within 1 year after BMT, a rapid progress of the disease occurred. The development of dementia was obvious and his motor ability declined. He died 18 months after BMT (Table 2). No benefit of BMT had been seen.

Patient 3. Pre-transplantation course. Patient 3 is one of the two younger brothers of Patient 2 and was diagnosed as ALD at the same time as his brothers, when he was 4 years and 10 months old (C25:0 4.7 $\mu\text{mol/l}$ and C26:0 5.5 $\mu\text{mol/l}$). Addison's disease was confirmed at the same time. A diet low in VLCFA supplemented with GTO/GTE oils was initiated soon after diagnosis. The neurological examination was normal, apart from a depression of the deep tendon reflexes, and he performed quite normally in neuropsychological tests (Table 2). EEG, VEP, BAEP and the NVRs were all within normal limits; however, bilateral lesions in the white matter of the occipital lobes and corpus callosum were visualized on MRI. He was followed every third month with neurophysiological investigations and every sixth month with neuropsychological tests. These were all within normal limits. MRI was also performed approximately every 6 months. Progress of the white matter lesions was observed immediately before transplantation in April 1993, 22 months after diagnosis (Fig. 1). He was grafted when he was 6 years and 8 months old, although

Table 2. Summary of some clinical, neurological and psychometric data in three children with ALD, before and after bone marrow transplantation. The results in Wechsler Intelligence Scale (WISC) are given as stanine in a scale from 0 to 9 (average = 5, SD = 2) and IQ in brackets. The results of neuropsychological investigations are given as Z-score in which the mean is 0 and standard deviation is 1.

Patient no.	1	2	3
First symptoms	attention deficits	adrenal insufficiency	adrenal insufficiency
Age	9.5 years	6 years	4.5 years
ALD diagnosis age	10 years	6.5 years	4.5 years
BMT age	10.5 years	8 years	6.5 years
Pre-transplant investigations			
Neurologically	clumsiness	dyspraxia, clumsiness, depressed reflexes	depressed reflexes
Intellectual assessment	4 months before BMT ^a	4 months before BMT ^a	4 months before BMT ^a
Verbal IQ	4 (89-96)	6 (104-111)	9 (> 127)
Performance IQ	3 (82-88)	2 (74-81)	8 (119-126)
Combined	3 (82-88)	4 (89-96)	8 (119-126)
Neuropsychological	4 months before BMT	2 months before BMT ^d	4 months before BMT
Attention	-1 Z-score ^b	-3 Z-score	normal
Language	-1 Z-score ^c	normal	normal
Sensory-motor	not performed	-3 Z-score	normal
Visuo-spatial	not performed	-2 Z-score	normal
Memory	not performed	normal	normal
BMT			
Follow-up after BMT	3.5 years	1.5 years	3.5 years
Neurological symptoms	progression	progression	healthy
At follow-up	dementia	died	tendon reflexes
Intellectual assessment	9 months after BMT ^a	not performed	3.5 years after BMT ^a
Verbal IQ	not completed		8 (119-126)
Performance IQ	not completed		7 (112-118)
Combined	-		8 (119-126)

Intellectual assessment: ^a Wechsler Intelligence Scale for Children; Neuropsychological tests: ^b Trail-making test, Kiddie version: visuo-motor speed and cognitive flexibility; ^c Spiq (understanding of words); ^d NEPSY.

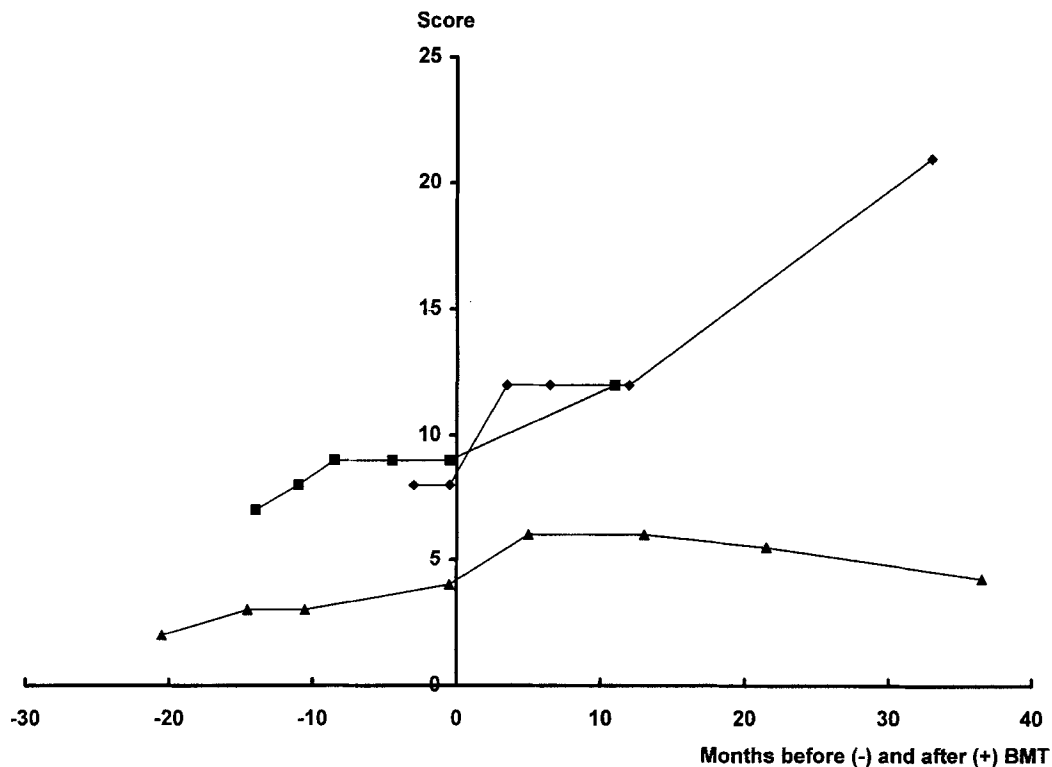


Fig. 1. MR severity score over time in Patients 1-3. Negative values represent number of months before, and positive values number of months after bone marrow transplantation (♦ = Patient 1; ■ = Patient 2; ▲ = Patient 3).

clinically still healthy, as soon as an HLA-identical unrelated donor was found.

Post-transplantation period. The post-transplantation period passed without major complications. The patient had a GVHD grade 1 of the skin and has developed an IGG 2 subclass deficiency. Three and a half years after BMT he is still healthy (Table 2). He attends an ordinary school and shows no deterioration in the neuropsychological tests.

Patient 4. Patient 4, the youngest brother of Patient 2 and 3, was biochemically diagnosed as ALD when he was 3 years old (C25:0 2.1 $\mu\text{mol/l}$ and C26:0 2.4 $\mu\text{mol/l}$). He has been on a diet and GTO/GTE oils since then. He has been followed with VEP, BAEP, EEG, MRI and neuropsychological tests. The VEP and BAEP have been normal, the EEG slightly abnormal and the NVRs at 3 and 6 years of age were also normal. At 6 years of age he is still healthy and has not yet developed any white matter lesions on the MRI. He has performed normally in Griffith's Developmental Scale. In neuropsychological tests he has shown deficits in attention and sensomotor functions. A search for an HLA-identical donor for future BMT if necessary, has been done, but not yet found.

Biochemical findings

All four boys were treated with a diet and GTO/GTE oils as soon as the diagnosis was confirmed: Patient 1 for 5 months, Patient 2 for 11 and Patient 3 for 17 months before BMT. The levels of VLCFAs in plasma normalized within 10 weeks in all boys and they were within normal limits before BMT (C25:0 < 2.1 $\mu\text{mol/l}$ and C26:0 < 1.9 $\mu\text{mol/l}$).

In Patient 1, in whom the diet and oils were discontinued directly after BMT, the levels of the VLCFAs rose slightly above normal in occasional blood samples (max. level C26:0 3.9 $\mu\text{mol/l}$). In Patient 2, who continued the diet and oils after BMT until he died, the concentrations of VLCFAs remained normal. Patient 3 continued the diet and oils until 2 years after BMT. As the levels of VLCFAs rose above normal after discontinuation (C26:0 max. level 3.4 $\mu\text{mol/l}$), the oils were reintroduced. The VLCFAs then normalized again.

Neuroradiological findings

Patient 1 showed widespread symmetrical demyelination in the frontal lobes including the genu of the corpus callosum, and via the internal capsulae the anterior brain stem was involved. Subcortical fibres in the frontal lobes were spared (Fig. 2a). The MRI score was 8 (Fig. 1). Follow-up examinations between 1 and 3 years after BMT demonstrated outward and posterior progression with the development of advanced cortical and white matter atrophy, and a symmetrical demyelination appeared in the occipital lobes separate from the frontal lesions (Fig. 2b). The

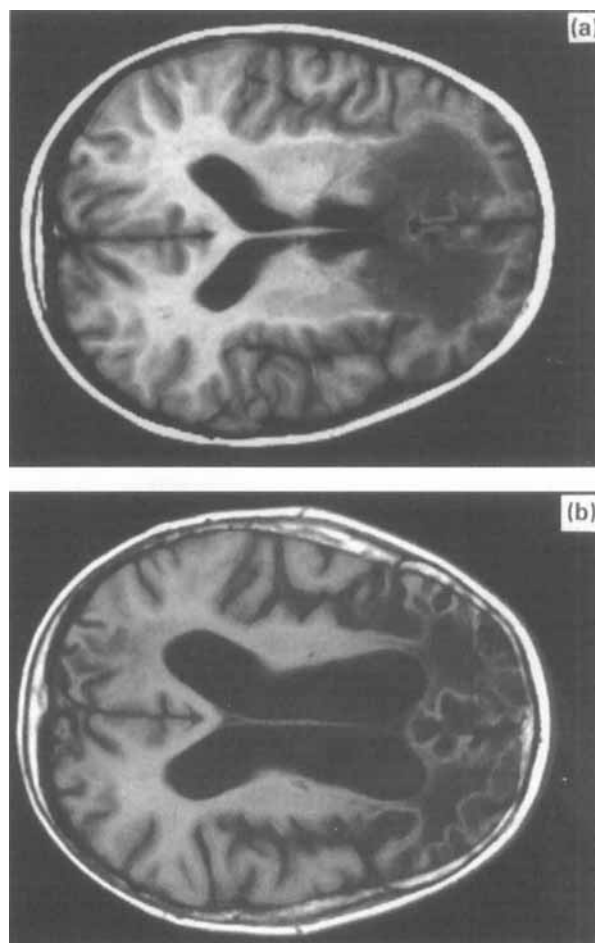


Fig. 2. T1-weighted brain MR images demonstrate symmetrical demyelination in both frontal lobes 2 weeks before BMT in Patient 1 (a). Thirty-three months after BMT there has been a progression outwards and a marked atrophy (b).

MRI-score increased considerably (Fig. 1). Contrast enhancement was never seen, however, performed only after transplantation.

In Patient 2, symmetrical hyperintensities as signs of demyelination were seen in the parieto-occipital region and in the splenium corporis callosi on the first MRI investigation, 3 months after the diagnosis was confirmed (Fig. 3a). The MRI-score was 7. A progress of the lesions with increased score was noted in the following MRI investigations (Fig. 1). On the MRI performed 11 months after BMT the demyelination of the white matter had increased further (Fig. 3b).

In Patient 3 a symmetrical hyperintensity band through the splenium of the corpus callosum was demonstrated on the first MRI, 3 months after the diagnosis was made. The MRI-score was 2. On the fourth MRI examination, a progress of the demyelination and an increase of MRI-score to 4 was seen 2 weeks before BMT (Fig. 4a). After an initial progression during the first year after transplantation to score 6 a slight improvement occurred during the second, and after 3 years the score was 4 (Figs 1 and 4b).

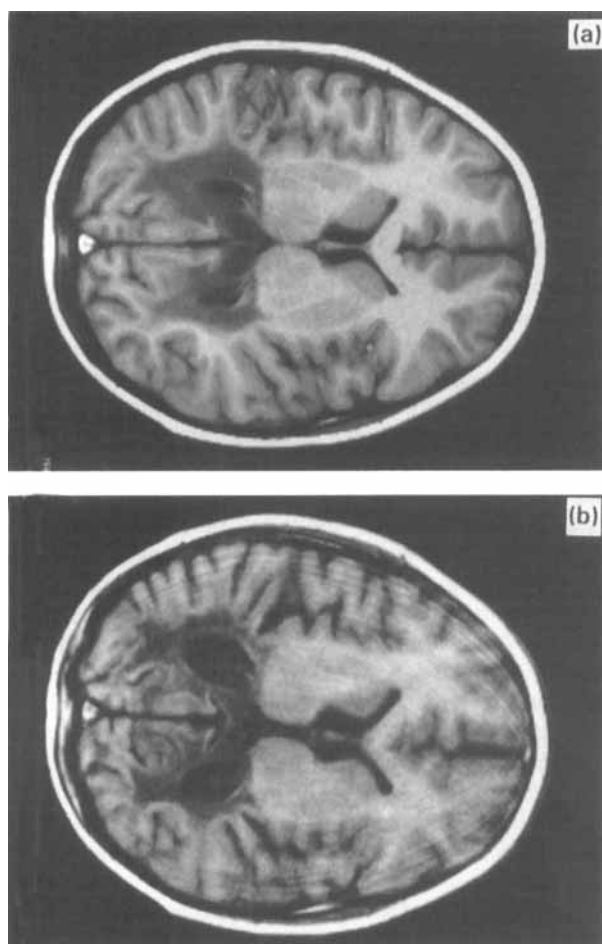


Fig. 3. T1-weighted brain MR images demonstrate symmetrical demyelination in the parieto-occipital lobes and in splenium of the corpus callosum 2 weeks before BMT in Patient 2 (a). Eleven months later there is a progression of the demyelination as well as local atrophy (b).

In Patient 4, no signs of demyelination of the white matter have yet been seen, almost 5 years after the diagnosis was made.

Neuropsychological findings

Patient 1 was investigated 4 months before BMT. He needed continually support to be able to sustain attention. He performed within the normal range in the WISC test (Table 2). The test profile was very uneven. Sub-tests measuring arithmetic, stanine 1, attention (coding), stanine 1, planning and strategy (mazes), stanine 2 were clearly below normal. In the neuropsychological tests employed verbal fluency was below normal. The trail-making test could not be performed without much support. Nine months after BMT only four of the WISC sub-tests were administered. He had no spontaneous speech and must get started to be able to answer questions. In three of the WISC sub-tests he performed within normal limits but on a lower level than before (verbal scale). In the neuropsychological

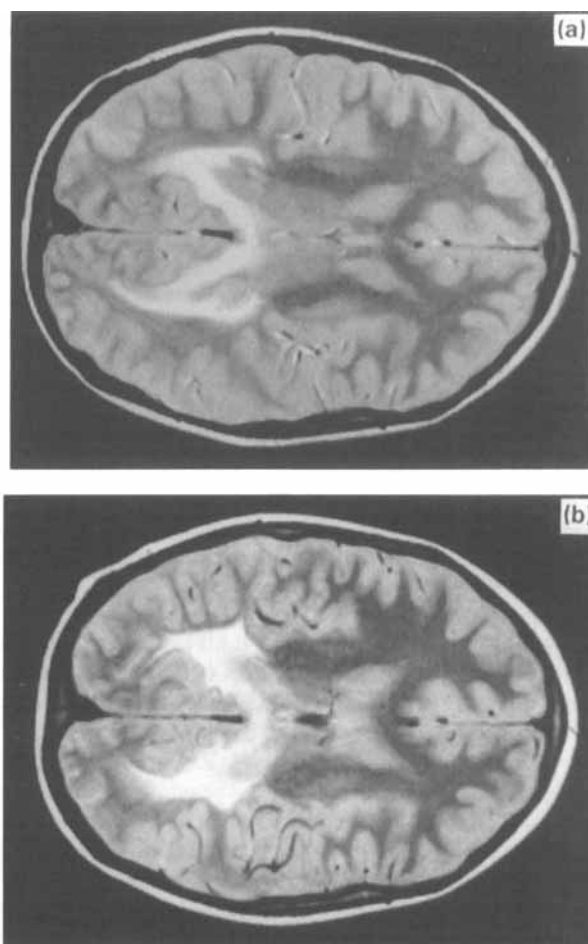


Fig. 4. Proton density brain MR images demonstrate symmetrical periventricular lesions in the parieto-occipital regions as well as in splenium of corpus callosum 2 weeks before BMT in patient 3 (a). Thirty-six months after BMT there is a slight outward progression of demyelination but no atrophy (b). The outward progression was seen already at 5 and 13 months after BMT, but an improvement occurred explaining the fall in Loes score.

tests no deficits in visual perception nor in visual memory could be found. Auditory memory as measured in memory of story was also within normal limits. Digit span and word span could not be performed. The Visual motor integration test was difficult to carry out. The patient could no longer write his name. Deficits in attention, ability to organize and process information had increased. The clinical impression of dementia was definitive.

Patient 2 underwent IQ and neuropsychological tests on five occasions: 13, 8, 4, 2 months and 4 weeks before BMT. Only on the first two occasions were full-scale WISC and complete neuropsychological tests given. Intellectual basic capacity 13 months before BMT were judged to give the same results as 4 months before (Table 2); however, on both occasions the results were lower than 8 months before BMT. There was a large difference between the results in the verbal scale compared to the performance scale. In the verbal scale the results were within normal in the different sub-tests, while in the performance scale object assembly

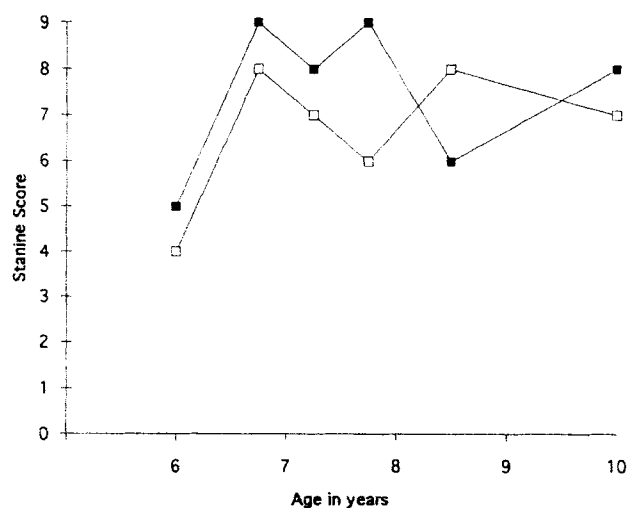


Fig. 5. IQ test (WISC verbal and WISC performance) in Patient 3 before and after BMT. The results are given as stanine, in which the mean is 5 and standard deviation 2.

was far below normal (stanine 1) at all test occasions. The neuropsychological tests 13 months before BMT showed mainly deficits in attention and kinaesthetic dyspraxia (distractability -2 Z-scores, kinesthetic praxis -2 Z-scores, kinaesthetic perception -3 Z-scores). The difficulties regarding kinaesthetic dyspraxia persisted and worsened 2 months before BMT, when he used compensatory procedures to solve some of the tasks. After BMT it was not possible to perform more than one assessment, and 1.5 months after BMT there was a further decline in neuropsychological abilities, mainly in visual and auditory perception and in memory tests. These functions rapidly deteriorated before he died.

Patient 3 was investigated twice, 7 and 4 months before BMT. On the first occasion he performed normally in the IQ-test (Table 2, Fig. 5) including all sub-tests. On the second investigation the results were far above normal (WISC verbal stanine 9, WISC performance stanine 8, WISC combined stanine 8). This could partly be due to the practice effect and the fact that the boy had just started school or the lower result on the first occasion may have been for psychosocial reasons (mother's death). In the neuropsychological tests (NEPSY), attention, language, sensorimotor and visuo-spatial functions and memory were all within normal limits. 6, 14, 22 and 40 months after BMT he has been re-tested. The result of his IQ and neuropsychological tests remains basically normal. Fourteen months after BMT (7:9) there was a discrepancy between the results on WISC verbal scale as compared to the performance scale. The patient worked in a very slow speed and the results of the sub-test coding was below normal (stanine 2). On the two following WISC the results on the different sub-tests in the performance scale continued to vary, and picture arrangement and symbol search was the most difficult (stanine 3). On the last test no negative deviations could be noted.

Patient 4, who was diagnosed when he was 3 years old,

was tested when he was 5 years and 3 months old. He performed normally on the Griffiths' Developmental Scale II in the different scales. In the neuropsychological tests, he showed deficits in attention and sensorimotor functions (tactile perception). However, he was very stressed when tested.

Neuropathological findings

At autopsy in Patient 2, bilateral severe changes in the white matter were present, especially involving the parieto-occipital lobes and to a lesser degree the temporal and posterior frontal lobes. The tissue was softened and weakly yellow-brown in colour. Microscopy revealed advanced myelin damage in those areas, although the sub-cortical U-fibres usually were spared. Macrophages and numerous reactive astrocytes could be detected in the tissue and perivascular infiltrates of macrophages and lymphocytes was also found. Cortical regions appeared normal but loss of neurons was seen in the hippocampus, most prominent in Sommer's sector. The adrenals were atrophic. Analysis of sections from the brain, bone marrow, heart, liver and lymph nodes by PCR showed that the bone marrow and lymph-node was homozygous for allele 2. Biopsies from the liver and heart show an allele pattern corresponding to three different alleles 1, 2, 3. In addition, material from three different brain regions was analysed which showed the same pattern. This indicates that the donor cells could be detected in the tissues showing three alleles, however, whether the donor cells were located in the lumen of the vessels or in the tissue was not possible to discern. Using *in situ* hybridization technique, only some 5% of all cells showed hybridization signals. A great proportion of the cells exhibiting signals contained both X and Y chromosomes, originating from the host. However, we were able to find eight cells with two X signals but no Y signals. These XX-bearing cells were in the area of perivascular infiltrates and they resembled lymphocytes. Still, because the morphology of a single cell is poorly preserved under *in situ* hybridization, it should be noted that it was not possible to classify these XX-bearing cells reliably.

Discussion

During the last decade BMT as a treatment modality has reportedly prevented the progress of ALD in selected cases (16–21). In a recent study (20) in which the lesions on MRI were quantitated, the prevention of progress of the white matter lesions and improvement was described on MRI in children with a clinical arrest of the disease after BMT, and previously even re-myelination has been described (16). However, despite promising results, one must note, that the number of transplanted children is yet too small and the follow-up periods are too short to allow any definite conclusions (19). Since the phenotypes in ALD show such great variability, experience from a large number of

patients is required to prove the benefit of BMT. The neurological outcome of the BMT may also be influenced by complications from the transplantation (19–21), and new recommendations of pre-transplant conditioning has been worked out (COGENT, Keystone meeting, January 1996).

The levels of VLCFAs in the patients in our study was normalized when BMT was performed, a fact previously suggested to be of significance in minimizing complications during the transplantation period (19, 21). None of our patients had major transplant-related complications. A slight rise in the levels of plasma VLCFAs in Patients 1 and 3 was seen when the diet and oils were excluded after BMT. However, it is not known if there is any correlation between the effect of BMT and the level of plasma VLCFA, and raised levels of plasma VLCFA have previously been described in patients after BMT was reported as successful (16–21).

In Patient 1, who presented neuropsychological symptoms and widespread frontal white matter lesions on the MRI before transplantation, the clinical symptoms have continued to increase slowly and a progression of the demyelination was seen on the MRI 3 years after BMT. One cannot decide whether the course of the disease may have been somewhat delayed by BMT, whether this is the natural course of a frontal, more slowly progressive form of the childhood cerebral ALD, or whether a progress of the disease could have been caused by the transplant complications. The present, persistent sequelae are serious, and it is still difficult to predict the degree of final disability when the patient becomes older. Furthermore, the disease progressed during the 5 months' search for a donor. This emphasizes the need for a rapid diagnosis and search for a donor, but also the need of a re-evaluation of the progress of the disease just before BMT. However, retrospectively, and in the light of our present knowledge (17–21), Patient 1 would not have been subjected to a BMT today.

In Patient 2, who had signs of demyelination on MRI but no clinical, neuropsychological or neurophysiological signs of disease when diagnosed, the deliberate wait for the occurrence of some clinical symptoms before a decision for transplantation was made (4), had devastating effects. BMT did not arrest the disease. Indeed, an acceleration seemed to occur, as previously reported (4). The findings of donor-derived DNA in the brain supports the desired technical success of the transplantation. This is additionally strengthened by the *in situ* hybridization showing donor cells, most likely lymphocytes, in the area of perivascular infiltrates in the brain. The younger brother, Patient 3, who also had signs of demyelination on MRI but no clinical, neuropsychological or neurophysiological signs of disease when diagnosed, except a slight progression of the lesions on the MRI before BMT, was engrafted as soon as a suitable donor was found. He is still healthy 3 years and 6 months after BMT with an arrest and even decrease of the white matter lesions seen on MRI, measured by Loes score. It cannot be excluded that he might have developed a late onset (adolescent or adult)

instead of a childhood cerebral form of ALD in the future, or even developed an AMN, although the localization of the white matter demyelination makes this less likely (1, 2).

Hitherto it has not been possible, with diet, GTO/GTE oils or pharmacotherapy, to prevent the development of the childhood cerebral form of ALD (7–11), however, it cannot be ruled out that very early initiation of diet and oil therapy may delay the onset (5). This may be true of Patient 4, who was started on diet and oils at 3 years of age with normalization of VLCFAs since then. Now, having been on his diet and oils for 5 years, he remains healthy and has no signs of demyelination on MRI. However, more than half of the boys with biochemically diagnosed ALD never develop this form of ALD (1).

BMT is not a proven cure of childhood cerebral form of ALD, but it is by far the most promising treatment at the moment. Therefore BMT has to be considered, when a child has got the biochemical diagnosis of ALD and signs of demyelination can be demonstrated on MRI (19–21), if a suitable donor is available. BMT is an expensive and stressful treatment and although the survival rates keep improving and the availability of donors steadily increases (26), BMT is associated with a significant mortality and should not be performed unnecessarily. However, our Patient 2 indicates that despite a careful control of the patient, the wait for clinical symptoms may be devastating. Even if our experience is restricted to only three cases, we claim that BMT has to be considered before the onset of clinical or neuropsychological symptoms in a child with demonstrable lesions on MRI.

A decision to perform a BMT under such conditions will presumably result in BMT of patients who never would have developed the severe form of ALD. This situation is analogous with the situation for high risk patients with leukaemia in remission (27). The problem of selecting patients who might benefit from BMT emphasizes further improved genetic, neuropsychological, neuroradiological and clinical diagnostic tools to select suitable candidates for BMT, and a need of prospective international studies to evaluate this rare disorder in a quantitative and qualitative manner.

Acknowledgments. — We thank Lisa Stolpe at the Departments of Clinical Genetics and Clinical Neuroscience, Karolinska Hospital, Christina Lindquist and Ingegerd Lindquist at the Department of Pathology at Huddinge University Hospital for excellent laboratory assistance. We also thank Drs Wa'el El-Rifai and Tarja Huhta at the Department of Medical Genetics, Haartman Institute, Helsinki, Finland, for performing *in situ* hybridization. We thank the nursing staff in the Department of Transplantation Surgery and Paediatrics at Huddinge Hospital for excellent patient care. The study was supported by grants from the National Board of Society, the Swedish Cancer Foundation, the Children's Cancer Foundation, the Swedish Medical Research Foundation and Belvén Foundation.

References

1. Moser HW, Smith KD, Moser AB. X-linked adrenoleukodystrophy. In: Schriver CS, Beaudet AL, Sly WS, Valle D, editors. The metabolic and molecular basis of inherited disease. New York: McGraw-Hill. 1995: 2325–49

2. Moser HW, Powers JM, Smith KD. Adrenoleukodystrophy: molecular genetics, pathology and Lorenzo's oil. *Brain Pathol* 1995; 5: 259–66
3. Mosser J, Douar A-M, Sarde C-O, Kioschis P, Feil R, Moser HW, et al. Putative X-linked adrenoleukodystrophy gene shares unexpected homology with ABC-transporters. *Nature* 1993; 361: 726–30
4. Moser HW, Moser AB, Smith KD, Bergin A, Borel J, Schankroff J, et al. Adrenoleukodystrophy: phenotypic variability and implication for therapy. *J Inher Metab Dis* 1992; 15: 645–65
5. Moser HW. Clinical and therapeutic aspects of adrenoleukodystrophy and adrenomyeloneuropathy. *J Neuropathol and Exp Neurol* 1995; 54: 740–5
6. Van Geel BM, Assies J, Weverling GJ, Barth PG. Predominance of the adrenomyeloneuropathy phenotype of X-linked adrenoleukodystrophy in the Netherlands: A survey of 30 kindreds. *Neurology* 1994; 44: 2343–6
7. Brown FR, Van Duyn MA, Moser AB. Adrenoleukodystrophy: effects of dietary restriction of very long-chain fatty acids and administration of carnitine and clofibrate on clinical status and plasma. *Johns Hopkins Med J* 1982; 151: 164–72
8. Watkins PA, Naidu S, Moser HW, Adamoleu S. Biochemical procedures in diagnosis, prevention and treatment in adrenoleukodystrophy. *J Inher Metab Dis* 1987; 10 Suppl: 146–53
9. Rizzo WB, Leshner RT, Odone A, Dammann AL, Craft DA, Jensen ME, et al. Dietary erucic acid therapy for X-linked adrenoleukodystrophy. *Neurology* 1989; 39: 1415–22
10. Moser HW, Aubourg P, Comblath D, Borel J, Wu Y-W, Bergin A, et al. Therapy for X-linked adrenoleukodystrophy. In: *Treatment of genetic disease*. Desnick RJ, editor. New York: Churchill Livingstone 1991; 111–29
11. Cappa M, Bertini E, del Balzo P, Cambiaso P, Biase AD, Salvati S. High dose of immunoglobulin iv treatment in adrenoleukodystrophy. *J Neurol Neurosurg Psychiatr* 1994; 57 Suppl: 69–70
12. Walkley SU, Thrall MA, Dobrenis K, Huang M, March PA, Siegel, et al. Bone marrow transplantation corrects the enzyme defect in neurons of the central nervous system. *Proc Natl Acad Sci* 1994; 91: 2970–4
13. Ringdén O, Groth CG, Erikson A, Granqvist S, Månsson J-E, Sparrelid E. Ten years' experience of bone marrow transplantation for Gaucher disease. *Transplant* 1995; 59: 864–70
14. Unger ER, Sung JH, Manivel JC, Chenggis ML, Blazar BR, Krivit W. Male donor-derived cells in the brains of female sex-mismatched bone marrow transplant recipients: a Y-chromosome specific in-situ hybridization study. *J Neuropathol Exp Neurol* 1993; 52: 460–70
15. Walkley SU, Dobrenski K. Bone marrow transplantation for lysosomal diseases. *Lancet* 1995; 345: 1382–3
16. Aubourg P, Blanche S, Jambaque I, Rocchiccioli F, Kalifa G, Naud-Sandreau C, et al. Reversal of early neurologic and neuroradiologic manifestations of X-linked adrenoleukodystrophy by bone marrow transplantation. *N Engl J Med* 1990; 322: 1860–6
17. Shapiro EG, Lockman LA, Balthazor M, Krivit W. Neuropsychological outcomes of several storage diseases with or without bone marrow transplantation. *J Inher Metab Dis* 1995; 18: 413–29
18. Hoogerbrugge PM, Brouwer OF, Bordigoni P, Ringdén O, Kapaun P, Ortega JJ, et al. Allogeneic bone marrow transplantation for lysosomal storage diseases. *Lancet* 1995; 345: 1398–402
19. Krivit W, Lockman LA, Watkins PA, Hirsch J, Shapiro EG. The future for treatment by bone marrow transplantation for adrenoleukodystrophy, metachromatic leukodystrophy, globoid cell leukodystrophy and Hurler syndrome. *J Inher Metab Dis* 1995; 398–412
20. Loes DJ, Stillman AE, Hite S, Shapiro E, Lockman L, Latchaw RE, et al. Childhood cerebral form of adrenoleukodystrophy: short-term effect of bone marrow transplantation on brain MR observations. *Am J Neuroradiol* 1994; 15: 1767–71
21. Krivit W, Lockman L A, Shapiro EG. Childhood onset of cerebral adrenoleukodystrophy: Effective treatment by bone marrow transplantation. In: Steward CG, Hobbs JR, editors. *Correction of genetic diseases by transplantation*, III. London: COGENT, 1995: 48–56
22. Loes DJ, Hite S, Moser H, Stillman A, Shapiro E, Lockman L, et al. Adrenoleukodystrophy: A scoring method for brain observations. *Am J Neuroradiol* 1994; 1761–6
23. Knuutila S: Morphology antibody chromosome technique for determining phenotype and genotype of the same cell. In: Boyle AL, editor. *Current protocols in human genetics*. Madison CT: John Wiley & Sons, Inc., Unit 4: 7
24. Slunga-Tallberg A, El-Rifai W, Keinönen M, Ylinen K, Kurki T, Klinger K, et al. Maternal origin of nucleated erythrocytes in peripheral venous blood from pregnant women. *Hum Genet* 1995; 96: 53–7
25. Aubourg P, Bourgères PF, Rocchiccioli F. Capillary gas-liquid chromatographic-mass spectrometric measurement of very long chain (C₂₂ to C₂₆) fatty acids in microliter samples of plasma. *J Lipid Res* 1985; 26: 263–7
26. Ringdén O, Bolme P, Lönnqvist B, Tollemar J, Dahllöf G, Garthon G, et al. Bone marrow transplantation in children. *Clin Transplant* 1989; 3: 12–8
27. Saarinen U, Mellander L, Nysom K, Ringdén O, Schröder H, Glomstein A, et al. Allogeneic bone marrow transplantation in first remission for children with very high risk acute lymphoblastic leukemia: A retrospective case-control study in the Nordic Countries. *Bone Marrow Transplant* 17: 357–63, 1996
28. Wechsler intelligence scale for children. Stockholm: Skandinaviska Testförlaget AB, 1970
29. Ahlin-Åkerman B, Nordberg I. Griffiths' utvecklingsskalor I och II. Manual. Stockholm: Psykologiförlaget, 1980
30. Korkman M. NEPSY. A proposed neuropsychological test battery for young developmentally disabled children. Theory and evaluation (dissertation). Helsinki, 1988

Received May 24, 1996. Accepted in revised form Dec. 11, 1996