

Teaching Point

(Section Editor: K. Kühn)

Vomiting, headache and seizures in a child with idiopathic nephrotic syndrome

F. Pillekamp, B. Hoppe, B. Roth and U. Querfeld

Klinik und Poliklinik für Kinderheilkunde der Universität zu Köln, Germany

Case report

A 5-year-old patient with idiopathic nephrotic syndrome had been successfully treated with a course of steroids. Four months later the patient had a first relapse of the nephrotic syndrome, which was also steroid responsive. Three weeks after the second course of steroid treatment, while still receiving 40 mg/m²/day prednisone, the child was admitted because of frequent vomiting and headache. Physical examination of the child was normal except for peripheral oedema. Neurological investigation was unremarkable. Blood pressure was 125/80 mmHg. Laboratory results included the following: leukocytes 30 200/μl, haemoglobin 14.4 g/dl, haematocrit 47%, platelet count 306 000 μl, total protein 4.4 g/dl, creatinine 0.37 mg/dl. Lp(a) level on admission was 750 mg/dl (reference range <300 mg/l). Urinary protein excretion was 1.5 g/24 h.

Since headaches were present without signs of hypertension, a cranial computed tomography was performed. It showed a so-called 'empty triangle sign', indicating a cerebral venous thrombosis (Fig. 1). Following the CT scan the patient suddenly developed a left-sided seizure of approximately 45 min duration. This could only be stopped by i.v. administration of phenobarbital and phenytoin. The seizure was followed by a transient left-sided hemiparesis.

Treatment of cerebral venous thrombosis was started immediately with i.v. administration of heparin (240–350 U/kg/day). In addition, acetylsalicylic acid (4 mg/kg/day) and substitution with antithrombin III was provided. A control CT on the following day revealed two small parasagittal areas of parenchymal intracerebral haemorrhage in the right parietal lobe. Follow-up cranial CT scans demonstrated complete resorption of cerebral haemorrhage and total resolution of cerebral venous thrombosis after 3 weeks. Four weeks later the patient was switched from heparin

to phenprocoumon and this was continued for 4 months.

Treatment with prednisone, albumin and furosemide resulted in complete remission of the nephrotic syndrome. Two years later the patient is free of neurological residues.

Discussion

Patients with a nephrotic syndrome are at increased risk of venous and arterial thrombosis. This includes cerebral venous thrombosis, although this complication has not been frequently reported [1]. A number of factors predispose to thrombosis: apart from altered procoagulatory factors (particularly low antithrombin III), altered fibrinolytic factors and abnormal platelet aggregation, some potentially avoidable factors may also be present, e.g. intravascular volume depletion with haemoconcentration. Of particular interest is the potential relation between elevated Lp(a) in the

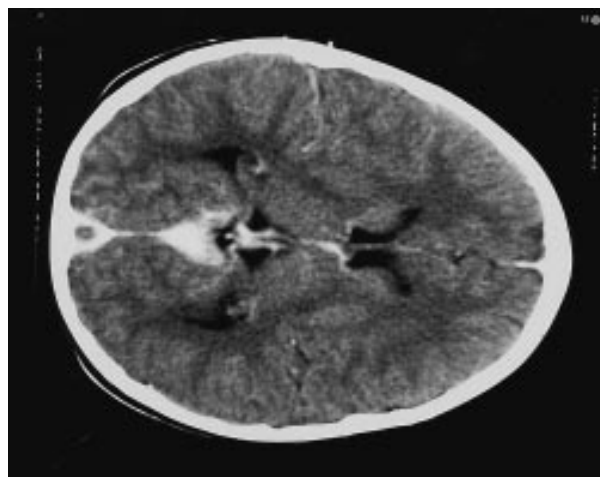


Fig. 1. First CT scan of the patient, showing a thrombus within the superior sagittal sinus surrounded by contrast media—the so-called 'empty triangle sign'.

Correspondence and offprint requests to: F. Pillekamp, M.D., University Children's Hospital, Joseph-Stelzmann-Strasse 9, D-50924 Köln, Germany.

nephrotic syndrome and inhibition of fibrinolysis by the plasminogen system [2,3].

How can the diagnosis of cerebrovenous thrombosis be made? Thrombi in cerebral veins can be directly visualized by CT. Initial and transient hyperdensity of the thrombus (so-called 'cord sign') is followed by hypodensity, intensified by peripheral contrast enhancement, producing a filling defect (so-called 'empty triangle' or 'empty delta sign') [6]. This sign is thought to be pathognomonic [7]. More recent studies indicate, however, that it is frequently found in asymptomatic subjects of the paediatric age group, indicating either limited specificity or frequent occurrence of unrecognized non-occlusive sinus thrombosis in this age group, where dehydration as a potential predisposing condition is frequent [8].

How reliable is the CT scan? Because of the above specificity problems and because results may be normal in up to 26% of cases with cerebral venous thrombosis, a negative CT scan does not rule out the diagnosis. MRI holds great promise, particularly since it is non-invasive and very sensitive to changes in flow [6], whereas angiography has a place only in purely cortical thrombosis, which might not be unrecognized with MRI [6].

Heparin followed by vitamin K antagonists is the treatment of choice for cerebrovenous thrombosis [9]. Some institutions favour early aggressive management with urokinase [10], but there is no general agreement on this point.

Teaching point

Progressive neurological symptoms, e.g. personality changes, vomiting, headache and seizures, in patients

with the nephrotic syndrome may be due to cerebral venous thrombosis. Early recognition (cranial CT) and early intervention (heparin) reduce the risk of neurological sequelae.

References

1. Burns A, Wilson E, Harber M, Brunton C, Sweny P. Cerebral venous sinus thrombosis in minimal change nephrotic syndrome. *Nephrol Dial Transplant* 1995; 10: 30–45
2. Murai A, Miyahara T, Fujimoto N, Matsud M, Kameyama M. Lp(a) lipoprotein as a risk factor for coronary heart disease and cerebral infarction. *Atherosclerosis* 1986; 59: 199–204
3. Querfeld U, Lang M, Friedrich JB, Kohl B, Fiehn W, Schärer K. Lipoprotein(a) serum levels and apolipoprotein(a) phenotypes in children with chronic renal disease. *Pediatr Res* 1993; 34: 772–776
4. Taimela S, Viikari JSA, Porkka KVK, Dahlen GH. Lipoprotein (a) levels in children and young adults: the influence of physical activity. The Cardiovascular Risk in Young Finns Study. *Acta Paediatr* 1994; 83: 1258–1263
5. Fujita T, Saito E, Ohi H, Yasugi T, Hatano M. Lipoprotein(a) predicts the risk of thrombotic complications in the nephrotic syndrome [letter]. *Nephron* 1992; 61(1): 122
6. Anxionnat R, Blanchet B, Dormont D, Bracard S, Chiras J, Maillard S, Louail C, Moret C, Braun, Roland J *et al.* Present status of computerized tomography and angiography in the diagnosis of cerebral thrombophlebitis cavernous sinus thrombosis excluded. *J Neuroradiol* 1994; 21(2): 59–71
7. Viraongse C, Cazenave C, Quisling R, Sarwar M, Hunter S. The empty delta sign: frequency and significance in 76 cases of dural sinus thrombosis. *Radiology* 1987; 162: 779–785
8. Davies RP, Slavotinek JP. Incidence of the empty delta sign in computed tomography in the paediatric age group. *Australas Radiol* 1994; 38(1): 17–19
9. Einhäupl K, Villringer A, Pellkofer M, Haberl RL, Pfister HW, Schmiedek P, Meister W. Heparin treatment in sinus venous thrombosis. *Lancet* 1991; 338: 597–600
10. Horowitz M, Purdy P, Unwin H, Carstens G, Greenlee R, Hise J, Kopitnik T, Batjer H, Rollins N, Samson D. Treatment of dural sinus thrombosis using selective catheterization and urokinase. *Ann Neurol* 1995; 38(1): 58–67