

## The Kluver-Bucy Syndrome

I. Gościński, S. Kwiatkowski, J. Polak, and M. Orłowiejska\*

Institute of Neurology, Department of Neurotraumatology, Jagiellonian University, Medical Faculty, Kraków, Poland

### Summary

Evolution of psychological disorders following head injury including memory and other cognitive disorders are common. The best known are psychiatric disturbances of various kinds after lesions of the frontal lobes.

Cognitive, behavioural and emotional disorders are not usually seen in patients with bilateral temporal lesions. In our Department of Neurotraumatology we have observed 4 patients with posttraumatic lesions localized bitemporally. They developed Kluver-Bucy syndrome – rarity in human pathology – combined with three or more of the following symptoms and signs: increased oral activity, hypersexuality, hypermetamorphosis, memory disorders, placidity, loss of people recognition, bulimia.

Several symptoms responded dramatically to carbamazepine. We conclude that it may be a useful agent in the treatment of this unusual syndrome.

**Keywords:** Kluver-Bucy syndrome; organic mental disorders; temporal lobe injuries; carbamazepine.

### Introduction

Craniocerebral injuries (especially severe with initial GCS between 3 and 7 points) with prolonged loss of consciousness produce various psychological disorders in the recovery period. They are most frequently associated with bilateral frontal lobe damage and treatment is limited to administration of neurotropic drugs. Much rarely bilateral involvement of the medio-basal temporal lobes leads to changes of expression of affects, moods, drives referred to as the Kluver-Bucy syndrome.

An experimental model of the Kluver-Bucy syndrome was produced by bilateral removal of the temporal lobe in rhesus monkeys [1]. Simple extrapolation of symptoms encountered in animals to human pathology may be controversial. However, over 200 cases described in the literature indicate that the man-

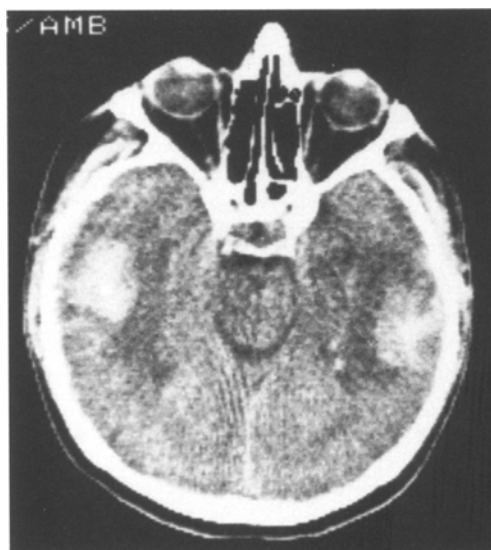

Fig. 1. CT of patient 2 revealed intracerebral haematoma localized bitemporally

ifestations of bilateral temporal injury in man (Fig. 1) are strong enough to form a separate disease entity [2]. Therefore, axial symptoms described by Kluver and Bucy in 1937 are still valid. They are as follows: 1. Visual agnosia (probably tactile, auditory); 2. Oral tendency; 3. Hypermetamorphosis; 4. Changes in behaviour; 5. Increase in sexual activity (homo-, hetero- and autosexual); 6. Changes in dietary habits.

In the present study only the first symptom referring to gnostic disorders has been changed. They have been diagnosed as loss of ability to recognize objects.

### Patients and Methods

Over the last 20 years of our Neurotraumatological Department has encountered complete Kluver-Bucy syndrome in only four cases.

\*Independent clinical neuropsychologist

Table 1. *Clinical Features*

Patient	1	2	3	4
Age	23	67	35	32
GCS on admission	4	7	6	8
Mechanism of injury	RA	F	H	H
Duration of higher neural activity disorders	119 days	14 days	30 days	21 days
Visual agnosia	—	—	+	+
Oral tendency	+	+	++	+
Hypermetamorphosis	—	+	++	—
Changes in behaviour	++	++	+	++
Increase in sexual activity	++	++	++	+
Changes in dietary habits	++	++	++	+
	bulimia	bulimia		

*Case 1.* In 1970 he was hit by a car and suffered from craniocerebral injury. He underwent emergency surgery — removal of left-sided subdural haematoma through burr holes. Right-sided cerebral oedema was also detected. For three months the patient was in coma. During the recovery complete Kluver-Bucy syndrome was diagnosed (see Table 1). The EEG revealed pathological signs in the temporal leads bilaterally, with the right-sided predominance.

*Case 2.* In 1991 this man suffered from craniocerebral injury with 10 min loss of consciousness after falling 3 m. Since the trauma he exhibited sluggishness of psychomotor reactions, speech disorders, lack of dependence, no control of sphincters, altered behaviour. CT (Fig. 1) revealed an intracerebral haematoma bitemporally.

*Case 3.* This man was found unconscious with a head injury. On admission he regained consciousness, was aphasic and had right-sided hemiparesis. CT revealed multiple cerebral contusions and a haemorrhage in the left frontal lobe.

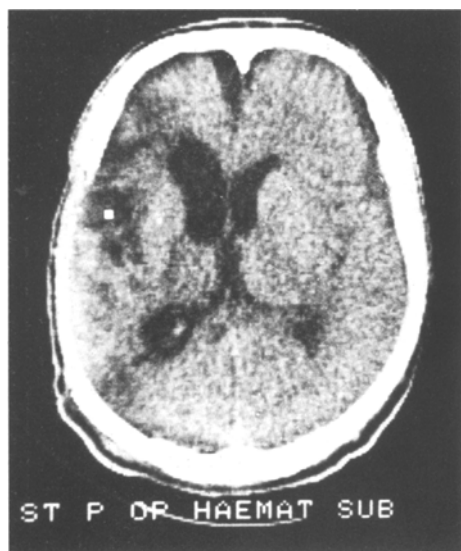


Fig. 2. Complete Kluver-Bucy syndrome (case 4). No CT evidence of posttraumatic bilateral lesions. One month after removal of epidural haematoma

Table 2. *GOS Assessment at Discharge, 6 Months and 1 Year After Trauma*

Case	GOS		
	At discharge	6 months after trauma	1 year after trauma
1	3	4	4
2	3	3	3
3	3	4	5
4	3	4	5

*Case 4.* In 1991 this man suffered from head injury in unknown circumstances. He was submitted to emergency surgery due to left-sided epidural haematoma. After the operation he gradually regained consciousness. The clinical manifestation, apart from right-sided hemiparesis, included mainly changes in behaviour. Complete Kluver-Bucy syndrome developed even though no CT evidence of bitemporal damage (Fig. 2) was found.

Every day the patients underwent neurological examination in the presence of a neuropsychologist. Table 1 summarises the results of this assessments.

Carbamazepine (Tegretol CR 400) in a dose of 400 mg twice a day was given to cases 2,3 and 4 in order to limit paroxysmal changes in the temporal focus, the site of injury in the Kluver-Bucy syndrome. Blood level of carbamazepine was measured at 5 days, and if necessary its dose was adjusted to maintain the level of 8–10 mg/ml.

## Results

The treatment is presented in the material section. Its effect was evaluated by GOS on control examination at discharge, 3 and 6 months after trauma. The patients showed improvement when they have been given carbamazepine during hospitalisation and after discharge (Table 2).

A detailed follow-up analysis was carried out in case 1. Seven years after the injury a psychological examination revealed markedly reduced intellectual skills (on the Wechsler's scale) but only nonverbal

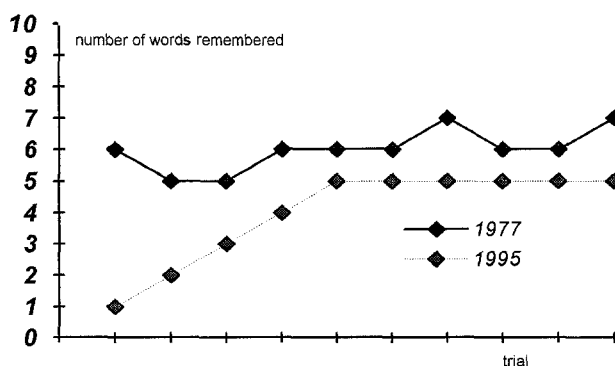


Fig. 3. Learning curves

functions, making a difference of 46 points in favour of verbal functions. The intelligence quotient II full 101 (verbal scale 123, nonverbal 77).

Twenty-five years after the injury the patient was submitted to a control examination. A history elicited from him indicated that despite intensive psychiatric pharmacotherapy he was very irritable, aggressive in verbal expression and behaviour, he had problems with memory, he showed complete lack of interests and no libido. Because of the patient's attitude, sluggishness of his reactions, unwillingness to be examined we were unable to repeat Wechsler's test.

We detected massive disorders of short memory, dynamic apraxia, total lack of kinetic melody, lack of drive, sluggishness and minimal ability to acquire new memories. Comparison of the learning curves from 1977 and 1995 revealed progressive deterioration of intellectual functions (Fig. 3).

Examination of cases 2 and 4 revealed prolonged psychiatric disorders, mainly social maladaptation, aggression and auto-aggression.

## Discussion

The main clinical manifestation in Kluver-Bucy syndrome was a tendency to place into the patient's mouth all types of objects within his reach [3], including inedible and even dangerous items such as cigarettes or objects with sharp edges, and excrements. The movements were so persistent and compulsive that the patients had to be restrained. It should be noted that the oral tendency is not a combination of grasping with the hands and mouth. The hands are used only as help, and grasp reflexes of the hands reflecting a lesion of the frontal cortex or its connections are not always present. This indicates only a more advanced injury of the primary structures in the Kluver-Bucy syndromes. It was confirmed by Pilleri in 1961 [4] who showed that lesions of the temporal lobe released oral grasping in the same way that lesions of the frontal lobe produced hand grasping and deliberative symptoms. The patient with the Kluver-Bucy syndrome can be easily attracted by any visual stimulus (hypermetamorphosis). An irresistible impulse to touch every object in sight led to placing it into the mouth and most frequently spitting it out.

Changes in sexual activities reflected increased libido. Hetero- and homosexual choice of partners, masturbation without concern about observers are the main forms of abnormal sexual behaviour. These manifestations do not correlate with the patient's

emotional behaviour. They are usually calm, manageable, indifferent in mood and with flat emotional reactions. The presence of these entirely different signs in one disease entity can be accounted for by disruption of the so-called Papez regulatory circuit, an anatomical substrate for the mechanisms of expression and creation of affects, moods associated with instinctive activities [5]. Appetite disorders in the form of bulimia frequently develop in the recovery period.

Localizing studies (clinical and anatomical) indicate the involvement of the phylogenetically old medial temporal lobe regions and bilateral lesions of Ammon's horn are a *sine qua non* for the production of the syndrome [6]. The mechanism of injury in these cases, apart from direct lesions of the temporal lobe tissue involves also compression of both hippocampi [7]. Radiological examination in our cases only in patient 2 revealed bitemporal haematomas (Fig. 1); in the remainder posttraumatic oedema was detected, which was clinically manifested by functional disorders.

Administration of carbamazepine caused rapid regression of the symptoms [8]. However, a late neuropsychological examination, after 25 years in case 1 and 3 years in case 2 revealed persistence of psychological disorders. Case 4 could not be examined because he stays in a psychiatric ward due to aggression, including auto-aggression.

The literature reports also emphasise persistence of psychological disorders, frequently the Kluver-Bucy syndrome develops into the Korsakow syndrome.

Although follow-up examination of case 1 does not reveal persistent Kluver-Bucy syndrome and Korsakow syndrome, neurological and psychiatric evaluation of the patient, including EEG, gives grounds for the diagnosis of posttraumatic temporal syndrome. The patient received carbamazepine and he gradually improved. A neuropsychological examination revealed deterioration of intellectual skills (Wechsler's test), but only of nonverbal functions, making a difference of 46 points in favour of verbal functions. This confirms that the patient suffered from a bitemporal injury associated with transient Kluver-Bucy syndrome.

## Conclusions

1. Clinical manifestations of Kluver-Bucy syndrome develop not only in patients with CT evidence of morphological lesions in the temporal lobes.
2. The presence of clinical symptoms of Kluver-

Bucy syndrome should be an indication for the use of carbamazepine as in temporal epilepsies.

3. Follow-up examinations in patients with post-traumatic Kluver-Bucy syndrome confirm beneficial effects of chronic treatment with carbamazepine.

4. A clinically rare Kluver-Bucy syndrome should be taken into account when evaluating the sequelae of severe craniocerebral injuries, even if there is no CT or EEG evidence of morphological lesions.

## References

1. Kluver H, Bucy PC (1938) An analysis of certain effects of bilateral temporal lobectomy in the rhesus monkey, with special reference to psychic blindness. *J Psychol* 5: 33–54
2. Aichner F (1984) Phenomenology of the Kluver-Bucy syndrom in man. *Fortschritte Neurologie Psychiatrie* 52 (11): 375–397
3. Gerstenbrand F, Poewe W, Aichner F, Saltuari L (1983) Kluver-Bucy syndrome in man: experiences with posttraumatic cases. *Neurosci Biobehav Rev* 7(3): 413–417
4. Pilleri G (1961) Orale Einstellung nach Art des Kluver-Bucy Syndroms bei hirnatropischen Prozessen. *Schweiz Arch Neurol Psychiat* 87: 286–298
5. Vinken PJ, Bruyn GW (1969) *Handbook of clinical neurology*. North Holland, Amsterdam, pp 349–356
6. Duus P (1983) *Neurologisch-topische Diagnostik*. Thieme, Stuttgart
7. Martynów R, Bemowa Z, Pourazowy ZKB (1987) *Psychiatria Polska* 5: TXXI
8. Stewart JT (1985) Carbamazepine treatment of a patient with Kluver-Bucy syndrome. *Clin Psychiatri* 46(11): 496–497

## Comment

It is more than evident that patients with contusions and/or haematomas of the brain do not only have neurological deficits, but also psychiatric disorders as a result of such a lesion. The psychiatric disorders in such cases are very complex, since the lesions do not only affect the areas demonstrated by CT (haematomas, hypodensity areas ...) but also broader areas damaged by shearing forces at the time of the initial trauma.

This report indicates the complexity of the problem of treating neurotrauma cases, a problem which lies in the exact assessment of the lesion, treatment and follow-up; these are procedures which should always be undertaken as team work, not only during the initial treatment but also during neurorehabilitation, and later on, during psychiatric and/or psychological treatment.

It is to be hoped that this report will provide the incentive for similar, well-organized and considered prospective studies of the problem.

*V. Dolenc*

Correspondence: Jarosław Polak, M.D., Institute of Neurology, Department of Neurotraumatology, 3, Botaniczna str., PL-31-503 Kraków, Poland.