

Dissecting Aneurysm of the Internal Carotid Artery After a Mandibular Osteotomy

HIROYUKI SUZUKI, DDS, PHD,* ETSURO SAITO, DDS,†
AND KENJI HASHIMOTO, MD, DDS, PHD‡

Sagittal split ramus osteotomy (SSRO) of the mandible is widely practiced procedure for correcting jaw deformities. Behrman¹ reported that the most commonly encountered complications were relapse, hemorrhage, trauma to the mandibular nerve, edema, fracture of the ramus, necrosis, sequestration of bone, and infection. Neurologic complications, including inferior alveolar nerve hypesthesia and anesthesia and facial nerve injury, also have been known to occur. Cerebral infarction caused by a dissecting aneurysm of the internal carotid artery after SSRO of the mandible is very rare.

Report of Case

A 25-year-old Japanese woman was referred to the department of oral and maxillofacial surgery at Hamamatsu University Hospital for surgical correction of her prognathism. In profile, there was mild protrusion of the lower lip. Preoperative cephalometric measurements included an SNA of 87.3° and an, SNB of 83.5°. It was determined that the patient should undergo bilateral SSROs of the mandible to correct the skeletal Class III profile. She was admitted to the hospital on February 14, 1994. On admission, her vital signs were normal and the results of the general physical examination were also within normal limits. The operation was performed on February 17, 1994, under general anesthesia. Bilateral SSROs were performed using the Obwegeser-Dal Pont method. The mandible was retruded approximately 5 mm and titanium miniplate fixation was placed. Postoperative maxillomandibular fixation was not used. The operation time

was 170 minutes there were no major intraoperative complications, and the initial postoperative course was uneventful.

About 20 hours after the operation, the patient complained of headache. It was regarded as a migraine headache and an anodyne was administered to her. Twenty-nine hours after the operation, she became drowsy and did not respond to verbal commands (Glasgow Coma Scale; E3 M6 VA). Physical examination showed that the blood pressure and pulse rate were normal. A left carotid bruit was heard. Cranial nerve examination showed that she had a right facial palsy. The pupils were asymmetric, with the left smaller than the right, later believed to be a Horner's syndrome. Motor nerve examination showed right hemiplegia. Because of these findings, a presumptive diagnosis of a cervical carotid injury was made. A Babinski sign was not observed on the right side.

Bilateral carotid cerebral arteriography via the femoral artery was performed emergently. The angiogram showed a filling defect in the left internal carotid artery about 2 to 3 cm above the bifurcation, and extending into the cavernous portion (C4) of the vessel. The angiogram was suggestive of a dissecting aneurysm of the left internal carotid artery (Fig 1) and therefore, intra-arterial infusion of Urokinase (960,000 IU) was performed immediately. After about half an hour of urokinase therapy, brisk bleeding from the bilateral operated area was encountered. A pressure pack was placed between the proximal and distal fragments and, after that, the patient was intubated. An hour post-therapy, a repeated angiogram showed mild recanalization of the left internal carotid artery (Fig 2). She was left intubated and transferred to the intensive care unit (ICU). Next morning she was extubated, and computed tomography (CT) was performed with contrast medium. Left putaminal hemorrhage was detected (Fig 3).

On March 1 (11th postoperative day), she was transferred to the neurosurgery ward. Within a month of the occurrence, there was a gradual resolution of her right hemiplegia. In April she was discharged from the hospital. One year later, the patient had only a minimal right upper extremity paresis.

Discussion

Injuries to the internal carotid artery are a well-known complication of maxillofacial trauma^{2,3} but are a rare complication after orthognathic surgery.⁴ Injuries to the internal carotid artery during orthognathic

Received from the Department of Oral and Maxillofacial Surgery, Hamamatsu University School of Medicine, Hamamatsu-city, Shizuoka Prefecture, Japan.

* Assistant Professor.

† Resident.

‡ Professor.

Address correspondence and reprint requests to Dr Suzuki: Department of Oral and Maxillofacial Surgery, Hamamatsu University School of Medicine, 3600 Handa-cho Hamamatsu-city, Shizuoka Prefecture, 431-31 Japan.

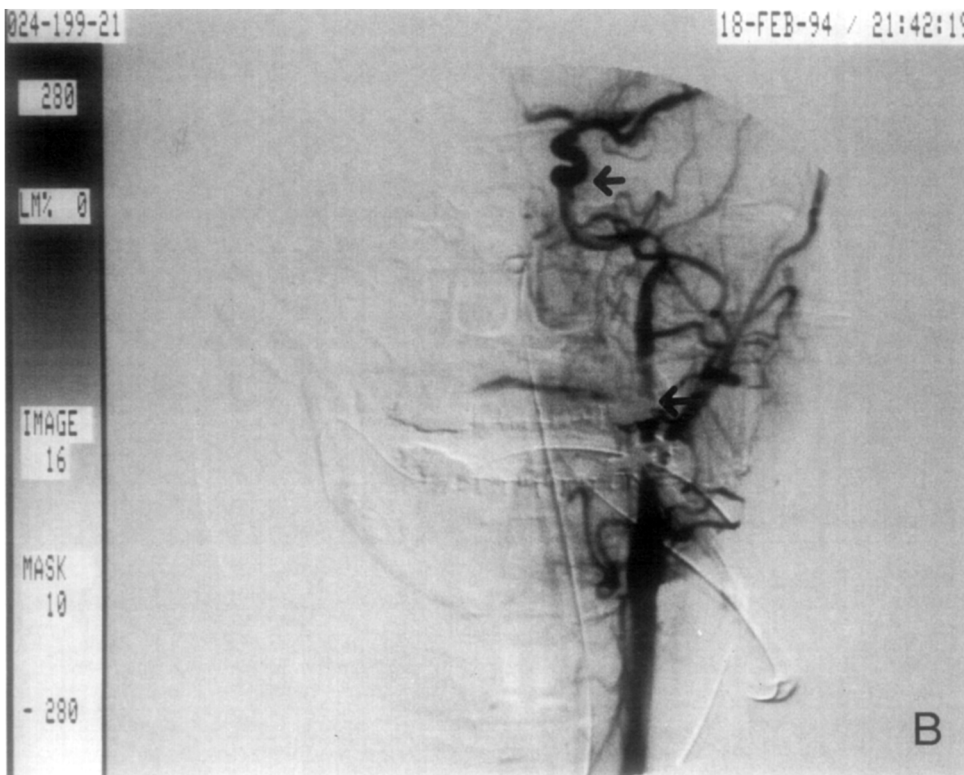
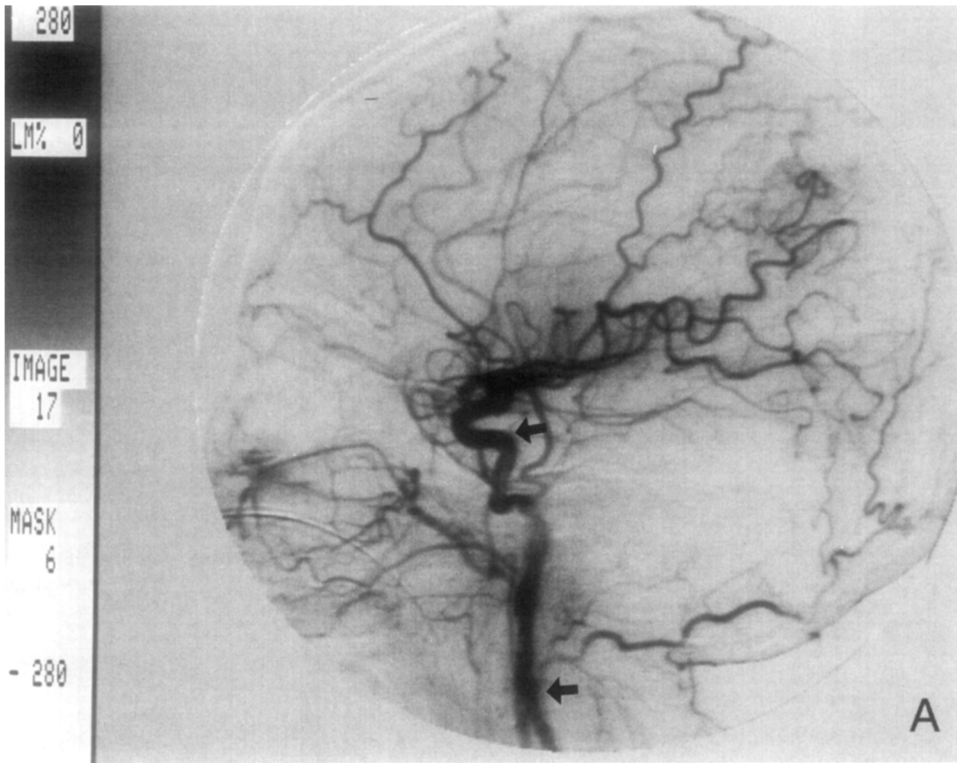


FIGURE 1. A carotid angiogram showing a filling defect distal to the bifurcation of the left internal carotid artery extending into the cavernous portion. A, Lateral view, B, frontal view.

FIGURE 2. A carotid angiogram after urokinase therapy showing slight recanalization of the left internal carotid artery.

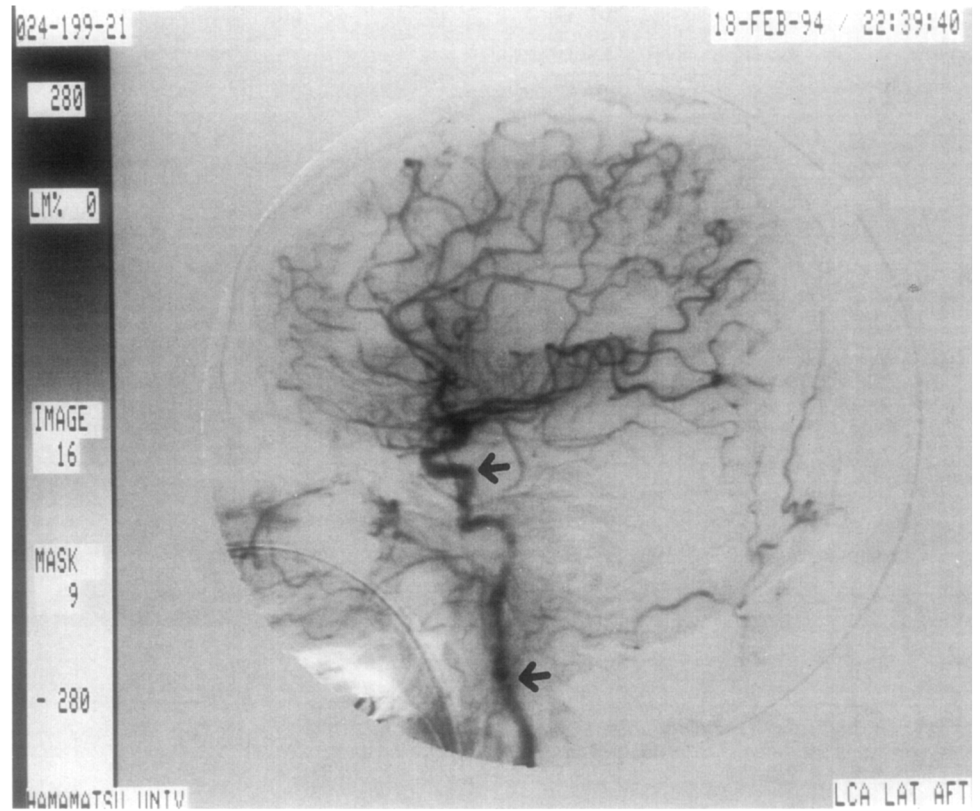
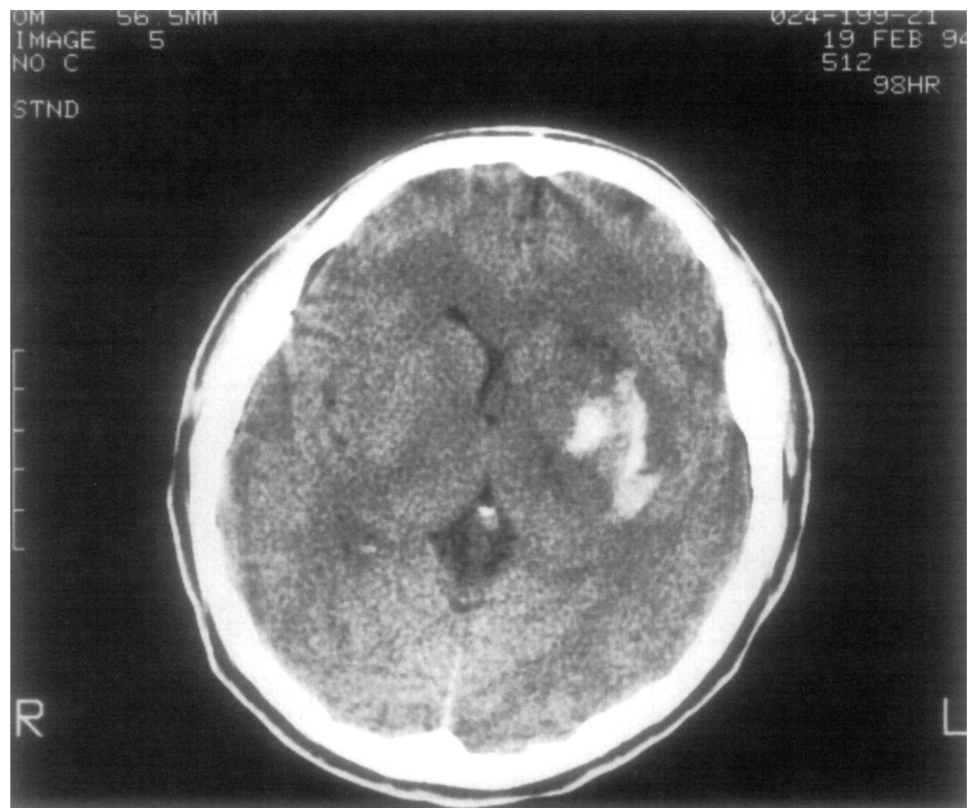


FIGURE 3. Computed tomogram after urokinase therapy showing left putaminal hemorrhage.



surgery can be direct or indirect and can occur anywhere from the bifurcation of the carotid artery in the neck to intracranially. Lanigan⁴ has shown that a direct injury to the carotid artery can occur after a skull base fracture in the area of the carotid canal or foramen lacerum. Anatomic variations of the base of the skull, such as incomplete ossification or bony defects in the vicinity of the cavernous sinus, can occur and can place the intrapetrous portion of the carotid artery in peril when maxillary orthognathic surgery is performed. Indirect injury, the most likely mechanism, is due to a sudden forceful stretching of the internal carotid artery in the neck over the upper cervical spine by cervical hyperextension and contralateral rotation of the head.

In the literature, there are some reports of aneurysms of the carotid artery after orthognathic surgery, and almost all of these occurred as a complication of Le Fort I osteotomy.⁵⁻⁷ After SSRO, there are two reports of a carotid arterial pseudoaneurysm⁸ and occlusion,⁹ but a dissecting aneurysm of the carotid artery after SSRO has not been reported previously.

In this case, although a definite cause cannot be established, the following are possibilities:

1. Direct trauma to the left internal carotid artery caused when the mandibular ramus was moved posteriorly
2. Direct trauma to the left internal carotid artery by an osteotome or Obwegeser Haken Retractor
3. Indirect trauma due to cervical hyperextension and contralateral rotation of the head

Contralateral rotation of the head at the atlantoaxial joint stretches the artery and, in addition, causes rota-

tion of the ipsilateral mass of the atlas anteriorly, forcing it against the artery. If both hyperextension and rotation occur in combination, it could cause impingement of the bone on the artery, resulting in acute local compression and stretch, and an intimal tear.⁴

This finding in this case suggests that the surgeon who performs a mandibular ramus split osteotomy should give consideration to protection of internal carotid artery to avoid direct trauma to it, and that good head position for the patient must be ensured and cervical hyperextension with contralateral rotation of the head must be avoided.

References

1. Behrmann SJ: Complications of sagittal osteotomy of the mandibular ramus. *J Oral Surg* 30:554, 1972
2. Silvernail WI, Croucher DL, Byrd BR, et al: Carotid artery injury produced by blunt neck trauma. *South Med* 68:310, 1975
3. Robinson NA, Flotte CT: Traumatic aneurysms of the carotid arteries. *The American Surgeon* 123, 1974
4. Lanigan DT: Injuries to the internal carotid artery following orthognathic surgery. *Int J Adult Orthodont Orthognath Surg* 3:215, 1988
5. Otterloo JJ, Tuinzing DB, Greebe RB, et al: Intra- and early postoperative complications of the Le Fort I osteotomy. *J Craniomaxillofac Surg* 19:217, 1991
6. Lanigan DT, Hey JH, West RA: Major vascular complications of orthognathic surgery, hemorrhage associated with Le Fort I osteotomies. *J Oral Maxillofac Surg* 48:561, 1990
7. Yeo JF, Loh FC, Egedie P, et al: Serious circulatory disturbance after Le Fort I osteotomy: A case report. *J Craniomaxillofac Surg* 17:222, 1989
8. Mercier J, Delaire J: Osteotomie sagittale des branches montantes de la mandible. *Rev Stomatol Chir Maxillofac* 2:94, 1984
9. Sanni K, Campbell R, Rosner M, et al: Internal carotid arterial occlusion following mandibular osteotomy. *J Oral Maxillofac Surg* 42:394, 1984