



# Grand rounds from international lupus centres—Edited by R Lahita

## LUPUS AND CEREBROVASCULAR ACCIDENTS

AE Ware and A-B Mongey

Division of Immunology, University of Cincinnati College of Medicine, PO Box 670563, Cincinnati, OH 45267-0563, USA

**Keywords:** cerebrovascular accidents; SLE; central nervous system

### Case history

CK is a 38 year old Caucasian female that presented to the hospital complaining of three days of fevers, nausea, vomiting and blurry vision. In addition to these symptoms, she reported a six-month history of polyarthralgias accompanied by knee swelling, Raynaud's phenomenon, hair loss, oral ulcerations and an erythematous malar rash over her face. Her past medical history was significant for a twenty-year history of epilepsy, Stage I adenocarcinoma of the cervix with a recent normal PAP smear, recurrent UTIs, fibrocystic breast disease and a tubal ligation. Her only medication at the time of presentation was dilantin 200 mg every other day which she had been taking for eighteen years with no reported seizure activity within the last 10 y. She had a 46 pack/year smoking history. Socially, she was divorced, had one child living with her, and worked periodically as a licensed practical nurse.

At the time of admission she was afebrile and her vital signs were stable. Her eyelids and palpebral fissures were edematous and a malar rash was present. A few shallow oral ulcers were seen on the buccal mucosa and hard palate. Mild diffuse alopecia was evident. Nonpalpable purpuric lesions were noted over her arms and legs. Splinter hemorrhages were present at multiple nailbeds. A four-centimeter left axillary node was palpable in addition to multiple small nodes in the posterior cervical, supraclavicular and inguinal chains. The left knee had palpable synovitis. On neurological examination, all cranial nerves were intact and sensation was intact to pinprick and light touch discrimination. Motor examination was without demonstrable upper or lower extremity weakness. Reflexes were brisk and symmetric.

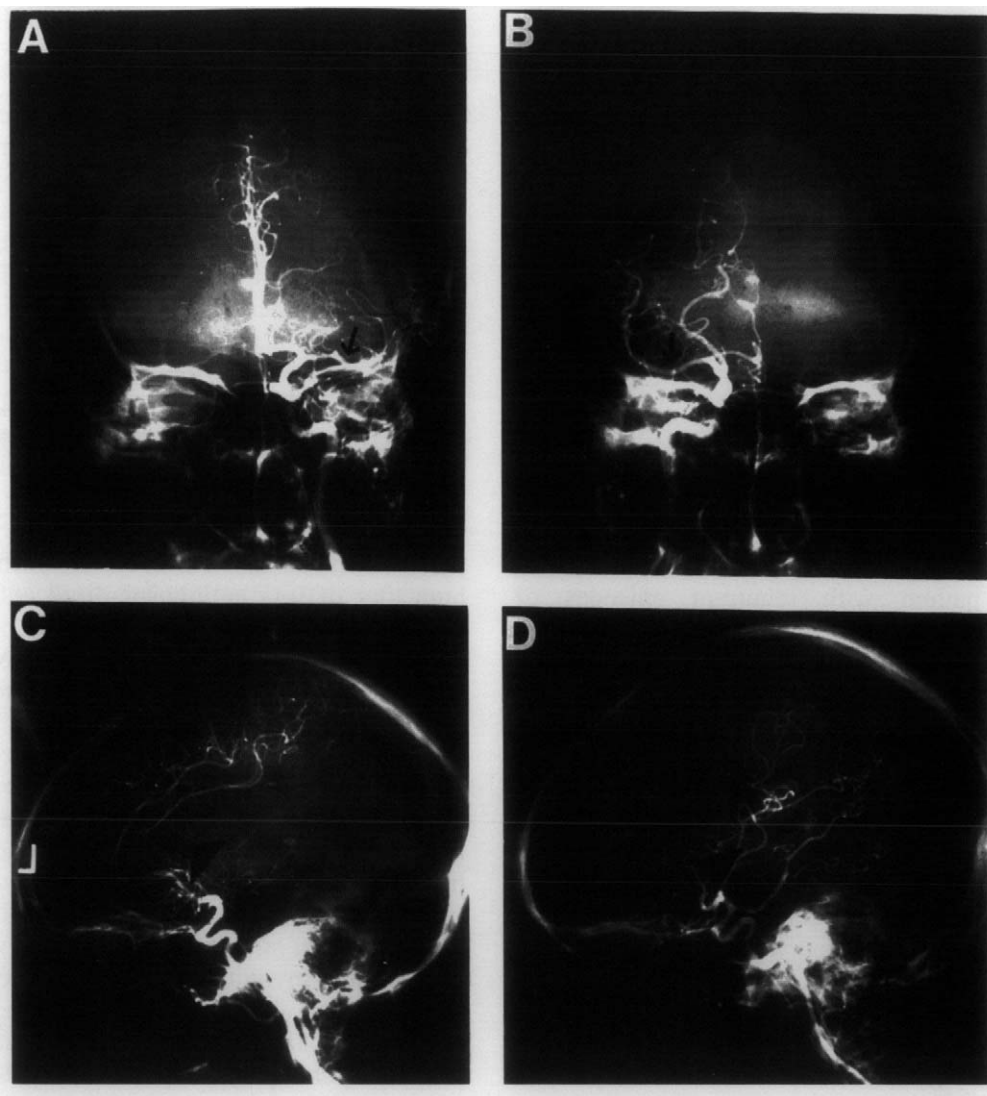
Admission laboratory data was significant for a

white blood cell count of 6.5, a differential of 77 neutrophils, 14 bands, two lymphocytes and six monocytes, a hematocrit of 44 and a platelet count of 214. The serum blood urea nitrogen and creatinine were 19 and 1.1 respectively. A urinalysis showed 3+ proteinuria, 2-4 red blood cells and 8-10 red blood cell casts. A fluorescent ANA was positive at a titer of 1:320 in a homogeneous pattern, a dsDNA was elevated to 36.5% by the Farr method and an ENA panel was RNP positive but Sm negative by immunodiffusion. The C3 component of complement was markedly reduced at a level of eight. A C4 was undetectable. A chest X-ray revealed a small left-sided pleural effusion.

The patient underwent a skin biopsy of a purpuric lesion that was consistent with a leukocytoclastic vasculitis. An ophthalmology consultation was obtained and a fundoscopic exam showed a low grade choroiditis and uveitis. The patient refused further inpatient treatment including a fluorescein angiogram and a kidney biopsy. She was discharged with a clinical diagnosis of systemic lupus erythematosus (SLE) and placed on 15 mg of prednisone twice daily and prednisone acetate 1% eye drops. An outpatient kidney biopsy was scheduled for the following week. The patient was not seen again until the day following the scheduled appointment when she presented to the emergency room complaining of the acute onset of right-sided flank pain. She was placed on 60 mg of solu-medrol twice daily for presumptive lupus nephritis. A renal ultrasound was significant only for mild diffusely increased echogenicity. A CAT scan of the abdomen showed a right renal infarct. A percutaneous renal biopsy was performed. Several hours following the biopsy she was found on the floor of her hospital room. A physical exam at that time revealed a complete right sided hemiparesis, a right facial droop and an expressive aphasia. A non-contrast CAT scan of the head was significant for a left fronto-temporal infarct and ischemic changes in the left corona radiata. A subsequent MRI scan confirmed an

Correspondence: Dr AE Ware.

Received 28 January 1997; accepted 22 April 1997



**Figure 1.** (A) The cerebral angiogram of the left internal carotid artery—anterior-posterior view. The arrow points to an occlusion of the proximal middle cerebral artery branch. (B) The cerebral angiogram of the right internal carotid artery in the same patient—anterior-posterior view. Normal filling of the middle cerebral artery branch is seen. (C) The cerebral angiogram of the left internal carotid artery—lateral view. The arrow points to the area where the sylvan, angular, and small distal middle cerebral branches should be visualized. Note the absence of vessels in this area when compared to a similar view on the right in D.

acute left frontal and temporal lobe infarct in the distribution of the left middle cerebral artery, contralateral right frontal lobe ischemia and a small left cerebellar infarct. A cerebral angiogram showed occlusion of the sylvan and angular branches of the left middle cerebral artery and occlusion of several smaller distal branches (Figure 1). A transthoracic echocardiogram was within normal limits without evidence of thrombi or valvular abnormalities. The patient was unable to tolerate a transesophageal echocardiogram. Carotid Dopplers were performed and showed a 40% stenosis of the left internal carotid. The right internal carotid was without abnormalities. Additional laboratory data was negative for a lupus anticoagulant by a dilute Russell viper venom assay,

but IgG and IgM anticardiolipin antibodies were elevated at 67 GPL (normal < 23) and 21 MPL (normal < 11) respectively by EIA.

The kidney biopsy was significant for focal proliferative glomerulonephritis and a single thrombosed capillary loop consistent with the patient's clinical diagnosis of SLE. She subsequently received a bolus of 1 gm of solu-medrol for three days in addition to a bolus of 750 mg/m<sup>2</sup> of intravenous cyclophosphamide for multi organ disease. She was also anticoagulated with warfarin because of the likelihood of a thrombotic and/or embolic etiology for the CVA related to hypercoagulability and anticardiolipin antibodies. Over the next several weeks, the steroids were gradually tapered. She required intense physical

and occupational rehabilitation, but was able to be discharged to her home with only mild residual right-sided arm and leg weakness and slightly slurred speech. She has continued cyclophosphamide and warfarin treatment and has done well with no recurrences of disease at one year follow-up. The INR has been maintained between 3 and 3.8. Although complement levels have normalized, the dsDNA titers remain moderately elevated.

## Discussion

Cerebrovascular accidents (CVAs) are seen in approximately 4–15% of patients with SLE.<sup>1</sup> The first reference in the medical literature addressing this serious complication appeared in 1903 when Osler described a patient with recurrent episodes of hemiplegia and aphasia.<sup>2</sup> Based on concomitant appearance of vasculitic skin lesions, he postulated a vasculitis-related etiology for CVAs in SLE. Since this report, many more cases have been described. These are most commonly seen in the setting of active systemic disease. However, CVAs can present as isolated central nervous system (CNS) events without evidence of multiple organ involvement. The first event typically occurs within the first five years of SLE, but later onset has been described. Morbidity and mortality rates associated with CVAs in SLE are 35% and 28% respectively, with recurrent events occurring in a high percentage of patients.<sup>3</sup>

Investigations have revealed a number of possible etiologies of CVAs in SLE patients. These include cerebral infarction secondary to emboli from left-sided cardiac valvular lesions (verrucous or Libman–Sacks endocarditis), thrombosis associated with a coagulopathy, a rare polyarteritis-type vasculitis as originally suggested by Osler, fibrin platelet occlusion of intracranial arterioles, a noninflammatory arteriopathy which may be due to accelerated atherosclerosis and which leads to microinfarction, and intraparenchymal or subarachnoid hemorrhage.<sup>4</sup>

Several of these etiologies were the possible cause of the CVA in our patient. The abrupt and profound clinical presentation along with the findings on MRI and cerebral angiogram suggest a cardioembolic source despite the negative transthoracic echocardiogram. Autopsy studies have suggested a prevalence of cardiac valvular lesions in SLE ranging from 35–59%.<sup>5</sup> Emboli to cerebral vessels originating from cardiac valvular lesions and resulting in CVAs have been well documented in several studies.<sup>6,7</sup> Their association with antiphospholipid antibodies has been convincingly shown.<sup>8</sup> Antiphospholipid antibodies are

found in up to 44% of SLE patients and were also seen in our patient.<sup>1</sup>

In addition to cardiac valvular lesions, these antibodies have been associated with spontaneous arterial and venous thromboses in multiple vessels throughout the body including those in the brain. Harris and colleagues<sup>9,10</sup> were the first to associate the presence of these antibodies with thrombosis and focal neurological deficits in SLE. In 1989, Asherson *et al.*<sup>11</sup> confirmed the strong association between antiphospholipid antibodies and cerebrovascular disease in SLE. The mechanisms by which these antibodies lead to hypercoagulability are speculative. Possibly, they cause endothelial damage leading to a loss of arachidonic acid release resulting in an inhibition of prostacyclin formation. Alternatively, they may directly inhibit thrombomodulin, an important cofactor in the prevention of thrombosis. The high titer of IgG antiphospholipid antibodies plus a thrombosed vessel seen on a kidney biopsy suggests an increased risk of spontaneous thrombosis in our patient that could have resulted in the cerebral infarcts seen on her MRI.

More recently, another vascular lesion has been attributed to antiphospholipid antibodies. A distinctive chronic cerebral vasculopathy has been described in three patients with these antibodies, one of whom also had SLE.<sup>12</sup> Histopathologic studies revealed obstruction of multiple leptomeningeal vessels secondary to fibrin thrombi and proliferation of intimal fibrous tissue and myointimal cells. Various stages of recanalization were observed similar to the plexogenic arteriopathy often described in the small vessels in primary pulmonary hypertension. The obstructed vessels could be traced to underlying multiple small cortical infarcts. It seems unlikely this was a major contributor to the CNS disease in our patient as her MRI does not reveal evidence of such cortical lesions.

Vasculitis due to immune complex deposition, *in situ* immune complex formation in vessel walls, or T cell mediated damage in large or small vessels could certainly contribute to CNS pathology as it does elsewhere in the body in SLE. However, in an autopsy series of twenty-four patients with SLE, of whom 75% had clinical evidence of neurologic disease, Johnson and Richardson<sup>13</sup> found only three patients with evidence of CNS vasculitis. This suggests vasculitis is a rare cause of CNS disease in SLE. The presence of choroiditis and leukocytoclastic vasculitis in our patient is intriguing and raises the possibility of a coexistent CNS vasculitis. The results of the MRI and cerebral angiogram argue against this type of disease.

Cerebral infarction from occlusion of small vessels by platelet and fibrin thrombi has been reported in patients with SLE.<sup>14</sup> The exact mechanism of platelet

and fibrin thrombi formation is not known, but possibly immune complex deposition in vessel walls leads to platelet aggregation enhancing clot formation especially in the presence of antiphospholipid antibodies. Ellison *et al* examined necropsy specimens of small cerebral blood vessels from six patients with SLE and CNS disease. He found fragments of platelet membranes in four. It would be impossible to definitively implicate this as a pathogenic mechanism in our patient without a pathology specimen. However, the MRI and cerebral angiogram suggest that occlusion of large vessels is responsible for our patient's clinical presentation.

The most common small vessel abnormality reported in CNS SLE is a noninflammatory vasculopathy secondary to vessel wall hyalinization and endothelial proliferation. Microinfarcts and hemorrhages in the areas supplied by these abnormal vessels have been described.<sup>13</sup> These lesions have been correlated with the finding of scattered punctate periventricular and predominantly white matter hyperintense areas on MRI. These lesions were notably absent in our patient. The cause of this vasculopathy has been attributed to various etiologies including direct damage by antineuronal antibodies, an indirect effect of immune complex deposition in the choroid plexus with subsequent cytokine release, hypertension, antiphospholipid antibodies, the mechanism of which has been described earlier, and accelerated atherosclerosis. This last etiology is gaining increasing recognition as a possible cause of CNS disease. The NZ(W × B)F1 mouse, a hybrid bred from crossing several strains of mice with lupus-like disease, is notable for the development of an immune complex-mediated glomerulonephritis.<sup>16</sup> They are also known to have a very high incidence of coronary vascular disease. Deposition of PAS-positive material in the intimal and medial portions of affected coronary vessel walls is seen. Inflammatory cell infiltration is sparse. The demonstration of immune complex deposition in the affected vessel walls by immunofluorescence and electron microscopy coupled with the coexistence of an immune-complex glomerulonephritis suggests an immune complex-mediated etiology to the pathogenesis of atherosclerosis in SLE.<sup>17</sup> Immunofluorescence and electron microscopy have also shown immune complex deposition in the coronary vessels of human patients with SLE and atherosclerotic coronary disease.<sup>18</sup> Interestingly, many of these lesions are accompanied by thrombosis. It is not clear if this thrombosis is secondary to disruption of vessel wall integrity by the underlying atherosclerotic lesion, or if perhaps antiphospholipids are pathogenetically involved. The contribution of prednisone therapy to these lesions is also controversial.

All of the above mechanisms could have a role either singly or in combination in causing a similar noninflammatory vasculopathy in the brain. It seems unlikely that this type of lesion explains the CNS disease in our patient. She appeared to have only large vessel disease by MRI and the duration of SLE was most likely too short to allow this type of lesion to develop.

Lastly, cerebral hemorrhage, both subarachnoid and intracranial, has been reported to occur with increased frequency in SLE compared to the general population. The incidence ranges from 0.4–7%.<sup>19</sup> Likely predisposing factors are hypertension and thrombocytopenia. Additionally, for unknown reasons, berry aneurysms are more common in SLE. MRI did not reveal evidence of a hemorrhagic CVA in our patient and she was not hypertensive or thrombocytopenic. Therefore, we do not believe this is the etiology of the CVA in our patient.

Because of the high morbidity and mortality associated with CVAs in SLE, several studies have attempted to identify treatable risk factors in hopes of preventing these events. Futrell *et al.*<sup>3</sup> retrospectively and prospectively compared patients with SLE and CVAs to patients with SLE without CVAs and identified several factors that were associated with a significantly increased risk of a stroke. These included cardiac valvular disease, coagulopathy, previous stroke or TIA and age greater than 60 y. If one of these factors was present, the risk of a CVA was 94%. If both cardiac valvular disease and coagulopathy were present, the risk of a CVA was 100%. Levine and Welch<sup>20</sup> reported that greater than 50% of strokes in SLE associated with a lupus anticoagulant were also associated with either hypertension, hypercholesterolemia, or diabetes mellitus suggesting a multifactorial etiology of strokes in the majority of SLE patients.

Treatment and prevention of strokes in SLE are of paramount importance. Anticoagulation with heparin or warfarin has been successful in preventing recurrent events although they do not correct the underlying fibrinolytic defects.<sup>3</sup> Steroids and cytotoxic agents have been administered although they are more often given to treat accompanying systemic disease. As mentioned previously, their role in preventing further CVAs is questionable especially considering the lack of evidence for an inflammatory etiology in most cases. Steroids in particular have not shown any effect in treatment or prevention of strokes in SLE. Through increases in plasma low density lipoprotein (LDL) levels and aberrant effects on coagulation, namely inhibition of plasminogen activator production, steroids may actually represent a risk factor. Aggressive controls of blood pressure,

blood glucose and blood lipid levels as well as smoking cessation are important adjunctive modifiable risk factors. The role of aspirin in prevention of CVAs in SLE remains unproven. Screening patients for the presence of concomitant circulating anticoagulants and cardiac valvular disease may be prudent considering the 100% incidence of a stroke in this subset of patients. Prophylactic anticoagulation may be warranted in these patients.

## Conclusion

We describe a case of SLE complicated by a CVA. Aggressive treatment for active systemic SLE as well as anticoagulation resulted in a good outcome. The most likely etiology of the CVA in our patient is cerebral infarction secondary to either cardiac emboli or spontaneous thrombosis related to a high level of an IgG antiphospholipid antibody. The long-term prognosis in SLE patients with this type of CVA remains guarded. Further elucidation of the mechanisms leading to strokes in these patients will hopefully lead to appropriate preventive measures as even one of these events can have devastating consequences.

## References

- 1 West SG. Neuropsychiatric lupus. *Rheumatic Disease Clinics of North America* 1994; **20**: 129–159.
- 2 Osler W. On the visceral manifestations of the erythema group of skin diseases. *Trans Assoc Am Physicians* 1903; **18**: 599–624.
- 3 Futrell N, Millikan C. Frequency, etiology and prevention of stroke in patients with systemic lupus erythematosus. *Stroke* 1989; **20**: 583–591.
- 4 Devinsky O, Petito CK, Alonso DR. Clinical and neuropathic findings in SLE: the role of vasculitis, heart emboli and thrombotic thrombocytopenic purpura. *Ann Neurol* 1988; **23**: 380–384.
- 5 Doherty NE, Siegel RJ. Cardiovascular manifestations of systemic lupus erythematosus. *Am Heart J* 1985; **110**: 1257–1265.
- 6 Fox IS, Spence AM, Wheelis RF, Healey CA. Cerebral embolism in Libman–Sacks endocarditis. *Neurology* 1980; **30**: 487–491.
- 7 Asherson RA *et al.* Diagnostic and therapeutic problems in two patients with antiphospholipid antibodies, heart valve lesions and transient ischemic attacks. *Ann Rheum Dis* 1988; **47**: 947–957.
- 8 Young SM *et al.* Cardiogenic brain embolism and lupus anticoagulant. *Ann Neurol* 1989; **26**: 390–392.
- 9 Harris EN *et al.* Cerebral infarction in SLE: association with anticardiolipin antibodies. *Clin Exp Rheumatol* 1984; **2**: 47–51.
- 10 Harris EN *et al.* Lupoid sclerosis: a possible pathogenetic role for antiphospholipid antibodies. *Ann Rheum Dis* 1985; **44**: 281–283.
- 11 Asherson RA, *et al.* Cerebrovascular disease and antiphospholipid antibodies in systemic lupus erythematosus, lupus-like disease and primary antiphospholipid syndrome. *Am J Med* 1986; **86**: 391–399.
- 12 Hughson MD, McCarty GA, Sholer CM, Brumback RA. Thrombotic cerebral arteriopathy in patients with the antiphospholipid syndrome. *Modern Pathology* 1993; **6**: 644–653.
- 13 Johnson RT, Richardson EP. The neurological manifestations of SLE. A clinical-pathological study of 24 cases and review of the literature. *Medicine* 1958; **47**: 337–369.
- 14 Peterson A, Timperley W, Slater D. Coagulation abnormalities in fatal cerebral lupus erythematosus. *J R Soc Med* 1981; **74**: 53–55.
- 15 Ellison D, Gotter K, Heryet A, Esiri M. Intramural platelet deposition in cerebral vasculopathy of systemic lupus erythematosus. *J Clin Pathol* 1993; **46**: 37–40.
- 16 Hang LM, Izui S, Dixon FJ. (NZW × BXSB)F1 hybrid: A model of acute lupus and coronary vascular disease with myocardial infarction. *J Exp Med* 1981; **154**: 216–221.
- 17 Accini L, Dixon FJ. Degenerative vascular disease and myocardial infarction in mice with lupus-like syndrome. *Am J Pathol* 1979; **96**: 477.
- 18 Bidoni AK, Roberts JL, Schwartz MM, Lewis EJ. Immunopathology of cardiac lesions in fatal systemic lupus erythematosus. *Am J Med* 1980; **69**: 849–858.
- 19 Kaell AT *et al.* The diversity of neurologic events in SLE—prospective, clinical and computed tomographic classification of 82 events in 71 patients. *Arch Neurol* 1986; **43**: 273–276.
- 20 Levine SR, Welch KMA. The spectrum of neurologic disease associated with antiphospholipid antibodies: lupus anticoagulants and anticardiolipin antibodies. *Arch Neurol* 1987; **44**: 876–883.