

# Revascularization of cerebral ischemia after previous bilateral extracranial-intracranial bypass procedures

V. S. Sotturrai, MD, PhD, L. Herbert, MD, and D. Hatter, MD, *New Orleans, La.*

Extracranial-intracranial (EC-IC) bypass grafting procedures were specially designed for treatment of bilateral internal carotid artery occlusion. When performed in an expeditious manner, EC-IC bypass procedures have produced effective and durable results, despite the recent disfavor given to this procedure. This communication reports a 68-year-old white man who developed generalized cerebral ischemia manifested as confusion, incoherence, disorientation, ataxia, and numerous episodes of syncope daily. A cerebral angiogram revealed bilateral external carotid arteries and left solitary vertebral artery critical stenosis. Transcranial Doppler study demonstrated reduction of cerebral and vertebral-basilar perfusion. However, the patient's EC-IC bypass graft had remained patent since 1985. The patient's recurrent symptoms of global ischemia and syncope resolved after carotid endarterectomy, vein patch external carotid artery, and vertebral-to-common carotid artery transposition. This report reiterates the value of the EC-IC bypass procedure and presents the surgical management of symptomatic external carotid and vertebral artery stenosis in patients after EC-IC bypass procedures. (*J Vasc Surg* 1997;26:160-3.)

Extracranial-intracranial (EC-IC) bypass grafting procedures were designed by Yasargil<sup>1</sup> and later elaborated by Shields and Donaghy.<sup>2</sup> We describe a patient who has done well after undergoing EC-IC bypass grafting procedures without symptoms of global ischemia from April 1985 to December 1994. He was seen in consultation for daily ataxia, syncope, and progressive development of incoherence, dizziness, and memory impairment. A cerebral angiogram revealed that bilateral external carotid and left solitary vertebral arteries had critical stenosis. Carotid endarterectomy, vein patch angioplasty of the external carotid artery, and vertebral-to-common carotid artery transposition resulted in resolution of these symptoms.

## CASE REPORT

A 68-year-old man who had global cerebral ischemia and daily episodes of syncope showed

>80% bilateral external carotid stenosis on duplex scan. Only 18 to 29 ml/sec of flow was documented in the anterior, middle, and posterior cerebral arteries. The patient did not have cardiac arrhythmia or seizure disorders, whereas the results of electronystagmography was consistent with brain stem ischemia. A cerebral angiogram revealed patent EC-IC bypasses and critical stenosis of bilateral external carotid and solitary left vertebral arteries (Fig. 1).

With the patient under general anesthesia, the common, internal, and external carotid arteries and the vertebral artery were exposed through an oblique incision placed along the anterior border of the sternocleidomastoid muscle. Sympathetic nervous plexus and vertebral ganglion were preserved, and cranial nerves (XII, X, and its associated branches) were protected. The thoracic duct was transected after ligation.

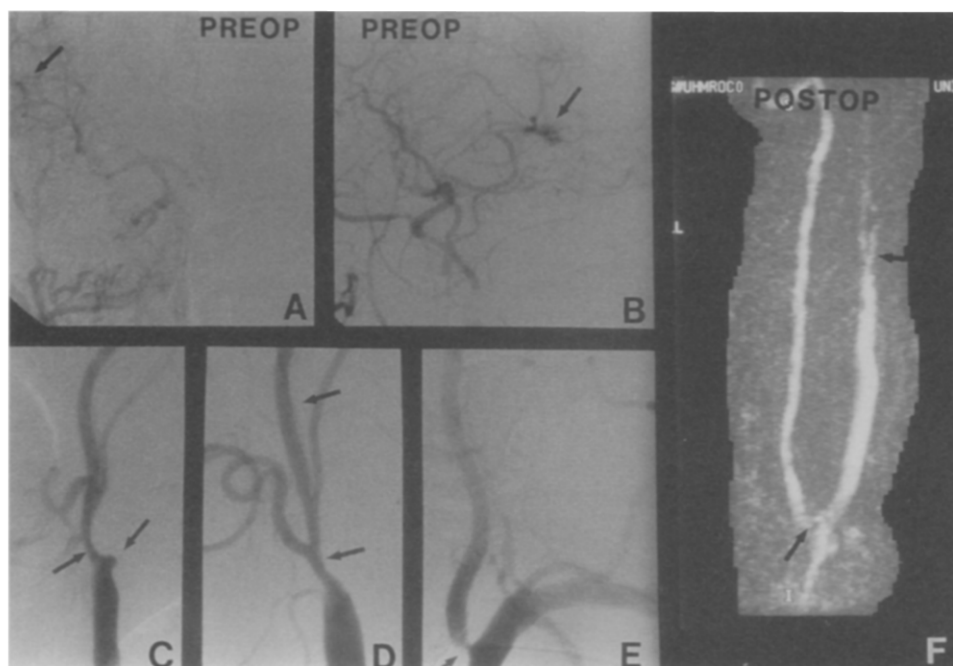After systemic heparin (5000 U) was administered, the common and external carotid arteries were occluded with vascular clamps. A carotid arteriotomy was made, and an Argyle shunt (8F) was placed in the external and common carotid arteries to maintain cerebral blood flow. Ulcerative plaques with necrotic debris were found in the internal carotid cul de sac and in several areas along the common carotid arteries (Fig. 1, C and

From the Department of Surgery, Section of Vascular Surgery, Louisiana State University School of Medicine.

Reprint requests: V. S. Sotturrai, Department of Surgery, Section of Vascular Surgery, Louisiana State University School of Medicine, 1542 Tulane Ave., New Orleans, LA 70112-2822.

Copyright © 1997 by The Society for Vascular Surgery and International Society for Cardiovascular Surgery, North American Chapter.

0741-5214/97/\$5.00 + 0 24/4/78862



**Fig. 1.** Preoperative cerebral angiograms. **A**, Left EC-IC anastomosis at middle cerebral artery (*arrow*). **B**, Right EC-IC anastomosis at middle cerebral artery (*arrow*). **C**, Left external carotid stenosis (*arrow*) at cul de sac of occluded left internal carotid artery (*arrow*). **D**, Stenosis of right external carotid artery (*arrow*). **E**, Critical stenosis of left solitary vertebral artery (*arrow*). **F**, Postoperative magnetic resonance angiogram depicts transposition of vertebral artery to the side of common carotid artery (*lower arrow*). *Upper arrow* indicates branching of external carotid artery.

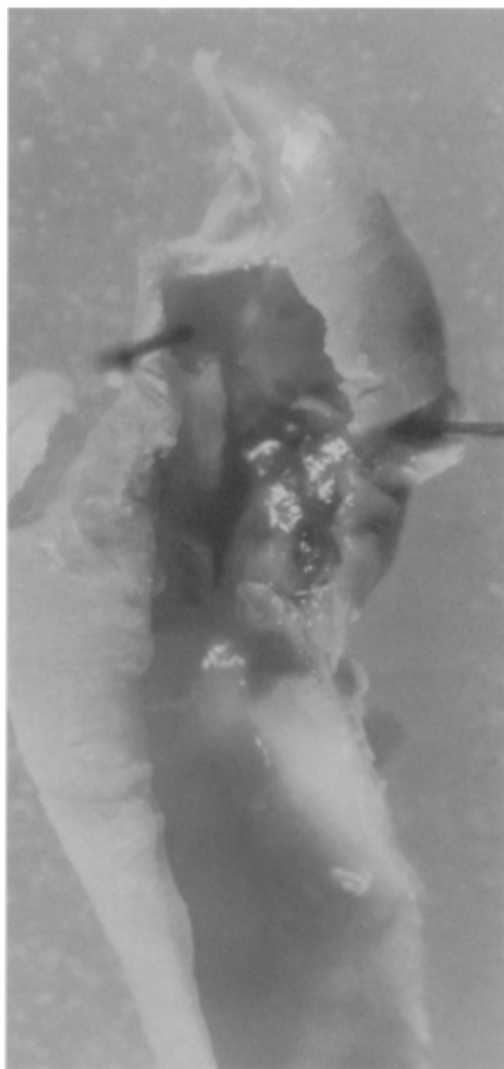
Fig. 2). The common and external carotid arteries were endarterectomized, and the internal carotid cul de sac was resected. The vertebral artery was transected at its origin and was transposed to the endarterectomized common carotid artery after spatulation. Saphenous vein patch angioplasty of the external carotid artery and carotid bifurcation was performed with running 6-0 prolene (Fig. 3). The preoperative global ischemia and syncope resolved after the operation.

## DISCUSSION

EC-IC bypass procedures, when properly performed in an expeditious manner, have produced effective and durable results.<sup>3-6</sup> Despite the recent disfavor given the procedure,<sup>7</sup> new information continues to support certain values of this operation.<sup>8</sup> This patient's case is a good testimony of the procedure. Progression of atherosclerosis remains a threat to the patency and function of the external carotid and vertebral arteries. Therefore, frequent surveil-

lance (every 6 to 12 months) with physical examination is needed. Duplex scan with transcranial Doppler is useful in interrogating cerebral and vertebral ischemic symptoms. Correction of external carotid stenosis and vertebral revascularization should be considered when reduction of territorial arterial perfusion can be established by transcranial Doppler or xenon washout studies. Resolution of global ischemia and vertebrobasilar insufficiency symptoms in this patient is a reflection of improved cerebral and brain stem perfusion. Postoperative transcranial Doppler analysis supported this conclusion (cerebral flow, 28 to 33 ml/sec; vertebral arterial flow, 29 ml/sec). A postoperative magnetic resonance angiogram showed widely patent vertebral-carotid transposition (Fig. 1, F).

Despite the fact that EC-IC bypass is often considered an end-stage procedure, surgical correction of extracranial carotid and vertebral artery stenosis is still indicated when a discrete anatomical lesion can be identified.



**Fig. 2.** Intraoperative specimen demonstrates necrotic thrombi in internal carotid cul de sac.



**Fig. 3.** Intraoperative photograph of long arteriotomy of common carotid artery (*small arrows*). *Open arrows* point to vein patch angioplasty of the external carotid artery. *Solid arrow* points to end-to-side vertebral carotid transposition.

## REFERENCES

1. Yasargil MG. Microsurgery applied to neurosurgery. Stuttgart: Verlag, 1969:95-119.
2. Shields CB, Donaghy RM. Arterial venous grafts for cerebral revascularization. *Surg Forum* 1977;28:463-4.
3. Chater N, Popp J. Microsurgical vascular bypass for occlusive cerebrovascular disease: review of 100 cases. *Surg Neurol* 1976;6:115-8.
4. Yasargil MG, Yonekawa YL. Results of microsurgical extra-intracranial arterial bypass in the treatment of cerebral ischemia. *Neurosurgery* 1977;1:22-4.
5. Reichman OH. Extracranial-intracranial arterial anastomosis. In: Whisnant JP, Sandok BA, editors. *Cerebral vascular diseases*. New York: Grune and Stratton, 1975:175-85.
6. Gratzl O, Schmiedek P, Spetzler R, Steinhoff H, Margurth F. Clinical experience with extra-intracranial arterial anastomoses in 65 cases. *J Neurosurg* 1976;44:313-24.
7. Holohan TV. Extracranial-intracranial bypass to reduce the risk of ischemic stroke. *Can Med Assoc J* 1991;144:1457-65.
8. Ishikawa T, Houkin K, Abe H, Isobe M, Kamiyama H. Cerebral hemodynamics and long-term prognosis after extracranial-intracranial bypass surgery. *J Neurol Neurosurg Psychiatry* 1995;59:625-8.

Submitted Oct. 21, 1996; accepted Oct. 27, 1996.