

STEREOTACTIC TRANSSYLVIAN, TRANSINSULAR APPROACH FOR DEEP-SEATED LESIONS

Dan S. Heffez, M.D., F.R.C.S.

The Chicago Institute of Neurosurgery and Neuroresearch, Chicago, Illinois

Heffez DS. Stereotactic transsylvian, transinsular approach for deep-seated lesions. *Surg Neurol* 1997;48:113-24.

BACKGROUND

Lesions located deep within the frontal and parietal lobes adjacent to the internal capsule are often considered surgically inaccessible. We have used intraoperative stereotactic lesion localization in conjunction with microsurgical dissection of the lateral sylvian fissure to accurately and atraumatically approach such lesions through the insular cortex.

METHODS

When possible, the sylvian fissure is widely opened using standard microsurgical technique. However, exploration through a precisely placed exposure no more than 1.0 cm in length is still feasible. Repeated intraoperative lesion localization employing ultrasound, frame-based or frameless stereotaxis was used to guide dissection deep to the insular cortex.

RESULTS

Using this approach we have resected five cavernous angiomas, three plexiform AVMs and 2 low-grade gliomas. There was a single case of transient dysphasia in seven dominant hemisphere explorations and a single case of transient somatosensory impairment. Otherwise, there were no new transient or permanent postoperative neurologic deficits. In two cases, hemiparesis present prior to surgery improved following resection of a cavernous angioma.

CONCLUSIONS

The transsylvian, transinsular approach can be employed to safely expose lesions deep within the cerebral hemisphere. Anatomic considerations, surgical technical refinements, and clinical results are the subject of this report. © 1997 by Elsevier Science Inc.

KEY WORDS

Stereotactic, transinsular, microsurgery, vascular malformation.

Many lesions would lend themselves to surgical resection were it not for their location deep within the brain. Under such circumstances, the surgical approach to the lesion can result in unacceptable neurologic deficit. This is certainly the case with cavernous angiomas located in the brain stem. A small lesion that does not present near the surface of the brain stem is generally considered inoperable, while a very large lesion that does reach some pial or ependymal surface can be resected, often without inducing any new neurologic deficit [4]. A similar situation exists for lesions located deep within the frontal and parietal lobes and adjacent to the internal capsule. Extensive dissection of normal brain required to expose these lesions may induce unacceptable neurologic deficits. A review of functional neuroanatomy reveals that the insula and subinsular nuclei and white matter tracts lateral to the internal capsule can be disrupted without inducing disabling neurologic deficit [8,9, 11]. Refinements in stereotactically guided surgery and, in particular, image-guided surgery have increased the ease, safety, and accuracy of microsurgical exposure of lesions not visible on the surface of the brain [1]. Therefore, we determined whether deep frontoparietal lesions could be safely resected via a transsylvian, transinsular approach. Dissecting the lateral sylvian fissure renders these lesions more superficial and allows the surgeon to reach the surface of the insula without damaging frontal, temporal, and parietal cortex. Combining the subarachnoid dissection with precise intraoperative lesion localization can facilitate the exposure and resection of lesions deep to the insular cortex with limited disruption of insular and subinsular structures. Our initial experience with 10 cases using a stereotactically guided transsylvian, transinsular approach is the subject of this report.

Address reprint requests to: Dan S. Heffez M.D., F.R.C.S., Director of Cerebrovascular Surgery, The Chicago Institute of Neurosurgery and Neuroresearch, 2515 N. Clark St., Chicago, Illinois 60614.

Received February 26, 1996; accepted September 6, 1996.

1 Anatomy relevant to the transsylvian, transinsular approach

STRUCTURE	FUNCTION
Frontal operculum (motor cortex and premotor cortex)	Voluntary movements of face, tongue, larynx, and pharynx
Parietal operculum (sensory cortex and inferior parietal lobule)	Cortical sensation of face, tongue, larynx, and pharynx and sensory association cortex. Language function (angular gyrus) in the dominant hemisphere.
Temporal operculum (superior temporal gyrus)	Brodman area 22 (Wernicke's area) integral to comprehension of spoken and occasionally written word. Brodmann's areas 41 and 42 (Hesch's gyri) are receptive and associative auditory cortex, respectively
Superficial sylvian veins	Contribute to venous drainage of lateral aspect of hemisphere
Middle cerebral artery (M2 and cortical branches)	Overlying insular cortex and within circular cistern. Arterial supply to the lateral cerebral hemisphere.
Insular cortex-1	Intraabdominal sensation represented in pre-central short insular gyri and tongue, throat, and buccal sensation represented in single long postcentral gyrus. Changes in gastric motility associated with stimulation of precentral gyri.
Extreme capsule-2	Associative system interconnecting frontal, insular, and temporal cortex. Transmits fibers interconnecting parietal and temporal lobes
Clastrum-3	Function unknown
External capsule-4	Cortical projection system transmitting fibers from area 4 and supplemental motor area to midbrain tegmentum
Putamen and globus pallidus-5	Extrapyramidal nuclei having no definite motor function independent of cortical action.
Anterior limb internal-6 capsule	Frontopontine projections and anterior thalamofrontal projections.
Posterior limb of internal-7 capsule	Frontobulbar projections to cranial nerve motor nuclei, corticospinal fibers, and corticorubral fibers. Thalamoparietal somatosensory projections within the retrolenticular portion of posterior limb.

SURGICAL ANATOMY

The area that can be explored through the transsylvian, transinsular trajectory is bounded laterally by the sylvian fissure and insular cortex, medially by the genu of the internal capsule, and anteriorly and posteriorly by the anterior and posterior limbs of the internal capsule, respectively. The risk of inducing a neurologic deficit is largely related to the neuroanatomic structures encountered and potentially disrupted during dissection. The superficial and deep structures at risk, and their respective functions, are listed in Table 1 and shown in Figure 1.

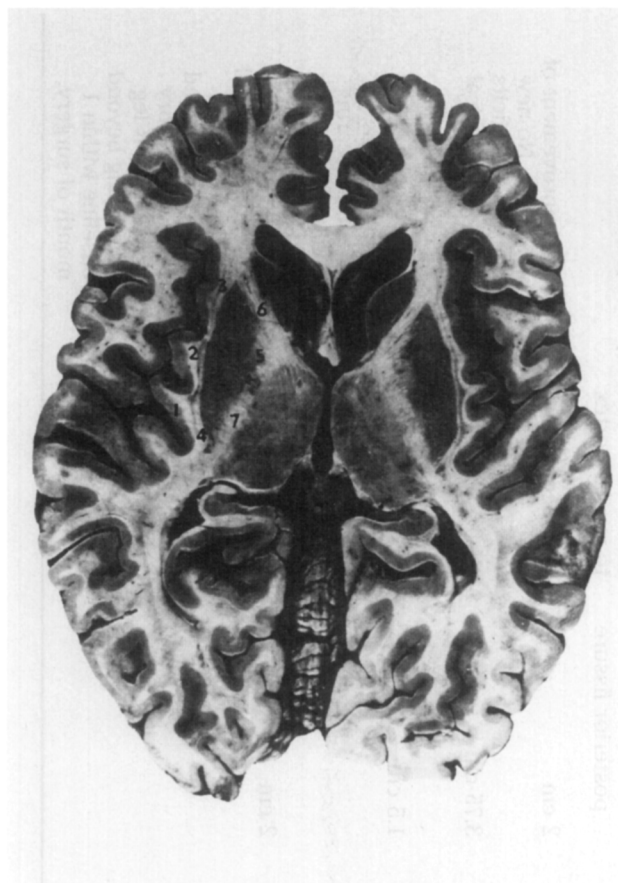
CLINICAL CASE MATERIAL

Between 1990 and 1994, ten patients harboring cavernous malformation [5], plexiform AVM [3], or low-grade glioma [2] were operated on via a transsylvian, transinsular approach. There were six males and four females. The mean age of the patients was 38 years. All patients were symptomatic from their lesions. Magnetic resonance imaging (MRI) was used in all cases to assess the applicability of the

transinsular approach. Cerebral arteriography was used only in cases of suspected plexiform AVM. Preoperative symptoms are outlined in Table 2.

THE USE OF MRI

The anatomy of the sylvian fissure is best demonstrated by MRI (Figures 2A, 2B, 3A, 3B). Our standard MRI technique utilizes 6-mm slice thickness with 1.5-mm gap between slices. T₁-weighted images are obtained in the sagittal, axial, and coronal planes and T₂-weighted images in the axial and coronal planes. The definition of the sylvian fissure is most easily appreciated in the coronal plane on T₂-weighted images. A cerebrospinal fluid (CSF) signal separating the frontal, parietal, and temporal opercula was taken to imply that pial banks were not adherent to one another and that atraumatic dissection of the fissure to expose the insula would be feasible. The T₁-weighted axial image is used to determine the relationship of the lesion in the anteroposterior plane and to the internal capsule. If ultrasound is the only localizing technique to be



1 Axial section of the brain at the level of the foramen of Monro showing the structures encountered deep to the insular cortex. The numbered structures correspond to the structures of same number listed in Table 1.

used, careful preoperative planning of the craniotomy based on the MRI scan is necessary to ensure adequate exposure of the sylvian fissure.

If frameless stereotaxis is to be employed, then the MRI scanning technique involves 3-mm thick, contiguous, interlaced sections in the axial and coronal planes in both the T_1 and T_2 sequences. A three-dimensional model of the brain and the pathology are then reconstructed in the standard manner using an Allegro work station (ISG Technologies, Mississauga, Ontario, Canada), for use in the operating room to optimally localize the craniotomy [4]. MRI-compatible fiducial markers may be applied to the skin prior to scanning to facilitate intraoperative registration and validation of the accuracy of the Allegro Wand [4]. Alternatively, we have relied on recognizable landmarks, such as the nasion and mastoid tips for the same purpose.

The MRI signal characteristics of the lesion are also helpful to determine the likely pathology (e.g., cavernoma, glioma, metastasis, AVM) and, hence,

the advisability of the transsylvian, transinsular approach.

TECHNIQUE OF INTRAOPERATIVE LESION LOCALIZATION

Three techniques of lesion localization have been employed—B-mode ultrasound using a Dasonics model SV200 (Dasonics Inc., Palatine Ill), frame-based stereotaxis using a CRW system (Radionics Inc., Burlington, Mass) and frameless stereotaxis using an ISG Allegro Wand (ISG, Mississauga, Ontario, Canada). The relative advantages and disadvantages of the three techniques are summarized in Table 3. Ultrasound may be used in conjunction with either frame-based or frameless stereotaxis to gauge the extent of surgical resection if required. Regardless of the localizing technique utilized, repeated intraoperative lesion localization is necessary to confirm the accuracy of the trajectory. Once one actually encounters the pathology, resection is guided by direct vision.

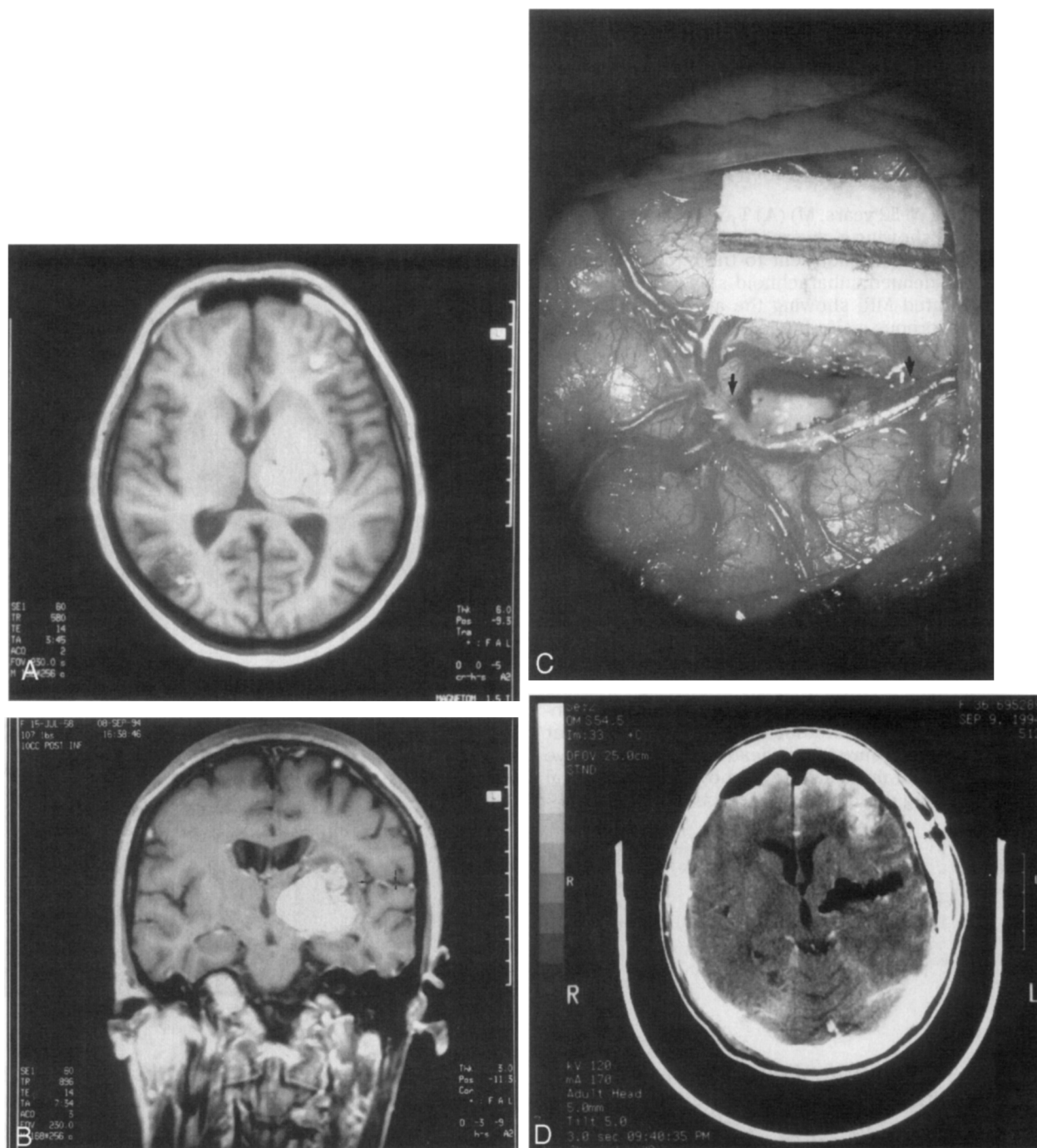
SURGICAL TECHNIQUE

The patient is positioned lateral decubitus with the relevant sylvian fissure oriented parallel to the floor. The scalp incision consists of an inverted U that is based inferiorly and extends superiorly to the superior temporal line. When ultrasonography is used as the sole localizing technique, the anteroposterior location of the scalp incision is determined from the preoperative MRI. When either frameless or frame-based stereotaxis is used, the incision can be centered more precisely over the lesion and the exposure can be more limited. If frame-based CRW stereotaxis is used, the CRW base ring is applied rotated 90 degrees from the usual anteroposterior orientation, so that anterior corresponds to the lateral surface of the hemisphere being explored. The trajectory to the target through the sylvian fissure is determined using the phantom base ring. The arc system is then transferred to the base ring attached to the patient's head and used at various stages of the exposure to confirm the accuracy of the dissection [1]. When frameless stereotaxis is used, a registration of the position of scalp markers (applied prior to preoperative MRI) or of fixed surface landmarks, such as the tragus of the ear, the mastoid process, the nasion, and the medial and lateral orbital rims, must be performed. The accuracy of this registration is then confirmed

2 Summary of Clinical Cases

PATIENT	PATHOLOGY	PREOPERATIVE SYMPTOMS	US	CRW	ALLEGRO WAND	LENGTH OF SYLVIAN DISSECTION		DEPTH OF LESION	POSTOPERATIVE SYMPTOMS
TW, 39 y, F	Cavernoma genu R internal capsule	Mild-moderate left hemiparesis and hemisensory loss due to six hemorrhages	No	Yes	No	1.25 cm		2 cm deep to insular cortex	Improvement of hemisensory loss
GM, 30 y, M	Oligo/astro R frontoparietal	Seizures	Yes	No	No	4 cm		Extends to and involves the insular cortex	Continued seizures
GH, 51 y, M	Small AVM L parietal lobe	Mild R hemisensory and moderate R hemiparesis due to three bleeds	Yes	No	No	Extensive		Hematoma 1.5 cm deep to insular cortex. AVM in medial wall of hematoma.	No new deficits; unable to approach lesion because of adhesions within Sylvian fissure; lesion also too posterior and superior
SW, 21 y, F	Cavernoma L frontoparietal	Mild R hemiparesis and hemisensory loss due to three bleeds	Yes	No	No	1.5 cm		0.5 cm deep to insular cortex	Resolution of symptoms
GP, 17 y, M	Cystic glioma R frontal	Seizures	Yes	No	No	1 cm		1 cm deep to insula	No postoperative deficits. Seizures persist.
RB, 43 y, M	AVM R frontal	Severe L hemiparesis due to intracerebral bleed	No	No	Yes	From limen to posterior fissure		Hematoma 1.5 cm deep to insular cortex	Improved
TW, 52 y, M	Cavernoma L frontal	Moderately severe R spastic hemiparesis	No	No	Yes	2 cm		1.3 cm deep to insula	Some improvement of spasticity. No new neurologic deficits
AE, 37 y, M	AVM L frontal	Seizures, mild word finding difficulty	Yes	No	Yes	3.75 cm		AVM 0.5 cm deep to insula. Extensive deep hematoma	No new neurological deficits
CH, 54 y, F	Cavernoma L parietal-operculum	Seizures, sensory and speech arrest	Yes	No	Yes	1.5 cm		1 mm below junction of angular gyrus, insula, and parietal operculum	Transient worsened dysphasia due to seizures, clearing completely 1 week postop
RB, 36 y, F	Multiple cavernomas. Active deep L frontoparietal lesion	Bleed, R hemiparesis A>>L>F, mild dysphasia, somatosensory impairment A>>L.	No	No	Yes	2 cm		5 mm below insular cortex extending to and involving lateral aspect posterior limb internal capsule	Improved language function. Increased weakness R arm, recovering beyond baseline. Sensory impairment R leg, recovering beyond baseline within 1 month of surgery.

AVM, arteriovenous malformation; A, arm; F, face.

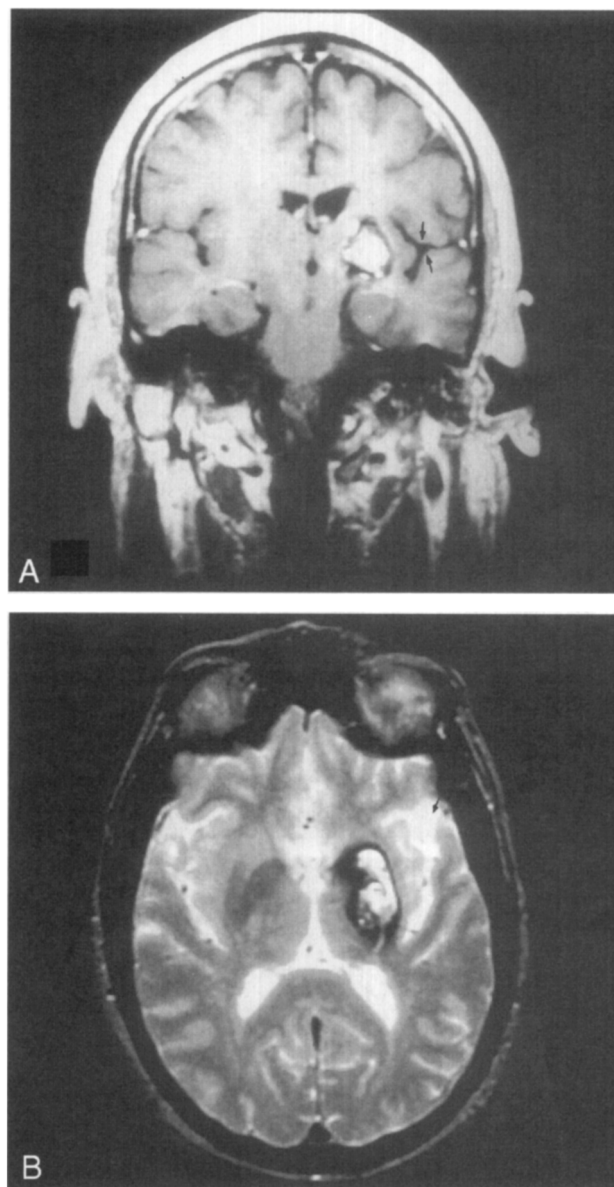


2 (RB, 36 years, F) (A) T₁-weighted MRI, axial view showing a large cavernous hemangioma deep to the insular cortex and involving the thalamus and posterior limb of the internal capsule. The patient harbored multiple cavernous malformations. (B) T₁-weighted, gadolinium-enhanced coronal MRI showing the large cavernous malformation. The sylvian fissure is defined by the cerebrospinal fluid signal separating the frontal and temporal opercula (arrows). (C) Operative photograph taken after resection of the cavernous malformation and showing the extent of the superficial sylvian dissection (arrows). The cottonoid marker is 2 cm in length. (D) Computed tomography (CT) scan of the brain, axial image, confirming complete resection of the cavernous malformation.

by demonstrating the correspondence between a point of contact on the scalp and the same point on the corresponding MRI in the computer's data base [4]. Thereafter, as long as the patient's head re-

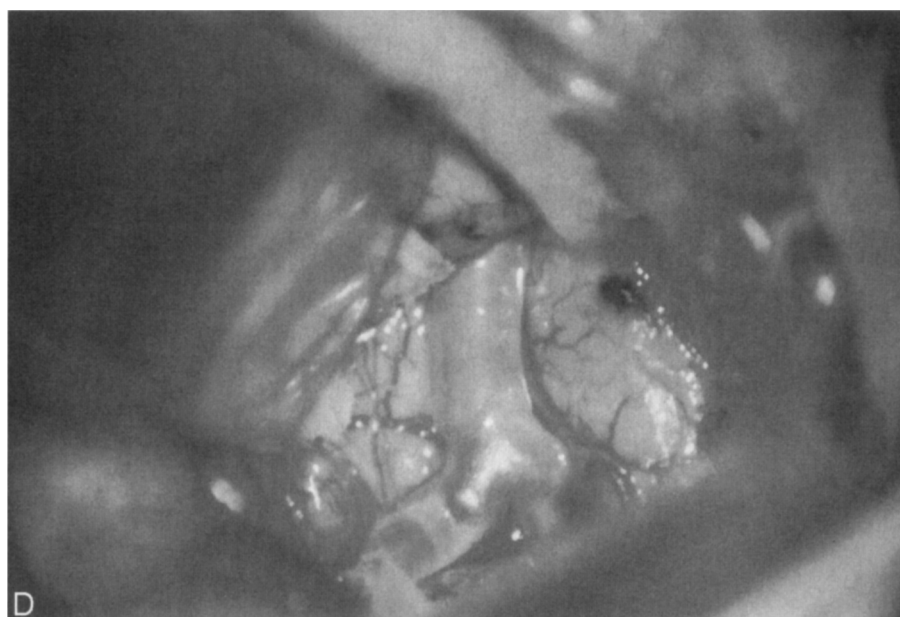
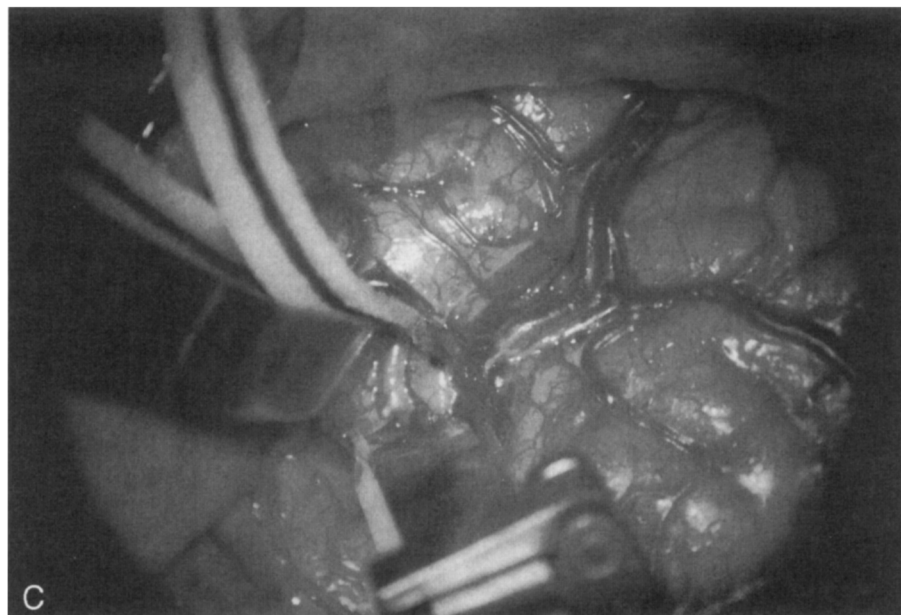
mains rigidly immobilized, the Wand can be used to localize the scalp incision and guide the microdissection of the sylvian fissure using MRI viewed on the computer monitor in the operating room for

3 (Patient TW, 52 years, M) (A) T₁-weighted MRI, coronal view, showing a cavernous angioma deep to the left insular cortex and adjacent to the internal capsule. Note the well-defined subarachnoid space (arrows). (B) Axial T₂-weighted MRI showing the anteroposterior extent of the cavernous malformation. Note the well-defined sylvian fissure filled with cerebrospinal fluid (arrow). (C) Intraoperative photograph showing the extent of sylvian fissure dissection. At the depth of the exposure, a branch of the middle cerebral artery can be seen overlying the insular cortex. The retractor blades are 0.64 cm in width. (D) Intraoperative photograph, high-power view, showing the large middle cerebral artery branches overlying the insular cortex. (E) Localization of the cavernous angioma using the Allegro Wand. The intersecting white lines coincide with the position of the tip of the computer-linked probe used to guide the surgical trajectory. The tip of the Wand appears to be in the center of the cavernous malformation as seen on the T₁-weighted MRI. In fact, the Wand tip is at the periphery of the lesion, illustrating the inaccuracy related to the settling of the brain with drainage of spinal fluid. (F) Intraoperative photograph showing the cavernous angioma at the depth of the surgical exposure. The tip of a 5 French Rhoton suction can be seen at the edge of the exposure (arrowhead). (G) Postoperative CT scan of the brain, axial view, showing the surgical trajectory leading directly to the resection cavity.



reference. Once the location of the incision has been determined, a conventional craniotomy is performed. The dural opening is U shaped and based inferiorly. The lateral sylvian fissure is recognized from the orientation of the superficial sylvian veins, and from the middle cerebral artery branches coursing over the frontal, parietal, and temporal opercula. The optimal trajectory through the sylvian fissure is selected based on ultrasonic or stereotactic localization of the lesion and the surface venous anatomy, which will determine access to the sylvian fissure. The sylvian fissure is dissected under high-power magnification using the operating microscope and standard microsurgical technique. The length of the superficial sylvian dissection is determined by the anteroposterior extent of the

lesion and the ease with which the pial banks can be separated. Exploration deep within the hemisphere has been accomplished through a superficial sylvian dissection as limited as 1.0 cm in length and can be comfortably accomplished through a 2-cm dissection. The subarachnoid dissection is carried down to the insular cortex, which is recognized by the orientation of the gyri somewhat perpendicular to the plane of dissection. Rostral short and caudal long gyri are separated by a central sulcus and oriented somewhat perpendicular to the long axis of the lateral sylvian fissure [8,9]. The sylvian branches of the middle cerebral artery are usually encountered at this point. No arteries or veins are sacrificed. A retractor blade can be applied to the superior and inferior pial banks to maintain expo-

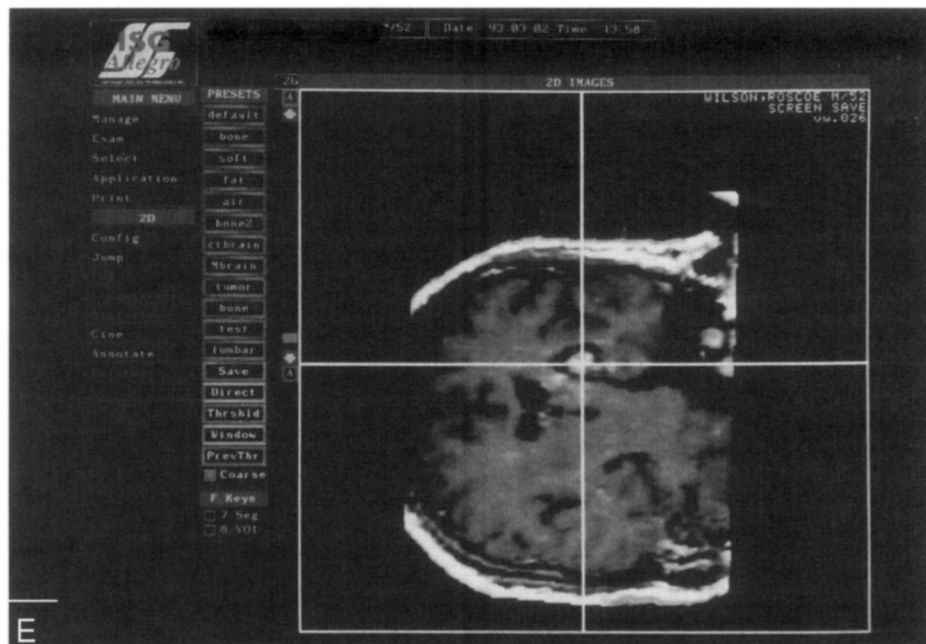
**3** Continued.

sure. Care must be taken to ensure a perpendicular orientation of the retractor blades to avoid contusing the opercula. This is particularly important with a more limited superficial sylvian dissection. The optimal site for insular corticotomy is determined stereotactically or by the use of ultrasound. Subcortical dissection then proceeds using microsuction and bipolar coagulation until the lesion is encountered. Repeated confirmation of the trajectory through the brain is required until the pathology is visualized. The lesion is then removed using techniques appropriate for the specific pathology encountered. Somatosensory-evoked potentials have been monitored routinely in these cases, primarily

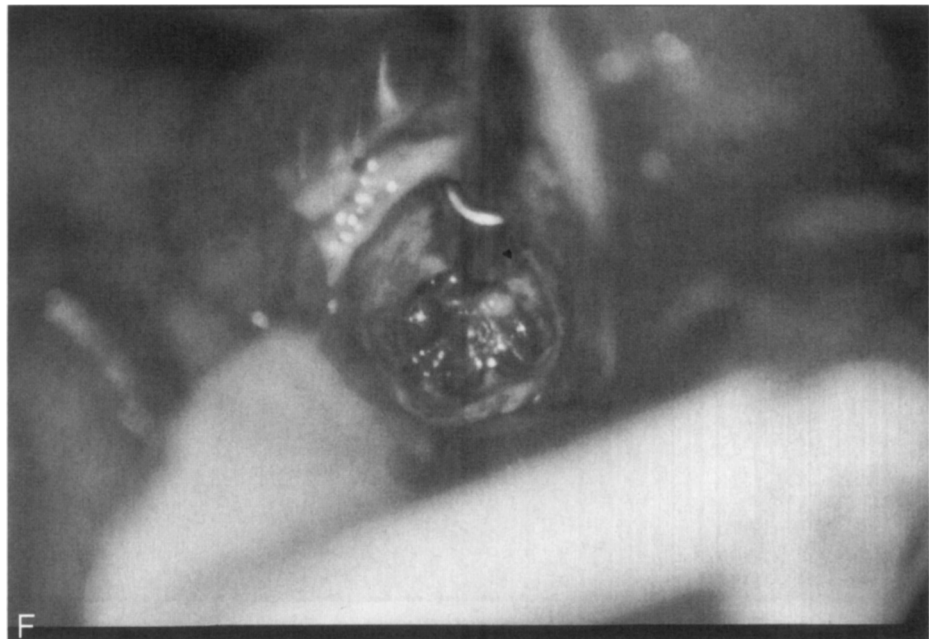to detect ischemia that may potentially result from retractor compression of middle cerebral artery branches. Closure proceeds according to standard neurosurgical technique.

CLINICAL RESULTS

The stereotactic transsylvian, transinsular approach was used in 10 cases (5 cases of cavernous malformation, 3 cases of plexiform AVMs, 1 case of solid low-grade mixed glioma, and 1 case of low-grade cystic astrocytoma). The clinical results including preoperative and postoperative neurologic

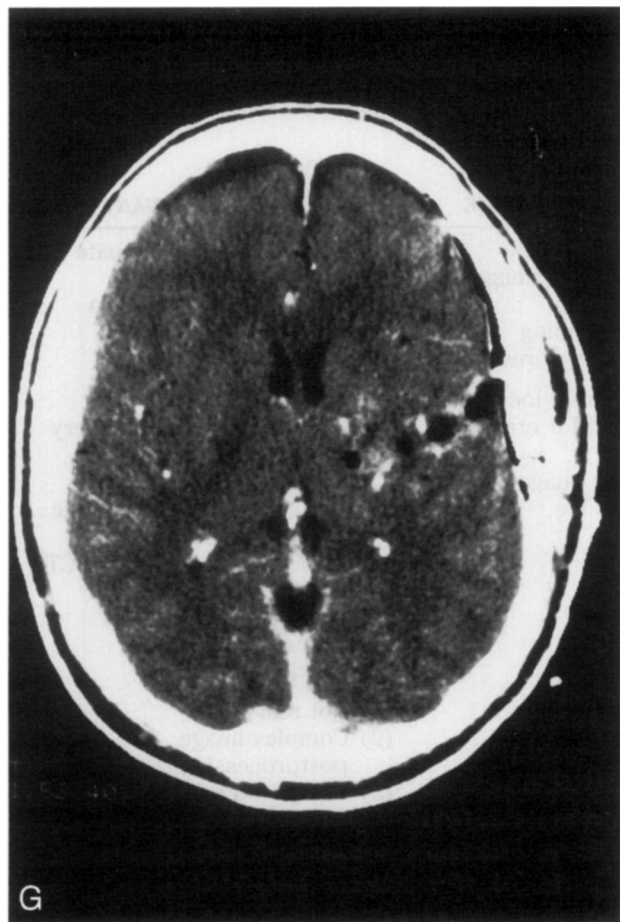


3 Continued.



findings, the length of the sylvian fissure dissection, and the depth of the lesion beneath the insular cortex are summarized in Table 2. Seven dominant and three nondominant hemispheres were explored. In six of seven dominant hemisphere explorations, language function was in no way worsened by surgery. One patient who underwent resection of a cavernous malformation 4.25 cm in maximum diameter reported improved word-finding ability following surgery (Figure 2). Another patient who underwent resection of a cavernous malformation immediately deep to the dominant angular gyrus

experienced worsened seizures characterized by word-finding difficulties. Her interictal language function was normal. Seizures were well controlled prior to discharge from the hospital on the seventh postoperative day. One patient with a spastic right hemiparesis awoke from surgery with a worsened somatosensory deficit in the right leg. A persistent change in the somatosensory-evoked potential was noted during surgery, but no change was made in the surgical technique, other than an adjustment of the retractors. The clinical deficit improved steadily following surgery and, within 1 month,



3 Continued.

both motor and sensory function exceeded the preoperative baseline. Two patients harboring cavernous malformations reported improvement in motor function immediately after surgery; one patient had a mild right hemiparesis that resolved completely; and the other patient with a long-standing spastic right hemiparesis reported diminished spasticity (Figure 3). One exploration in which only ultrasound was used for intraoperative guidance was unsuccessful because the sylvian fissure resisted extensive dissection and because the lesion, a plexiform AVM, was positioned too posteriorly and superiorly to be resected through a limited exposure. Even in this case, there were no postoperative deficits, despite the difficult dissection. This AVM was eventually removed through a stereotactically guided transcortical, superior, parietal, lobule approach. Thus far, there has been no case of a new postoperative seizure disorder related to the insular corticotomy. The lesions were always encountered at a depth several millimeters greater than

anticipated by either frame-based or frameless stereotaxis, but not when real time ultrasound was used. This has been attributed to the visible settling of the brain with drainage of spinal fluid. As the patients were all positioned lateral decubitus, no displacement in the anteroposterior plane was noted.

DISCUSSION

The transsylvian, transinsular approach was first described by Suzuki and Sato who used it to facilitate the needle aspiration of hypertensive intracerebral hematoma [12]. The initial experience was limited to patients with hemiplegia and with a depressed level of consciousness. While the patients were already severely impaired, the authors did not feel that additional neurologic deficit was provoked by the transinsular approach. Yaşargil has described the transsylvian, transinsular route through a pterional craniotomy for the resection of striocapsulothalamic AVMs, although he questioned the adequacy of this approach for safe resection [16]. From his experience with a series of 23 insular AVMs approached through the sylvian fissure, Yaşargil did not note any deficit related to the insular dissection [15]. U utilized this approach to expose the lateral portion of deep AVMs, which he resected in multiple stages; but he abandoned it because of difficulty controlling deep bleeding [13]. Roper et al used the transsylvian approach for the resection of glioma of the nondominant insula. Good results were obtained in two of two cases [10]. Bertalanffy et al explored 10 deep hemispherical cavernous malformations through the transsylvian approach to the insular surface via a pterional craniotomy. Six lesions were located in the insula, three in the basal ganglia, and one in the posterior limb of the internal capsule. New severe postoperative neurologic deficits were noted in 7 of 10 patients. These deficits were attributed to manipulation of the lenticulostriate arteries and to overly aggressive resection of hemosiderin-stained brain tissue. Of note, the patient with the cavernoma in the internal capsule did well [2].

We have modified the transinsular approach in three ways:

- (1) by relying on some form of stereotactic intraoperative localization, the sylvian fissure dissection and insular corticotomy can be more precisely tailored. Image guidance was used to limit the extent of disruption of subinsular structures, as most lesions to be explored are not evident on the insular surface.

3 Localizing Techniques

LOCALIZING TECHNIQUE	PRIMARY LOCALIZING TECHNIQUE (NUMBER OF CASES)	SECONDARY LOCALIZING TECHNIQUE (NUMBER OF CASES)	RELATIVE ADVANTAGE	RELATIVE DISADVANTAGE
Ultrasound	4	2	(1) Real time (2) Avoids complex image postprocessing (3) Aids in confirming completeness of resection	(1) Resolution is inadequate for small lesions (2) Cannot be used to plan craniotomy
CRW Stereotaxis	1	0	(1) Highly accurate localization (2) Can be used for craniotomy planning (3) No complex image postprocessing	(1) Not real time (2) Brain shifts during surgery can result in inaccurate localization (3) Expertise with stereotactic device required (4) Immediate preoperative CT scanning required (5) Headframe in place throughout surgery (6) No visual feedback
ISG Allegro Wand	5	0	(1) Non encumbering (2) Useful for planning craniotomy (3) Intraoperative reference to 3-D and triplanar CT and MRI images (4) Intraoperative use not restricted by stereotactic coordinates (5) User friendly (6) Imaging and postprocessing can be done days earlier	(1) Not real time (2) Complex image postprocessing required (3) Preoperative fiducial registration can be time consuming (4) Brain shifts during dissection can lead to inaccurate localization (5) Skull movement during craniotomy results in 1-2-mm shift, reducing usefulness for small lesions

- (2) we have demonstrated that large, deep lesions can be safely removed through limited sylvian fissure dissections if the exposure is precisely localized overlying the lesion. While extensive dissection of the sylvian fissure can facilitate deeper intraparenchymal dissection by maximizing exposure, it is time consuming, subjects more frontal, parietal, and temporal cortex to the risk of surgically induced trauma, and is not always possible if pial banks are adherent to one another. Successful surgery has been possible through sylvian dissections as limited as 1.0 cm. in length.
- (3) To minimize the problem of intraoperative anatomic shifts, which can degrade the accuracy of both frame-based and frameless stereotaxis, we have positioned the patients lateral decubitus. In this position, anatomic shifts appear to

have been limited to dependent settling of the brain due to drainage of CSF. As a result, while lesions have been encountered at a greater depth than predicted, we have not been misled in the anteroposterior plane even when dealing with small, deep lesions. Furthermore, a laterally placed craniotomy exposes the entire lateral sylvian fissure, which is essential if a limited sylvian dissection positioned precisely overlying the lesion is to be used or if an alternate trajectory is required because of the adherence of the opercula to one another.

Insulectomy in the course of seizure surgery has not been associated with demonstrable neurologic deficit and, in particular, dysphasia [9,10], although the early literature documents a 20% incidence of retraction hemiparesis/hemiplegia with extensive

insular resection [11]. Penfield reported visceral sensory, visceral motor and somatic sensory responses to insular stimulation in awake patients [9]. While the insular corticotomy that we employed was limited in extent, we selected the site for corticotomy exclusively on anatomic basis without relying on functional mapping. Nevertheless, our patients did not report any new long-standing sensorimotor or language dysfunction following their surgery. The extreme capsule, an associative pathway, and the external capsule, a corticofugal pathway, can be dissected without ill effect in our experience. Although the globus pallidus and putamen comprise part of the basal ganglia of the extrapyramidal motor system, their unilateral disruption in the absence of damage to the motor cortex or internal capsule reportedly does not result in any demonstrable motor dysfunction [3,7]. Lesions within or medial to the genu and posterior limb of the internal capsule which transmit frontobulbar and corticospinal and thalamocortical sensory projections, respectively, would not be resectable through this approach without the risk of causing a significant contralateral motor/sensory deficit. In the face of an existing relevant neurologic deficit, the transinsular approach would remain an option. The function of the anterior limb of the internal capsule is less eloquent; infarctions of this structure have been associated with ataxic hemiparesis and with the dysarthria-clumsy hand syndrome [6]. We would not approach lesions of the head of the caudate nucleus, which lies medial to the anterior limb of the internal capsule, through the transsylvian, transinsular route.

Somatosensory-evoked potentials have been monitored in all cases. In a single case, an intraoperative deterioration in the recorded cortical signal did correlate with a transient postoperative cortical sensory deficit. While this finding was informative, it did not alter our surgical technique. In the remaining nine cases, no deterioration in the somatosensory-evoked potential was noted. Somatosensory-evoked potential monitoring may be most helpful when exploring lesions adjacent to the posterior limb of the internal capsule.

The nature of the pathology encountered determines the feasibility of safe resection. Discrete lesions, which displace rather than infiltrate normal brain tissue, should be most amenable to transinsular resection through a limited exposure, as most of the surgical manipulation will take place within the pathology. Cavernous malformations in particular lend themselves to removal through this limited approach because of their circumscribed nature, their clear demarcation from normal adjacent

brain tissue by a tough gliotic plane, and the possibility of removing them piecemeal without provoking unmanageable bleeding [14]. Low-grade gliomas, which may be cystic or solid and appear well demarcated from normal brain on MRI, would also be amenable to this approach. The true plexiform AVMs that we have explored through the transinsular approach had all previously hemorrhaged. The existing hematoma cavity greatly increased the deep exposure, facilitating resection. Otherwise, the exploration of any but a small AVM through a limited exposure would carry the risk of incomplete resection and postoperative hemorrhage. Metastatic tumors, which are characteristically well circumscribed, might also be amenable to resection via the transinsular approach if surgery were indicated and if cerebral edema were not so severe as to prevent safe dissection of the sylvian fissure.

In summary, the transsylvian, transinsular approach can be used to resect deep intraparenchymal lesions without inducing permanent neurologic deficit. We have refined this approach by relying on precise intraoperative lesion localization, which permits exploration through a limited exposure and by using a lateral, rather than a pterional, craniotomy—which appears to limit anatomic shifts, an absolute requirement of image-guided surgery. Even large lesions can be safely resected in this manner through a sylvian dissection no more than 1–1.25 cm in length. Further experience with this technique is required in order to expand its application.

REFERENCES

1. Apuzzo MLJ, Chandrasoma PT, Breeze RE, Cohen DM, Luxton G, Mazumder A. Applications of image-directed stereotactic surgery in the management of intracranial neoplasms. In: Stereotactic neurosurgery Heilbrun MP, ed., Baltimore: Williams and Wilkins, 1988:73–132.
2. Bertalanffy H, Gilsbach JM, Eggert HR, Seeger W. Microsurgery of deep seated cavernous angiomas: report of 26 cases. *Acta Neurochir (Wien)* 1991;108: 91–9.
3. Brodal A. Neurological anatomy in relation to clinical medicine. New York: Oxford University Press, 1981: 282–6.
4. Drake JM, Rutka JT, Hoffman HJ. ISG viewing wand system. *Neurosurgery* 1994;34:1094–7.
5. Heffez DS, Zinreich SJ, Long DM. Surgical resection of intrinsic brainstem lesions: an overview. *Neurosurgery* 1990;27:789–98.
6. Mohr JP. Lacunes. In: Stroke, pathophysiology, diagnosis and management. Barnett HJM, Mohr JP, Stein BM, Yatsu FM, eds. New York: Churchill Livingstone, 1992:548.
7. Peele TL. The neuroanatomic basis for clinical neurology, New York: McGraw-Hill, 1977:390–419.

8. Peele TL. The neuroanatomic basis for clinical neurology. New York: McGraw-Hill, 1977:362-3.
9. Penfield W, Falk ME. The insula: further observations on its function. *Brain* 1955;78:445-70.
10. Roper SN, Levesque F, Sutherling WW, and Engel J. Surgical treatment of partial epilepsy arising from the insular cortex. *J Neurosurg* 1993;79:266-9.
11. Silfvenius H, Gloor P, Rasmussen T. Evaluation of insular ablation in surgical treatment of temporal lobe epilepsy. *Epilepsia* 1964;5:307-320.
12. Suzuki J, Sato S. The new transinsular approach to the hypertensive intracerebral hematoma. *Jpn J Surg* 1972;2:47-52.
13. U HS. Microsurgical excision of paraventricular arteriovenous malformations. *Neurosurgery* 1985;16:293-303.
14. Voigt K, Yaşargil MG. Cerebral cavernous hemangiomas or cavernomas: incidence, pathology, localization, diagnosis, clinical features and treatment. Review of the literature and report of an unusual case. *Neurochirurgia (Stuttg)* 1976;19:58-68.
15. Yaşargil MG. *Microneurosurgery*. Vol. IIIB, New York: Thieme Medical Publishers, 1988:137-49.
16. Yaşargil MG. *Microneurosurgery*. Vol. IIIB. New York: Thieme Medical Publishers, 1988:210.

COMMENTARY

I do believe preoperative high-resolution stereo-angiography can obviate the need for any stereotactic guidance, by matching the vascular anatomy. It has worked for me for many years.

Also in my experience, the longest possible dissection of the sylvian fissure, always including going anteriorly along the sphenoid ridge, permits the fissure to fall open, essentially eliminating the need for retraction.

Finally, I doubt that I would have operated on the low-grade gliomas, since I believe the diagnosis can be established by the combination of CT, MRI, and angiography. Whether to operate once the diagnosis is known is a matter of personal philosophy. Despite this difference of opinion, this is an excellent review, well worth reading.

Leonard I. Malis, M.D.
Neurosurgeon
New York, New York

PEOPLE ARE THE COMMON DENOMINATOR OF PROGRESS. SO . . . NO IMPROVEMENT IS POSSIBLE WITH UNIMPROVED PEOPLE, AND ADVANCE IS CERTAIN WHEN PEOPLE ARE LIBERATED AND EDUCATED. IT WOULD BE WRONG TO DISMISS THE IMPORTANCE OF ROADS, RAILROADS, POWER PLANTS, MILLS, AND THE OTHER FAMILIAR FURNITURE OF ECONOMIC DEVELOPMENT. . . . BUT WE ARE COMING TO REALIZE . . . THAT THERE IS A CERTAIN STERILITY IN ECONOMIC MONUMENTS THAT STAND ALONE IN A SEA OF ILLITERACY. CONQUEST OF ILLITERACY COMES FIRST.

—JOHN KENNETH GALBRAITH (B. 1908)
"ECONOMIC DEVELOPMENT," 1964