

- leefwijze en sterfte in relatie tot opleiding.) *T Soc Gezondheidsz* 1988;66:345–348.
13. Appels A, Otten F, Mendes de Leon C, Sturmans F, Mulder P, Schuurman J. The KRIS follow-up study VII. Socio-economic status and health. (De KRIS follow-up studie VII. Sociaal-economische status en gezondheid.) *T Soc Gezondheidsz* 1990; 68:298–305.
 14. Folstein MF, Folstein SE, McHugh PR. Mini-mental state: a practical method for grading the cognitive state of patients for the clinician. *J Psychiatr Res* 1975;12:189–198.
 15. Roth M, Huppert FA, Tym E, Mountjoy CQ. CAMDEX. The Cambridge examination for mental disorders of the elderly. Cambridge: Cambridge University Press, 1988.
 16. Katz S, Ford AB, Moskowitz RW, Jackson BA, Jaffe MW. Studies of illness in the aged. The index of ADL: a standardized measure of biological and psychosocial function. *JAMA* 1963;185:914–919.
 17. Lawton PM, Brody EM. Assessment of older people: self-maintaining and instrumental activities of daily living. *Gerontologist* 1969;9:179–186.
 18. McKhann G, Drachman D, Folstein M, Katzman R, Price D, Stadlan EM. Clinical diagnosis of Alzheimer's disease: report of the NINCDS-ADRDA Work Group under the auspices of Department of Health and Human Services Task Force on Alzheimer's disease. *Neurology* 1984;34:939–944.
 19. Kaplan EL, Meier P. Nonparametric estimation from incomplete observations. *J Am Stat Assoc* 1958;53:457–481.
 20. Cox DR. Regression models and life tables. *J R Stat Soc* 1972; 34:187–220.
 21. Manton KG, Poss SS, Wing S. The black/white mortality crossover: investigation from the perspective of the components of aging. *Gerontologist* 1979;19:291–300.
 22. Guralnik JM, Land KC, Blazer D, Fillenbaum GG, Branch LG. Educational status and active life expectancy among older blacks and whites. *N Engl J Med* 1993;329:110–116.

Anterior translocation of language in patients with left cerebral arteriovenous malformation

R.M. Lazar, PhD; R.S. Marshall, MD; J. Pile-Spellman, MD; L. Haccin-Bey, MD; W.L. Young, MD; J.P. Mohr, MD; and B.M. Stein, MD

Article abstract—We studied seven patients with left cerebral arteriovenous malformation (AVM) with superselective arterial injection of anesthetics during angiography to determine whether there was translocation of some language functions to other regions in the ipsilateral hemisphere. All patients were right handed. With a catheter inserted into each target vessel, patients underwent aphasia examination in an A-B-A design: (A) baseline, no anesthetic; (B) 1 minute after anesthetic injection; and (A) 12 minutes after injection (when its effects had dissipated). The results showed that six of seven patients had no significant aphasia at baseline or 12 minutes after anesthetic injection. One patient had a mild conduction aphasia at baseline and after anesthetic effects had dissipated. In the six patients with temporoparietal AVM, anesthetic injections into vessels in the lower division of the middle cerebral artery (MCA) not feeding the AVM (e.g., the left angular artery) produced a wide range of language function—from conduction aphasia to dense Wernicke's syndromes. When upper division MCA vessels were injected (e.g., the prefrontal branch), all developed a major aphasic disorder with significant comprehension defects. A seventh patient with a frontal opercular AVM had a mild anomia, semantic paraphasias, and decreased word-list generation when the prefrontal branch was injected. Her comprehension, however, was intact. These data show that patients with posterior cerebral AVM can show language abnormalities where such deficits are not typically seen after acute brain injury. These findings support a posterior-to-anterior extension of some language skills under conditions of brain disease.

NEUROLOGY 1997;49:802–808

Acquired disorders of language can arise from many etiologies, such as stroke,¹ trauma,² tumor,³ and most other causes of cerebral dysfunction.⁴ Although there is extensive literature on the relationship between lesion location and aphasia syndrome,^{5,6} much less is known regarding the neural networks responsible for language function in patients with brain

lesions. The purpose of this study was to delineate some of the features of the neural compensatory mechanism that may be associated with language reorganization.

We chose cerebral arteriovenous malformation (AVM) as our disease model because its evaluation and treatment represented a unique opportunity to

From the Departments of Neurology (Drs. Lazar, Marshall, and Mohr), Radiology (Drs. Pile-Spellman, Haccin-Bey, and Young), Anesthesiology (Dr. Young), and Neurological Surgery (Drs. Lazar, Mohr, Young, and Stein), Columbia-Presbyterian Medical Center, New York, NY.

Supported in part by PHS grant NS27713.

Presented in part at the 48th annual meeting of the American Academy of Neurology, San Francisco, CA, February 1996.

Received October 3, 1996. Accepted in final form April 2, 1997.

Address correspondence and reprint requests to Dr. Ronald M. Lazar, Neurological Institute, Columbia-Presbyterian Medical Center, 710 West 168th Street, New York, NY 10032.

study the localization of higher cerebral functions. Arteriovenous malformations in the brain are thought to be the result of dysvasculogenesis during fetal development⁷ but patients usually do not become symptomatic until the middle decades of life.⁸ As part of the work-up for treatment consideration at our center, the territories of feeding, and adjacent, and remote arteries are studied in conscious patients with superselective neuroangiographic techniques, not only to assess hemodynamic contributions of blood vessels but also to ensure that therapeutic embolization or subsequent surgical resection will not affect eloquent functions.⁹ Prior to the delivery of embolic material (N-butyl cyanoacrylate), amobarbital sodium (USP) and a contrast medium are injected into a target vessel distal to the circle of Willis to produce temporary anesthesia in the focal brain region supplied by the artery. This superselective anesthetic technique is an adaptation of Wada's test used to determine cerebral dominance for memory and language in presurgical epileptic patients.¹⁰ The objective of this paper is to describe how the superselective anesthetic technique demonstrated an unexpected pattern of language organization in the brains of patients with left-hemisphere AVM.

Methods. Patients. Seven patients (two men and five women) were studied after informed consent was obtained for neuroangiography and possible embolization for a cerebral AVM. All patients were right handed and were studied between November 1994 and June 1996. Because of the idiosyncrasies often seen in the history and presentation of AVM, a brief clinical summary for each patient follows.

Patient 1 was a 27-year-old man who had a history of headache and was discovered to have a left parieto-occipital AVM in 1990. He underwent nine previous embolizations in 1990 and 1991. He never had a hemorrhage. His last embolization was associated with an ischemic stroke that produced speech difficulties. He returned to our center in 1994 with worsening headaches. On presentation he was found to have mild sensory aphasia but normal physical examination. Noncontrast CT of the brain (figure 1A, left) showed multiple coil and silastic bead embolic material, and acrylite in the left occipitoparietal region and left thalamus. There was a persistent lucency, compared with previous films, in the left posterior temporal and parietal region thought to represent the old infarct. Repeat angiogram (figure 1A, right) revealed a large, left occipitoparietal AVM with both superficial and deep drainage. Multiple arterial feeders were seen from the left middle cerebral artery (MCA), including a left angular artery feeder and a left posterior temporal artery feeder. There were also multiple left external carotid artery feeders as well as feeders from the left occipital artery and the left meningeal artery. There was occlusion of the left P2 segment of the posterior cerebral artery (PCA) and there were multiple posterior choroidal feeders off the proximal PCA.

Patient 2 was a 37-year-old woman who presented in August 1995 with a 6-month history of headache. Her neurologic examination was entirely normal. CT of the brain (figure 1B, left) suggested an AVM in the left temporal

lobe. An angiogram (see figure 1B, right) showed a small left anterior temporal AVM supplied by the anterior temporal branch of the left MCA draining into superficial cortical veins as well as into the basal vein of Rosenthal.

Patient 3 was a 25-year-old woman who reported a 1-year history of paresthesias in the right arm, blurring of visual fields, and recent episodes of speech difficulty and inability to understand language. She also developed nausea and dizziness. An EEG was negative. Neuropsychological evaluation showed some minor changes in verbal function but no aphasia. MRI (figure 1C, left), taken after her superselective Wada's test and first embolization, showed a $2 \times 2.5 \times 3$ -cm left parietal opercular AVM. There was no evidence of midline shift or significant mass effect. Cerebral angiography (see figure 1C, right) showed the AVM on the posterior aspect of the sylvian fissure, fed mainly by distal left MCA sylvian branches, and draining through a large vein of Trolard and a large vein of Labbé. Her data (later) were collected prior to embolization.

Patient 4 was a 42-year-old woman with increasing headaches for the year prior to April 1996 when she found that she was experiencing confused speech at work. A first seizure brought her to a local hospital. CT of the brain showed a left parietal lobe hemorrhage. She was placed on Dilantin and discharged. Seven days later she had a second seizure with aphasic features. CT and MRI (figure 1D, left) revealed a subacute hemorrhage. An angiogram showed a 1.5-cm AVM in the region of the hemorrhage and she was referred to our center for further treatment. The neurologic examination showed a mild conduction aphasia with some dysprosodic features in her speech. A left internal carotid injection during neuroangiography (see figure 1D, right) revealed a 2×3 -cm AVM in the left temporosylvian region at the junction between the temporal and parietal lobes, supplied mainly by the left angular artery and draining into the sigmoid sinus.

Patient 5 was a 29-year-old man who was well until April 1991 when he had a mild, focal seizure. MRI and angiographic evaluation at that time revealed a left parietal AVM, and he was treated with anticonvulsants alone. In July 1995 he developed a severe headache, diplopia, and impaired speech, and he was found to have a left temporal hemorrhage (figure 1E, left). He recovered significantly, with neuropsychologic testing disclosing some learning problems and a subtle language disorder at the time he presented at our center. His physical examination was normal. An angiogram (see figure 1E, right) demonstrated a small AVM in the left temporoparietal region supplied by the left angular artery with numerous branches in passage. The venous drainage was primarily superficial.

Patient 6 was a 15-year-old girl who experienced seven episodes of difficulty in using her right hand in April 1996. She was brought to a local hospital where she had the same problem in paroxysmal fashion in addition to nausea and vomiting. MRI of the brain showed a large left parietal AVM. After referral to our center, neuropsychological examination revealed a very mild sensory aphasia with otherwise normal reading comprehension. Her physical examination was normal. Neuroangiographic evaluation on 6/7/96 (figure 1F, right) revealed a moderate-size left central AVM supplied by the left MCA and anterior cerebral artery (ACA) branches with superficial venous drainage.

Patient 7 was a 29-year-old woman with migraine head-

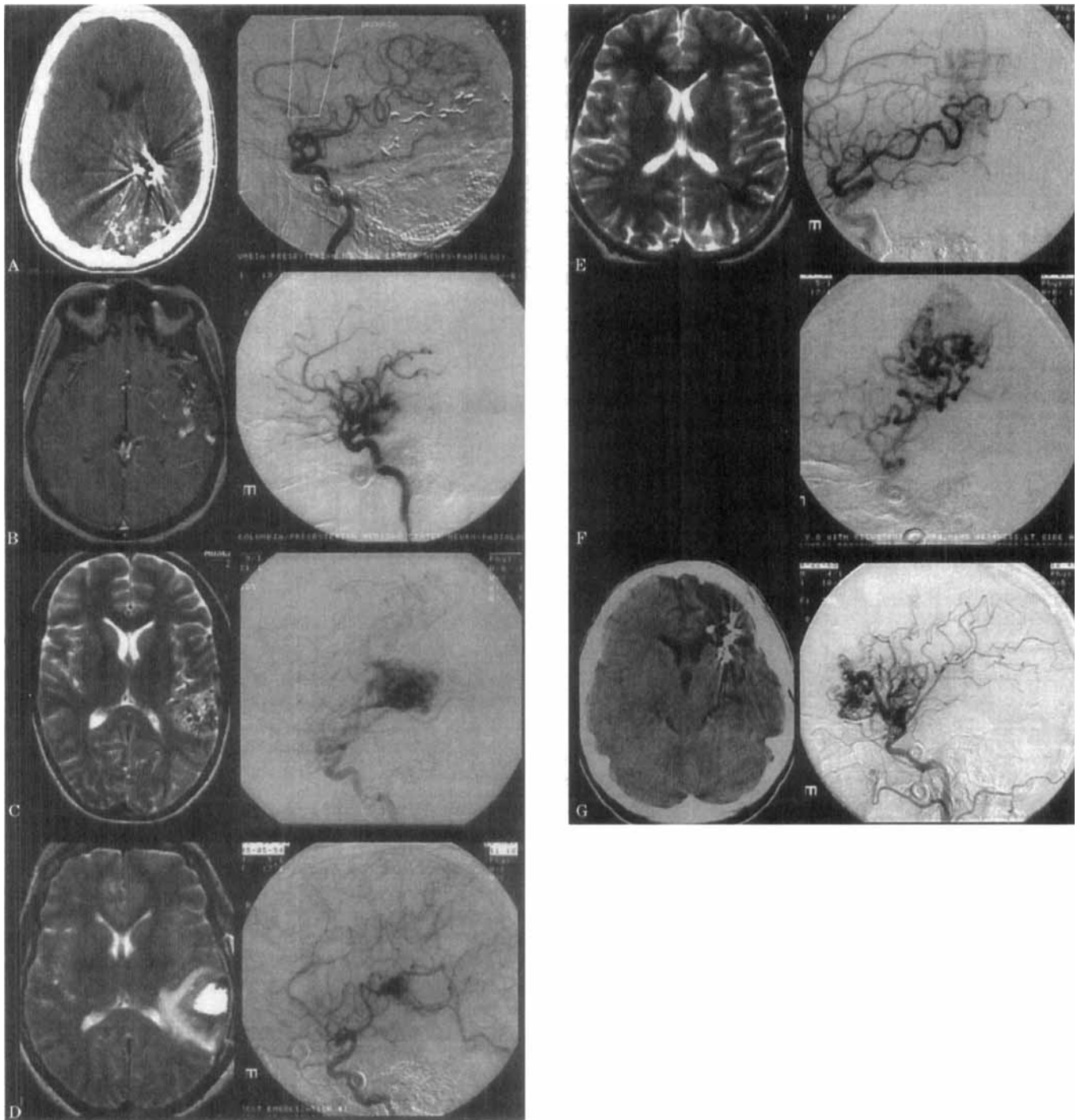


Figure 1. Left column shows representative CT or MRI for six of the seven study patients. CT for Patient 7 (1G, left) was postsurgical. The right column displays corresponding angiograms for all seven patients at the time of superselective Wada's testing.

ache who had sudden onset of severe headache, neck pain, and nausea and vomiting in June 1994. She improved to normal within 2 weeks, but 1 month later her symptoms recurred. CT of the brain revealed no new hemorrhage but a left frontal AVM. Following referral to our center, an angiogram (figure 1G, right) demonstrated a left frontal AVM with its main supply via left ACA branches (orbital frontal, frontal polar, anterior internal frontal arteries) as well as left MCA opercular and frontal branches. Following two embolizations she began to complain of memory problems, and neuropsychological examination showed her to

have some verbal memory dysfunction, dysnomia, and dyscalculia. Her physical examination was normal.

Superselective Wada's test. All testing was performed in the Embolization Suite. Patients were lightly sedated with midazolam, fentanyl, and propofol. The right common femoral artery was then punctured using a Pott's needle. A 7.5 French vascular sheath was inserted over a guide wire. A coaxial system, consisting of a 5 French inner hockey stick catheter and a 7 French outer guiding catheter, was then used to catheterize selectively the left internal carotid artery. After angiographic verification of catheter place-

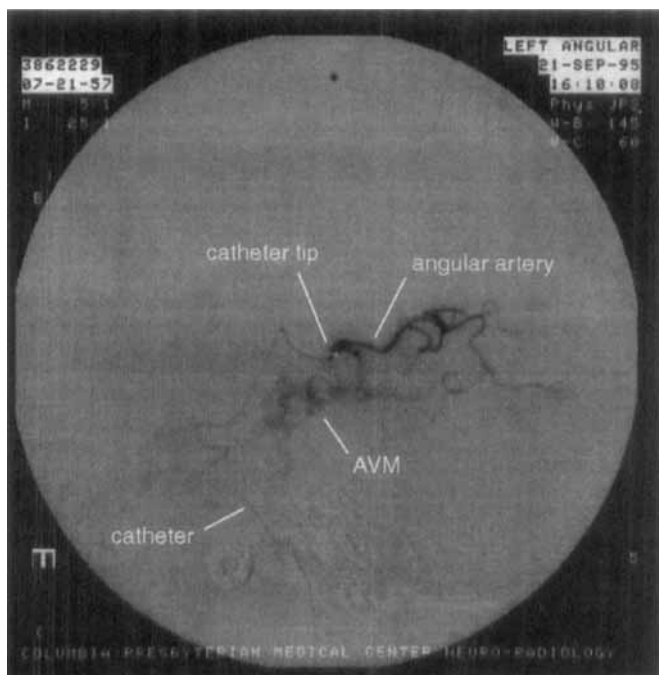


Figure 2. An angiogram demonstrating placement of a microcatheter into the left angular artery just prior to injection of amobarbital sodium/lidocaine and metrizamide.

ment, the 5 French hockey stick catheter was replaced by a 1.8 French Magic Balt microcatheter. The latter was navigated to the target vessel, such as to the left angular artery for Patient 1 as shown in figure 2. Mean arterial feeding pressures were measured at the catheter tip both in the arteries feeding AVMs and in the vessels undergoing superselective Wada's testing.

With the microcatheter in place in the target vessel, sedation was discontinued and patients underwent aphasia examination in an A-B-A design: (A) A 4- to 5-minute baseline language examination evaluating fluency, comprehension, naming, repetition, and oral reading. Materials were generally adapted from the Boston Diagnostic Aphasia Examination,¹¹ Boston Naming Test,¹² and the Wide Range Achievement Test.¹³ Then, 50 to 75 mg of amobarbital sodium and 20 mg of lidocaine opacified with metrizamide were injected, followed 1 minute later by (B) a repeat language examination. Twelve to 15 minutes after anesthetic injection, when the anesthetic effects were presumed to have dissipated, the language evaluation was performed again (A). The microcatheter was then removed from the initial artery and placed into the next target vessel, and the evaluative process was repeated until all vessels of interest had been studied. Determination of a change in language function was based on guidelines from the Boston Diagnostic Aphasia Examination¹¹ with an audio recording used for later verification. Because of variation in neurovascular architecture and the patients' tolerance of procedures, the same arterial territories could not be evaluated in all patients.

Results. All patients performed at their baseline clinical state in the Embolization Suite before and 12 to 15 minutes after amobarbital sodium injection. The table shows the nature and extent of language abnormality for the seven study patients during superselective Wada's testing.

Table The results of the language examination following injection of anesthetic in each target vessel for each patient.*

Patient	Injected vessel	Elicited syndrome
1	Angular artery	Wernicke's aphasia
	Prefrontal artery	Global aphasia
2	Angular artery	Wernicke's aphasia
	Prefrontal artery	Global aphasia
3	Angular artery	Wernicke's aphasia
	Insular artery	Semantic conduction aphasia
	Prefrontal artery	Global aphasia
4	Supramarginal artery	Conduction aphasia
	Angular artery	Conduction aphasia
	Frontal opercular branch of MCA	Mixed nonfluent aphasia
5	Superior temporal branch	Conduction aphasia
	Angular artery	No aphasia
	Posterior Rolandic artery	No aphasia
	Upper division of MCA	Global aphasia
	Lower division of MCA	Mild decrease in fluency but no aphasia
6	Upper division of MCA	Impaired comprehension, dysfluency, anomia, normal reading aloud
	Prerolandic artery	Anomia
7	Prefrontal artery	Semantic paraphasias, decreased word-list generation

*All arteries were in the left hemisphere.
MCA = middle cerebral artery.

The first six patients (Patients 1 to 6) had cerebral AVMs in temporoparietal regions, whereas Patient 7 had a frontal lobe AVM. All AVMs had low feeding pressures.

Five of the six patients with retrorolandic AVM had injections of the angular artery with a wide range of outcomes. Patients 2 and 3 developed dense Wernicke's aphasias (fluent speech with literal and verbal paraphasias, inability to follow any commands, poor repetition, and inability to name pictures), but Patient 1 only had a mild Wernicke's syndrome, demonstrated by mild comprehension defect, mildly impaired repetition ("They heard him speak on the rag. . .radio last night" for *They heard him speak on the radio last night*), and mild dysnomia with literal paraphasic errors ("bool" for *broom*; "pretza" for *pretzel*). Patient 4 had a conduction aphasia ("Fry the tin lid off" for *Pry the tin lid off*; "The phantom ducella across the foggy firth" for *The phantom soared across the foggy heath*) that was no different from her clinical level of function. Patient 5 showed no language changes in this condition, but he had a conduction aphasia following injection of

a medial temporal sylvian branch off the lower division of the MCA ("The yak leaks" for *The vat leaks*; "The fleece fled to Greece" for *The spy fled to Greece*). Patient 6 had a more global injection into the main branch of the lower division of the MCA, but there was no change in language except for dysfluency. Patient 3 also had injection of the insular artery, which produced an unusual form of "conduction" aphasia characterized by a disorder of repetition in which many of her errors were semantic rather than phonemic in nature. Whereas she made some literal paraphasias during animal naming such as "turkio" for *turkey* and "monkley" for *monkey*, she repeated the dictated sentence *The phantom soared across the foggy heath as* "The phantom flew over the...field." Semantic substitutions during repetition have recently been described following infarction limited to the posterior insula and immediately adjacent intrasylvian parietal operculum.¹⁴

There was greater uniformity in language abnormality during the peak anesthetic effect when the six patients with posterior AVM had injections in vessels in frontal regions anterior to their lesions. All developed a major aphasic syndrome with significant receptive language dysfunction. Following injection of the prefrontal artery, Patients 1, 2, and 3 became globally aphasic so that in addition to impaired vocalizations, they were unable to perform consistently even simple tasks on command. Patient 1 opened his mouth and stuck out his tongue to the plane of his lips when asked to "Stick out your tongue." When next asked to "Say the days of the week," he opened his mouth. When asked to show one finger, he responded by drawing a circle in the air and tapping each finger successively. He was unable to read any single words aloud or repeat single words. Patient 2 said numbers aloud when asked to say the days of the week. She appropriately opened her eyes when asked to do so, but when asked to repeat single words, she responded by saying numbers. Patient 3 developed a dense receptive aphasia and was unable to execute correctly any dictated commands. Her speech contained literal, semantic, and neologistic paraphasic errors.

Patient 4 received an injection into the frontal opercular branch in the upper division of the MCA. When asked to say the names of animals, she responded, "Six, six, six." She answered "No," to each of the initial eight questions from the Complex Ideational Material section (e.g., Does a stone sink in water?) from the Boston Diagnostic Aphasia Examination.

Patients 5 and 6 had an injection of the entire upper division of the MCA. The former developed a severe global aphasia with virtually no measurable language. Patient 6 was dysfluent and dysarthric with significant receptive dysfunction. She answered 5 of 8 questions correctly on the initial eight questions from the Complex Ideational Material. She could not provide the names of any animals in 1 minute. The dictated sentence *The spy fled to Greece* yielded "The sply full to Greece." Her oral reading of single words, however, was normal with no alexic errors.

Patient 7 was the only example in this cohort of patients with an AVM in the left frontal lobe. No vessel in the lower MCA division was explored. In the frontal region, an injection in the prerolandic artery produced a mild anomia. When the prefrontal artery was investigated she produced semantic paraphasic errors and her word-list

generation decreased from her preinjection baseline. Her comprehension, however, remained intact.

Discussion. The application of Wada's test to the selective study of vessels prior to embolization of AVM feeding vessels has seen considerable recent development. Rauch et al.¹⁵ found 23 positive amobarbital sodium tests out of 109 injections, and Han et al.¹⁶ found 11 positive tests out of 66 vessels evaluated. In all patients, however, the arteries undergoing superselective testing were those feeding the AVM. To our knowledge, our study is the first to explore vessels remote from the lesion.

Our series of mainly posterior AVM demonstrated varying degrees of aphasia during the peak anesthetic effect when vessels supplying posterior parietal and temporal brain regions were injected, findings consistent with the expected involvement of these regions in speech-language processes. The major new finding in these patients was that when arteries in the superior division of the MCA in the frontal lobe were anesthetized, all six patients developed a major aphasic syndrome that included severe comprehension deficits. We interpret these data to indicate that patients with posterior AVM in the left hemisphere can show language abnormalities in frontal regions where such deficits are not typically seen after acute focal brain injury, such as stroke. These findings support a posterior-to-anterior extension of some language functions under conditions of brain abnormality. The only patient not to demonstrate such profound receptive language deficits with a frontal injection was Patient 7, who had a frontal lobe AVM, indicating that frontal artery anesthesia per se was not sufficient to produce comprehension defects in this setting. Simple learning effects could not account for our findings since the order of arterial studies varied randomly across patients and repeated exposures to language tests did not improve performance. Patients 1, 2, 3, and 5, for example, demonstrated their most severe disorders in the last vessel studied.

Patients with acute infarction in the territory of the upper division of the MCA can present with global aphasia, but the lesion is very large, encompassing not only Broca's area but also the insula and the adjacent operculum from the frontal to the parietal lobe.⁴ Alexander et al.¹⁷ reported comprehension deficits in nine patients with infarcts in the region of the left frontal operculum. Their CT data, however, showed that in every patient the lesion extended to the insula cortex. Injury to the left insula, has been shown to produce aphasias with sensory features.¹⁸ In the series reported here, anesthetic injections in the prefrontal and frontal opercular branches, with no radiographic evidence of perisylvian involvement, produced marked comprehension defects. Lesions restricted to Broca's area may produce an initial mutism with buccofacial dyspraxia, but comprehension of auditory and visual language information is virtually intact.¹⁹ The simultaneous injection of contrast

material with amobarbital sodium provided a means of determining the region of induced anesthesia in the present study, and in four of the six patients with posterior AVMs, the affected territory in the single arterial branch of the frontal lobe more closely approximated the size seen in Broca's area infarction. The defect in receptive language seen in Patients 5 and 6 with complete upper division injections was not merely the grammatical comprehension difficulty seen in Broca's aphasia,⁵ but gross dysfunction for even simple, auditory comprehension.

Other authors have made observations consistent with this interpretation in individual patients. Martin et al.²⁰ reported the case of a right-handed patient with a 3.5-cm AVM involving the posterior temporal branches of the left MCA and two temporal branches of the left PCA. Superselective testing was performed in the posterior temporal branch of the left MCA with contrast medium that demonstrated filling of a branch supplying the superior temporal gyrus. There were no receptive or expressive language deficits identified, suggesting the absence of language function in that region. Our data suggest that language skills could have extended to new regions in this patient.

Our observations do not modify the well-documented evidence that patients with stroke, the most common cause of aphasia, have extremely variable language recovery. Factors involved in the outcome are thought to be related to location and size of infarcted brain tissue,²¹ and the degree of severity of the initial aphasic syndrome.²²⁻²⁵ Since the brain does not regenerate its neural tissue, a functional reorganization must be assumed.²⁶

It is not yet clear how such improvements or changes occur, but evidence supports a role in both the ipsilateral (left) and contralateral (right) hemisphere,^{27,28} findings supported by regional cerebral blood flow (rCBF) changes.^{26,29-31} More recently there has been increasing evidence in PET studies that the left hemisphere may play a crucial role in recovery from aphasia. Heiss et al.,³² using resting and activation (with spontaneous speech) procedures, studied patients 12 to 18 days following left MCA stroke and again after 4 months. They found that in addition to metabolic rates in the mirror region in the right hemisphere, the intactness of the left hemisphere was an important predictor of recovery. Kamimoto et al.³³ evaluated patients with PET after acute, left-hemisphere stroke, and again after 3 to 49 months. All patients demonstrated improvement on a clinical stroke scale during the study period. Among these regions both rCBF and CMRO₂ were significantly increased in the middle frontal gyrus, inferior frontal gyrus, supramarginal gyrus, and angular gyrus. In the right hemisphere, both rCBF and CMRO₂ were increased in every measured region except the thalamus, especially in the supramarginal gyrus. Collectively these data therefore suggest that intact re-

gions ipsilateral to the damaged brain are important for language recovery.

There are little data showing that such brain structures are *necessary* for language recovery to take place. Indeed, the PET studies described have shown bilateral activation with language tasks but a single, ischemic stroke in the homologous region in the right hemisphere rarely produces aphasia. A recent study³⁴ with normal subjects using functional MRI demonstrated extensive left prefrontal activation, but the investigators noted that functional imaging techniques do not distinguish between critical areas from those that participate in a task. To confirm the importance of a region to recovery, an experimental model is needed to establish a causal relationship between a brain site and a target function. The application of superselective testing with amobarbital sodium in target arteries using an A-B-A experimental design may represent such a model.

The reorganizational process for language recovery following stroke may not represent the same mechanism of language relocation in patients with cerebral vascular malformations. Neuropsychological investigations of patients before surgical resection of AVMs have yielded variable results with respect to localization of function, and most neurocognitive studies have not been able to demonstrate the kind of impairment typically seen with acute focal lesions in comparable brain regions.^{35,36} Brown et al.³⁷ and Mahalick et al.³⁸ suggest that one possible reason for the variability of neuropsychological impairment seen among AVM patients could be atypical organization of language function. Moreover, intracranial AVMs are congenital lesions composed of a coiled mass of arteries and veins lying in a bed formed by displacement rather than invasion of normal brain tissue. AVMs appear to undergo an unclear development process for many years until some critical mass is reached and symptoms (often seizures or hemorrhage) occur. "Steal" is unlikely to account for the redistribution of function since recent data have suggested that focal neurologic deficits are rare at the time of presentation, except in cases of hemorrhage.³⁹ Moreover, many of the vessels serving language areas injected in this series had very low feeding pressures. At this point it is not known when this reorganization begins, or whether it needs to begin in childhood or can occur later in life.

There were several matters that this study did not address. First, we examined only selected vessels in each patient, and not all patients underwent the same superselective studies. All patients had cerebral AVMs as a common feature but one had infarction 3 years earlier, one a cerebral hemorrhage 1 year earlier, and one a cerebral hemorrhage 1 month earlier than the superselective study. We were able to demonstrate that certain regions were necessary for language function but other regions that were not evaluated could have also been important. In addition, we did not determine the contribution of the right hemisphere to language function in these pa-

tients. Nevertheless, this research demonstrates a new method of study in the cerebral localization of behavior and some of the redistribution of function from posterior to anterior regions that can occur.

References

- Mohr JP, Gautier JC, Hier DB. Middle cerebral artery disease. In: Barnett HJM, Mohr JP, Stein BM, eds. *Stroke pathophysiology, diagnosis, and management*. 2nd ed. London: Churchill Livingstone, 1992:361-417.
- Luria AR. *Traumatic aphasia*. Hague: Mouton, 1970.
- Anderson SW, Damasio H, Tranel D. Neuropsychological impairment associated with lesions caused by tumor and stroke. *Arch Neurol* 1990;47:397-405.
- Lazar RM, Marshall RM, Mohr JP. Aphasia and stroke. In: Bogousslavsky J, Caplan L, eds. *Stroke syndromes*. New York: Cambridge University Press, 1995:118-133.
- Albert ML, Goodglass J, Helm N, Rubens AB, Alexander MP. *Clinical aspects of dysphasia*. Berlin: Springer-Verlag, 1982.
- Damasio AR. Aphasia. *N Engl J Med* 1992;326:531-539.
- Robinson JR, Awad IA, Zhou P, Barna BP, Estes ML. Expression of basement membrane and endothelial cell adhesion molecules in vascular malformations of the brain: preliminary observations and working hypothesis. *Neurol Res* 1995;17:49-58.
- Mohr JP, Hilal SK, Stein BM. Arteriovenous malformations and other vascular anomalies. In: Barnett HJM, Mohr JP, Stein BM, eds. *Stroke: pathophysiology, diagnosis, and management*. 2nd ed. London: Churchill Livingstone, 1992:645-670.
- Young WL, Pile-Spellman J. Anesthetic considerations for interventional neuroradiology. *Anesthesiology* 1994;80:427-456.
- Wada J, Rasmussen T. Intracarotid injection of sodium Amytal for the lateralization of cerebral speech dominance: experimental and clinical observations. *J Neurosurg* 1960;17:266-282.
- Goodglass H, Kaplan E. *Boston Diagnostic Aphasia Examination (BDAE)*. Philadelphia: Lea & Febiger, 1983.
- Kaplan E, Goodglass H, Weintraub S. *The Boston Naming Test*. Philadelphia: Lea & Febiger, 1983.
- Jastak S, Wilkinson GS. *The Wide Range Achievement Test-Revised*. Wilmington, DE: Jastak Assessment Systems, 1984.
- Marshall RS, Lazar RM, Mast H, Mohr JP. "Semantic conduction" aphasia from a posterior insular cortex infarction. *J Neuroimaging* 1996;6:189-191.
- Rauch RA, Vinuela F, Dion J, et al. Preembolization functional evaluation in brain arteriovenous malformations: the superselective Amytal test. *Am J Neuroradiol* 1992;13:303-308.
- Han MH, Chang KH, Han DH, Yeon KM, Han MC. Preembolization functional evaluation in supratentorial cerebral arteriovenous malformations with superselective intraarterial injection of thiopental sodium solution. *Acta Radiol* 1993;35:212-216.
- Alexander MP, Naeser MA, Palumbo C. Broca's area aphasia: aphasia after lesions including the frontal operculum. *Neurology* 1990;40:353-362.
- Damasio H, Damasio AR. *Lesion analysis in neuropsychology*. New York: Academic Press, 1989.
- Mohr JP. Broca's area and Broca's aphasia. In: Whitaker H, ed. *Studies in neurolinguistics*. New York: Academic Press, 1976:201-235.
- Martin NA, Beatty J, Johnson RA, et al. Magnetoencephalographic localization of a language cortical area adjacent to a cerebral arteriovenous malformation. *J Neurosurg* 1993;79:584-588.
- Wityk RJ, Pessin MS, Kaplan RF, Caplan LR. Serial assessment of acute stroke using the NIH stroke scale. *Stroke* 1994;25:362-365.
- Kertesz A, McCabe P. Recovery patterns and prognosis in aphasia. *Brain* 1977;100:1-18.
- Pedersen PM, Jorgensen HS, Nakayama H, Raaschou HO, Olsen TS. Aphasia in acute stroke: incidence, determinants, and recovery. *Ann Neurol* 1995;38:659-666.
- Kertesz A, Poole E. The aphasia quotient: the taxonomic approach to measurement of aphasic disability. *Can J Neurol Sci* 1974;1:7-16.
- Karbe H, Kessler J, Herholz K, Fink GR, Heiss W-D. Long-term prognosis of poststroke aphasia studied with positron emission tomography. *Arch Neurol* 1995;52:186-190.
- Weiller C, Isensee C, Rijntjes M, et al. Recovery from Wernicke's aphasia: a positron emission tomographic study. *Ann Neurol* 1995;37:723-732.
- Kinsbourne M. The minor cerebral hemisphere as a source of aphasic speech. *Arch Neurol* 1971;25:302-306.
- Basso A, Gardelli M, Grassi MP, Mariotti M. The role of the right hemisphere in recovery from aphasia: two case studies. *Cortex* 1989;25:555-556.
- Knopman DS, Rubens AB, Selnes O, Klassen AC, Meyer MW. Mechanisms of recovery from aphasia: evidence from serial xenon 133 cerebral flow studies. *Ann Neurol* 1984;15:530-535.
- Demeurisse G, Capon A. Language recovery in aphasic stroke patients: clinical, CT and CBF studies. *Aphasiology* 1987;1:301-315.
- Chollet R, DiPietro V, Wise JS, Brook DJ, Dolan RJ, Frackowiak RSJ. The functional anatomy of motor recovery after stroke in humans: a study with positron emission tomography. *Ann Neurol* 1991;29:63-71.
- Heiss W-D, Kessler J, Karbe H, Fink GR, Pawlik G. Cerebral glucose metabolism as a predictor of recovery from aphasia in ischemic stroke. *Arch Neurol* 1993;50:958-964.
- Kamimoto K, Kabasawa H, Nakazawa M, Matsubara M, Hibino H, Nagai H. Changes in cerebral circulation and metabolism with recovering aphasia [abstract]. *J Cereb Blood Flow Metab* 1995;5(suppl 1):S187.
- Binder JR, Frost JA, Hammeke TA, Cox RW, Rao SM, Prieto T. Human brain language areas identified by functional magnetic resonance imaging. *J Neurosci* 1997;17:353-362.
- Waltimo O, Putkonen A-R. Intellectual performance of patients with intracranial arteriovenous malformations. *Brain* 1974;97:511-520.
- Brown GG, Spicer KB, Robertson WM, Baird AD, Malik G. Neuropsychological signs of lateralized arteriovenous malformations: comparison with ischemic stroke. *Clin Neuropsychol* 1989;3:340-352.
- Brown GG, Spicer K, Malik G. Neurobehavioral correlates of arteriovenous malformations and cerebral aneurysms. In: Bornstein RA, Brown G eds. *Neurobehavioral aspects of cerebrovascular disease*. New York: Oxford University Press, 1991:202-223.
- Mahalik DM, Ruff RM, Sang H. Neuropsychological sequelae of arteriovenous malformations. *Neurosurgery* 1991;29:351-357.
- Mast H, Mohr JP, Osipov A, et al. "Steal" is an unestablished mechanism for the clinical presentation of cerebral arteriovenous malformations. *Stroke* 1995;26:1215-1220.

Neurology[®]

Anterior translocation of language in patients with left cerebral arteriovenous malformation

R. M. Lazar, R. S. Marshall, J. Pile-Spellman, et al.
Neurology 1997;49;802-808
DOI 10.1212/WNL.49.3.802

This information is current as of September 1, 1997

Updated Information & Services	including high resolution figures, can be found at: http://www.neurology.org/content/49/3/802.full.html
References	This article cites 27 articles, 2 of which you can access for free at: http://www.neurology.org/content/49/3/802.full.html##ref-list-1
Citations	This article has been cited by 10 HighWire-hosted articles: http://www.neurology.org/content/49/3/802.full.html##otherarticles
Permissions & Licensing	Information about reproducing this article in parts (figures, tables) or in its entirety can be found online at: http://www.neurology.org/misc/about.xhtml#permissions
Reprints	Information about ordering reprints can be found online: http://www.neurology.org/misc/addir.xhtml#reprintsus

Neurology® is the official journal of the American Academy of Neurology. Published continuously since 1951, it is now a weekly with 48 issues per year. Copyright . All rights reserved. Print ISSN: 0028-3878. Online ISSN: 1526-632X.

