

7. Nuovo GJ, Alfieri ML. AIDS dementia is associated with massive, activated HIV-1 infection and concomitant expression of several cytokines. *Mol Med* 1996;2:1076-1551
8. Nuovo GJ, Forde A. An improved system for reverse transcriptase in situ PCR. *J Histotech* 1995;18:295-299
9. Zehender G, De Maddalena C, Osio M, et al. High prevalence of human T cell lymphotropic virus type II infection in patients affected by human immunodeficiency virus type I-associated predominantly sensory polyneuropathy. *J Infect Dis* 1995;172:1595-1598
10. Rance N, McArthur JC, Cornblath DR, et al. Gracile tract degeneration in patients with sensory neuropathy and AIDS. *Neurology* 1988;38:265-271
11. Bagasra O, Lavi E, Bobroski L, et al. Cellular reservoirs of HIV-1 in the central nervous system of infected individuals: identification by the combination of in situ polymerase chain reaction and immunohistochemistry. *AIDS* 1996;10:573-585
12. Nuovo GJ, Gallery F, MacConnell P, Braun A. In situ detection of polymerase chain reaction-amplified HIV-1 nucleic acids and tumor necrosis factor- α RNA in the central nervous system. *Am J Pathol* 1994;144:659-666
13. Swingler S, Easton A, Morris A. Cytokine augmentation of HIV-1 LTR-driven gene expression in neural cells. *AIDS Res Hum Retrovir* 1992;8:487-493
14. Tornatore C, Nath A, Amemiya K, Major EO. Persistent human immunodeficiency virus type 1 infection in human fetal glial cells reactivated by T-cell factor(s) or by the cytokines tumor necrosis factor α and interleukin-1 β . *J Virol* 1990;65:6094-6100
15. Kolson DL, Collman R, Hrin R, et al. Human immunodeficiency virus type 1 Tat activity in human neuron cells: uptake and trans-activation. *J Virol* 1994;75:1927-1934

Factor V Leiden Mutation: An Unrecognized Cause of Hemiplegic Cerebral Palsy, Neonatal Stroke, and Placental Thrombosis

Olafur Thorarensen, MD,* Stephen Ryan, MD,* Jill Hunter, MD,† and Donald P. Younkin, MD*

Activated protein C resistance caused by an Arg⁵⁰⁶Gln mutation in the factor V gene (factor V Leiden mutation) is the most common cause of familial thrombosis. This

From the Divisions of *Neurology and †Neuroradiology, Children's Hospital of Philadelphia, and Departments of *Neurology, *Pediatrics, and †Radiology, University of Pennsylvania, Philadelphia, PA.

Received Jan 2, 1997, and in revised form Mar 4. Accepted for publication Mar 10, 1997.

Address correspondence to Dr Younkin, Division of Neurology, 6th Floor, Wood Bldg, Children's Hospital of Philadelphia, 34th St and Civic Center Blvd, Philadelphia, PA 19104.

mutation is associated with arterial and venous thromboembolic disease in neonates, infants, and children, but is not a significant risk factor for ischemic stroke in adults. We report on 3 babies with different neonatal cerebrovascular disorders including ischemic infarction and hemorrhagic stroke who are heterozygous for factor V Leiden mutation. One infant had multiple thrombi in the fetal placental vasculature. This is the first reported association between hemiplegic cerebral palsy, placental thrombosis, and factor V Leiden mutation. We suspect that activated protein C resistance may be an important cause of in utero cerebrovascular disease and hemiplegic cerebral palsy.

Thorarensen O, Ryan S, Hunter J, Younkin DP. Factor V Leiden mutation: an unrecognized cause of hemiplegic cerebral palsy, neonatal stroke, and placental thrombosis. *Ann Neurol* 1997;42:372-375

Activated protein C (APC) resistance due to factor V Leiden mutation is the most common cause of familial thrombosis [1]. It has a prevalence of 2 to 7% [2-4], is found in all ethnic groups studied to date, and is 10 times as common as protein C, protein S, and antithrombin III deficiencies [3]. Although APC resistance is associated with thromboembolic disease [4] including stroke in childhood and young adults [5-7], its association with hemiplegic cerebral palsy or placental thrombosis has not been reported. We report 3 babies who are heterozygous for factor V Leiden mutation and had neonatal cerebrovascular disorders, including ischemic infarction and hemorrhagic stroke. Multiple placental thrombi were present on the fetal side in one of these infants. Recent studies report that 40% of cerebral palsy (CP) is related to vascular factors, including infarction and hemorrhage [8]. We suspect that factor V Leiden mutation may be an important cause of neonatal stroke, CP, and placental thrombosis.

Case Reports

Case 1

A male infant presented at 6 months of age with right hemiplegia, which was first observed at 3 months. The last week of the pregnancy was complicated by toxemia, which was treated with magnesium sulfate. He was born at term by spontaneous vaginal delivery to a 30-year-old G2P1 (two pregnancies, one viable birth) mother. Birth weight was 7 lb 12 oz. Apgar score was 8 and 8 after 1 and 5 minutes. On the first day of life, he had mild respiratory problems, possibly related to magnesium-induced weakness, and required supplemental oxygen. He did not have other neurologic problems in the nursery and was discharged on day 3 of life. Early development was normal, but by 3 months he had a left-hand preference. His father had a history of deep vein thrombosis treated with warfarin. Physical examination revealed right spastic emiparesis with the arm more involved than the leg, and mild right facial weakness. Magnetic reso-

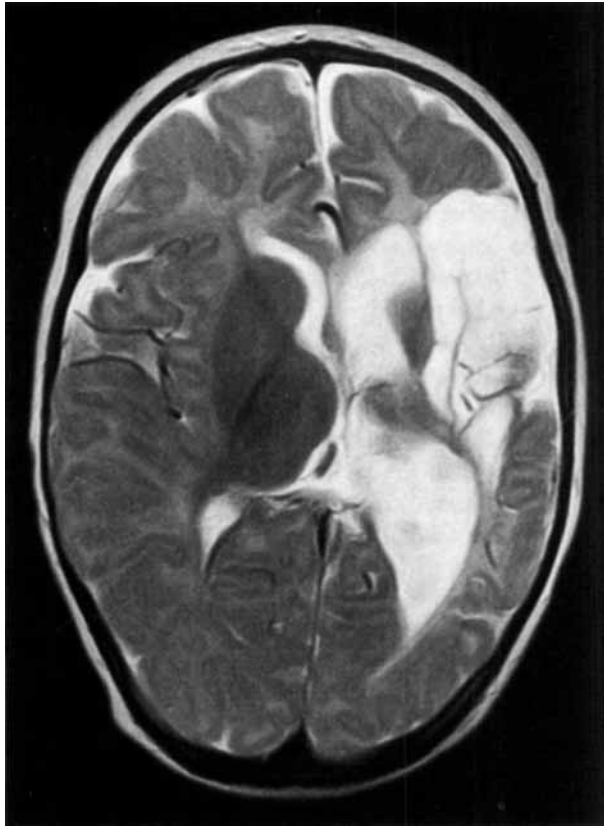

Fig 1. T2-weighted image showing atrophy with ex vacuo dilatation of the body of the lateral ventricle and gliosis in the left frontotemporal region without evidence of blood products. Imaging in other planes confirmed the absence of any communication with the body of the left lateral ventricle. A magnetic resonance angiogram performed concurrently revealed a small left middle cerebral artery.

nance imaging (MRI) of the head performed at 2 years of age disclosed a large left middle cerebral artery distribution area of encephalomalacia involving the frontotemporal region with evidence of gliosis (Fig 1). The patient and his father were heterozygous for the factor V Leiden mutation. The mutation was detected with polymerase chain reaction and the restriction enzyme *MnlI* as described by Bertina and colleagues [2]. Determinations of complete blood count (CBC), prothrombin time (PT), partial thromboplastin time (PTT), protein C, protein S, antithrombin III, and bleeding time were normal. He was not anticoagulated and has not had subsequent thrombotic events. At 30 months, he has persistent hemiparesis, mild global developmental delay, and intractable seizures.

Case 2

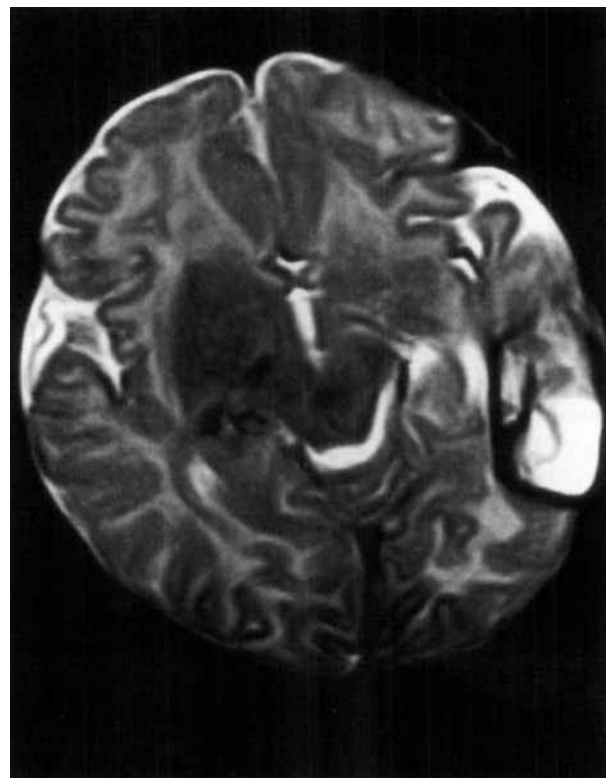
A female infant was referred at 1 month of age for evaluation of neonatal hemorrhagic cerebral infarction. She was born by spontaneous vaginal delivery after an uncomplicated 36-week pregnancy to a 26-year-old G1P0 mother. Birth weight was 5 lb 11 oz. Apgar score was 6 and 8 after 1 and 5 minutes. On day 1 of life, she had mild respiratory difficulty, rapidly

falling hematocrit (40% to 33%), and hemorrhagic cerebrospinal fluid (CSF red blood cells: 2,200). She had no clinical seizures and her neurologic examination was nonfocal. Her paternal grandfather had a stroke at 53 years of age and the maternal great grandfather had a myocardial infarction at 46 years of age. Computed tomographic scanning of the head on day 3 of life disclosed a left parietal intraparenchymal and subarachnoid hemorrhage. She was discharged on day 6 of life and did not have subsequent neurologic problems. An MRI of the head at 3 months revealed a large left temporal-parietal hemorrhagic infarction (Fig 2). She and her mother were heterozygous for factor V Leiden mutation, detected by the method described by Bertina and colleagues [2]. CBC, PT, PTT, protein C, protein S, and antithrombin III were normal. She was not treated and has not had subsequent thrombotic events.

Case 3

A female infant presented on the first day of life with neonatal seizures. She was born at term after an uneventful gestation to a 20-year-old G1P0 mother. During labor, meconium-stained amniotic fluid was noted and several late fetal heart decelerations occurred. She was born by vaginal delivery with low forceps assistance, suctioned, and intubated. A small amount of thin meconium was obtained on the first intubation. Birth weight was 7 lb. Apgar score was 8 and 9 after 1 and 5 minutes. At 6 hours of age repetitive,

Fig 2. Axial T2-weighted image demonstrating loss of brain tissue with a rim of hemosiderin (T2 hypointensity) in the left posterior temporal region in association with altered blood products (T2 bright signal).



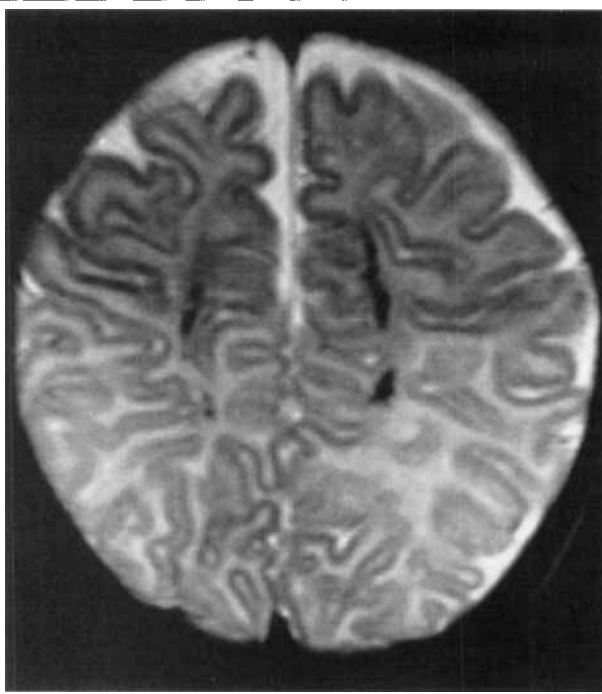


Fig 3. Axial T2-weighted slice acquired near the vertex, returning T2 dark signal consistent with hemosiderin deposition in the centra semiovale overlying the bodies of the lateral ventricles, secondary to prior hemorrhage in the periventricular white matter.

brief focal seizures were noted. With the exception of lethargy and hypotonia, neurologic examination disclosed no abnormalities. Family history was nonrevealing. MRI showed hemorrhagic periventricular leukomalacia (Fig 3). DNA analysis, described by Bertina and colleagues [2], showed that she was heterozygous for the factor V Leiden mutation. Protein S determination was normal. Protein C functional assay was 46% of control (normal adult range, 72–142% of control). The placenta was grossly normal, but histological examination revealed intravascular thrombosis associated with fragmentation of erythrocytes in multiple fetal vessels. The infant was discharged from the hospital at 6 days of age, appearing well. She was treated with coumadin and has not had subsequent thrombotic events.

Discussion

Rapid but controlled thrombosis results from a complex balance between coagulant and anticoagulant factors. APC is an important anticoagulant factor. Thrombin formed at sites of vascular injury leads to coagulation by converting factors V and VIII to activated forms (Va and VIIIa), but it also activates protein C by binding with the endothelial membrane protein thrombomodulin. APC, with its cofactor protein S, acts as an anticoagulant by inactivating both Va and VIIIa [9]. Deficiencies of protein C, protein S, and antithrombin III are recognized causes for familial thrombosis, but they only comprise a small percentage of pa-

tients with thrombophilia; the overwhelming majority are due to APC resistance [9].

In 1993 Dahlbäck and collaborators [3, 10] reported a family with autosomal dominantly inherited venous thrombosis secondary to APC resistance. Subsequently, APC resistance was localized to a point mutation in the factor V gene that replaces arginine with glutamine at the cleavage site for APC on factor Va [1, 2]. Mutated factor Va has procoagulant activity but is resistant to APC [8]. Factor V Leiden mutation occurs in 2 to 6% of the population and causes most cases of APC resistance [2, 4].

The relationship between factor V Leiden mutation and venous thromboembolic disease has been established in children [11] and adults [4]. Three recent studies show that this mutation is not a significant risk factor for ischemic stroke [4, 12] or transient ischemic attack [13] in adults. However, the prevalence of APC resistance and factor V Leiden mutation appears to be higher in pediatric and juvenile stroke populations [5–7, 14]. Simioni and co-workers [5], in their report on three Italian families with hereditary APC resistance, found 1 heterozygous 8-month-old child with ischemic stroke without any other known prothrombotic conditions. Ganesan and associates [6] found that 16% of their British pediatric stroke population was heterozygous for factor V Leiden mutation. The prevalence of factor V Leiden mutation was 38% in a German population of neonates, infants, and children with arterial thromboembolic disease [7]. This study found arterial stroke predominantly in the neonatal age group but did not specify how many neonates had factor V Leiden mutation. Young patients with this mutation, in addition to other risk factors for thrombosis, may not survive to adulthood. To our knowledge, this is the first report linking factor V Leiden mutation and hemiplegic cerebral palsy.

Familial thrombosis is rarely associated with neonatal stroke. Babies who are homozygous for protein C or protein S deficiency can develop cerebral infarction in association with purpura fulminans, a fatal thromboembolic condition [15]. Both heterozygous and homozygous cases of factor V Leiden mutation have increased risk for thrombosis throughout life but usually are asymptomatic in youth unless associated with other acquired or genetic prothrombotic conditions, including central venous catheters, trauma, surgery, cancer, pregnancy, oral contraceptives, deficient protein C or protein S, and homocystinuria [7, 16–19].

Several factors unique to the fetus may predispose these babies to in utero infarction. The thrombotic system in the normal fetus is tilted slightly in favor of thrombosis; factor V Leiden mutation could further alter the balance toward pathologic thrombosis. The fetus has a high hematocrit and relatively slow blood flow, factors known to lead to thrombosis in older chil-

dren. Finally, the fetus has a patent foramen ovale, which allows venous emboli to enter the arterial system. More than 60% of fetal cardiac output goes to the brain, which would predispose it to embolic infarction. In comparison with the right common carotid artery, the left has a relatively straight path, which would lead to preferential streaming and explain the higher incidence of left hemispheric infarction in neonates. We suspect that, as in adults, venous thrombosis and embolic stroke may be the predominant mechanism of infarction in neonates with factor V Leiden mutation.

Long-term anticoagulation prevents recurrent thrombosis in patients with factor V Leiden mutation [9, 11] but has considerable risk in infants and toddlers. The incidence of recurrent infarction in babies with neonatal stroke is extremely low; therefore, we did not anticoagulate Case 1 and Case 2. Given the coexistence of low protein C functional assay and factor V Leiden mutation, predisposing to thromboembolism, anticoagulation with coumadin was initiated in Case 3. With follow-up as long as 2 years, none has had subsequent venous or arterial thrombosis.

Placental thrombosis in the fetal and maternal circulation has been associated with maternal coagulopathies [20]. Recurrent abortions and placental infarctions were reported in 3 women both heterozygous for homocystinuria and factor V Leiden mutation [19]. This is the first report linking placental thrombosis and factor V Leiden mutation without other prothrombotic conditions.

CP is one of the most common neurologic disorders of childhood. It occurs in 0.25% of live births and affects more than 100,000 American children. Known perinatal complications comprise fewer than 20% of the cases of CP; the vast majority are attributed to unknown prenatal factors. A recent MRI-based study attributed 40% of the cases to usually unknown vascular factors [8]. We speculate that some of these were secondary to factor V Leiden-induced cerebral infarction.

Infantile hemiplegia is frequently attributed to pre- or perinatal cerebral infarction, but the etiology is usually unknown. As demonstrated by these 3 babies, factor V Leiden mutation may cause hemiplegic CP and hemorrhagic stroke. We recommend testing for this mutation in all babies with unexplained prenatal or neonatal cerebral infarction or CP related to vascular events, especially if there is a family history of venous thrombosis, early stroke, or heart disease.

We thank Dr Robert Clancy for referring a patient included in this report, and Dr Katherine A. High for testing for factor V Leiden mutation and helpful discussion.

References

1. Zöller B, Dahlbäck B. Linkage between inherited resistance to activated protein C and factor V gene mutation in venous thrombosis. *Lancet* 1994;343:1536–1538
2. Bertina RM, Koeleman BPC, Koster T, et al. Mutation in blood coagulation factor V associated with resistance to activated protein C. *Nature* 1994;369:64–67
3. Svensson PJ, Dahlbäck B. Resistance to activated protein C as a basis for venous thrombosis. *N Engl J Med* 1994;330:517–522
4. Ridker PM, Hennekens CH, Lindpainter K, et al. Mutation in the gene coding for coagulation factor V and the risk of myocardial infarction, stroke, and venous thrombosis in apparently healthy men. *N Engl J Med* 1995;332:912–917
5. Simioni P, de Ronde H, Prandoni P, et al. Ischemic stroke in young patients with activated protein C resistance. A report of three cases belonging to three different kindreds. *Stroke* 1995; 26:885–890
6. Ganesan V, Kelsey H, Cookson J, et al. Activated protein C resistance in childhood stroke. *Lancet* 1996;347:260 (Letter)
7. Nowak-Göttl U, Koch HG, Aschka I, et al. Resistance to activated protein C (APC) in children with venous or arterial thromboembolism. *Br J Haematol* 1996;92:992–998
8. Sugimoto T, Woo M, Nishida N, et al. When do brain abnormalities in cerebral palsy occur? An MRI study. *Dev Med Child Neurol* 1995;37:285–292
9. Dahlbäck B. Physiological anticoagulation. Resistance to activated protein C and venous thromboembolism. *J Clin Invest* 1994;94:923–927
10. Dahlbäck B, Carlsson M, Svensson PJ. Familial thrombophilia due to a previously unrecognized mechanism characterized by poor anticoagulant response to activated protein C: prediction of a cofactor to activated protein C. *Proc Natl Acad Sci USA* 1993;90:1004–1008
11. Sifontes MT, Nuss R, Jacobson LJ, et al. Thrombosis in otherwise well children with the factor V Leiden mutation. *J Pediatr* 1996;128:324–328
12. Press RD, Liu XY, Beamer N, Coull BM. Ischemic stroke in the elderly. Role of the common factor V mutation causing resistance to activated protein C. *Stroke* 1996;27:44–48
13. Lalouschek W, Suess E, Aull S, et al. Clinical and laboratory data in heterozygous factor V Leiden mutation positive versus negative patients with TIA and minor stroke. *Stroke* 1995;26: 1963–1964 (Letter)
14. Halbmayer WM, Haushofer A, Schön R, Fischer M. The prevalence of poor anticoagulant response to activated protein C (APC resistance) among patients suffering from stroke or venous thrombosis and among healthy subjects. *Blood Coagul Fibrinolysis* 1994;5:51–57
15. Marlar RA, Neumann A. Neonatal purpura fulminans due to homozygous protein C or protein S deficiencies. *Semin Thromb Haemost* 1990;16:299–309
16. Zöller B, Svensson PJ, He X, et al. Identification of the same factor V gene mutation in 47 out of 50 thrombosis-prone families with inherited resistance to activated protein C. *J Clin Invest* 1994;94:2521–2524
17. Bokarewa MI, Bremme K, Blombäck M. Arg 506-Gln mutation in factor V and risk of thrombosis during pregnancy. *Br J Haematol* 1996;92:473–478
18. Andrew M. Developmental hemostasis: relevance to thromboembolic complications in pediatric patients. *Thromb Haemost* 1995;74:415–425
19. Mandel H, Brenner B, Berant M, et al. Coexistence of hereditary homocystinuria and factor V Leiden—effect on thrombosis. *N Engl J Med* 1996;334:763–768
20. Gersell DJ. Selected vascular lesions of the placenta. *Clin Lab Med* 1995;15:611–629