

An Unusual Cause of Neonatal Seizures in a Newborn Infant

ABSTRACT. Neonatal seizures in the neonatal period are symptoms of numerous underlying disorders of the neonate. We present a case in which neonatal seizures due to cerebral infarction led to a diagnosis in the mother.

Neonatal convulsions caused by cerebral artery thrombosis is relatively rare in the neonatal period and is often secondary to indwelling intravascular catheters that cause thromboembolism, but may be associated with many conditions.¹

Cerebral artery thrombosis in newborns, in which antiphospholipid antibodies (APA) were found in the mother, has been described in three case reports.^{2,3} Two of these premature infants were born with other risk factors for thrombosis. APA could not be identified in any of these three infants. In the two cases reported by Silver et al³ the diagnosis was made several months after birth.

This case is unique in the fact that no other risk factors for thrombosis could be identified to explain the infarction, and that APA were found in the offspring of an apparently healthy mother. Whether the prior fetal death was caused by APA remains unclear. The finding of lupus anticoagulant in her child led to the diagnosis of antiphospholipid antibody syndrome in her. We believe that in case of cerebral artery thrombosis in a neonate, with no trivial cause such as an indwelling catheter or sepsis, both mother and infant should be tested for presence of APA, even when the mother seems healthy. *Pediatrics* 1997;100(4). URL: <http://www.pediatrics.org/cgi/content/full/100/4/e8>; neonate, cerebral infarction, maternal antiphospholipid syndrome.

ABBREVIATIONS. MRI, magnetic resonance imaging; LAC, lupus anticoagulant; IgG, immunoglobulin G; APA, antiphospholipid antibodies.

Neonatal seizures in the neonatal period are symptoms of numerous underlying disorders of the neonate. We present a case in which neonatal seizures due to cerebral infarction led to a diagnosis in the mother.

CASE REPORT

A 3-day-old male infant was referred to the neonatology ward because of convulsions. He was born at 39-weeks gestation, after a normal vertex delivery. His 25-year-old mother had a history of one intrauterine fetal death at 20 weeks. This pregnancy had been uncomplicated, although his mother had noticed numerous periods of subtle movements in the last 4 weeks of her pregnancy that felt different from normal fetal movements or uterine contractions and never lasted more than 2 minutes. The infant weighed 3500 g (P50), was 54 cm long

Received for publication Dec 2, 1996; accepted Feb 15, 1997.
Reprint requests to (T.W.d V.) Department of Pediatrics, Medisch Centrum Leeuwarden, Mr PJ Troelstraweg 78, 8917 CD Leeuwarden, The Netherlands.
PEDIATRICS (ISSN 0031 4005). Copyright © 1997 by the American Academy of Pediatrics.

(P90), and had a head circumference of 35 cm (P50). A few hours after birth, he started to have multiple subtle seizures manifested by repetitive blinking, smacking movements, right-sided twitching of the head and ipsilateral hand and foot. None of the seizures lasted more than 3 minutes. Neurologic examination was otherwise normal. Hematological evaluation, glucose, and electrolytes were normal. There were no signs of an intrauterine infection. An electroencephalogram showed an intermittent irritative disturbance in the left hemisphere.

An ischemic left-middle cerebral artery infarct with a minor hemorrhage could be identified on magnetic resonance imaging (MRI) (Fig 1). On additional magnetic resonance angiography no vascular aberrations of the large vessels were seen. Duplex of the carotid arteries and transcranial Doppler did not show any abnormalities. Coagulation studies revealed lupus anticoagulant (LAC) immunoglobulin G (IgG) presence, the titer being 18.9 GPL units/mL (normal ≤ 10 GPL units/mL). Anticardiolipin antibody was negative. Detection of LAC and anticardiolipin IgG was performed according to the methods described by Brandt et al.¹ Activated partial thromboplastin time and prothrombin time were both normal. Protein S, protein C activity, and antithrombin III-activity were normal for age. Factor V_{Leiden} was absent. An electrocardiogram showed no signs of heart blockage. His mother was additionally tested (6 days later) for antiphospholipid antibodies (APA) and she seemed to have an anticardiolipin IgG titer of 20 GPL units/mL (normal ≤ 10 GPL units/mL); LAC was negative.

The child was given phenobarbital on day 4. The convulsions were not seen after day 5, and no other problems were encountered. He was discharged on day 8, and is still doing well. After 1 month, he became LAC-negative. At the age of 3 months, the MRI showed an old infarct of the left middle cerebral artery with some cortical atrophy (Fig 2). At neurologic examination at the age of 1 year, no asymmetry in motor function was found and there were no signs of developmental delay.

COMMENTS

In the neonatal period, convulsions are mostly attributable to perinatal asphyxia, metabolic derangements, or infections.² Thromboembolism is a relatively rare cause of convulsions in the newborn and is often secondary to indwelling intravascular catheters,³ but may be associated with many conditions. Thromboembolism in newborns of LAC-positive mothers has been described.^{4,5} Affected women characteristically have poor pregnancy outcomes that may be improved with prednisone and low-dose aspirin treatment.⁶ Zurgil⁷ showed transplacental transfer of APA in 18 pregnant women, but in none of the cases could clinical manifestations of APA syndrome be detected. Titers of APA in affected women may fall after pregnancy. This may explain why anticardiolipin antibodies, and not LAC, could be detected in the mother at the time of determination.

Cerebral artery thrombosis in newborns, in which APA were found in the mother, has been described in three case reports.^{8,9} Two of these premature infants were born with other risk factors for thrombosis. In none of the three cases could APA be identified in the infant. In the two cases reported by Silver et al⁹ the diagnosis was made several months after birth.

This case is unique in the fact that no other risk

Fig 1. MRI image of the brain made 1 week postpartum showing edema of the left hemisphere with a small hemorrhage, corresponding with a left middle cerebral artery infarction.

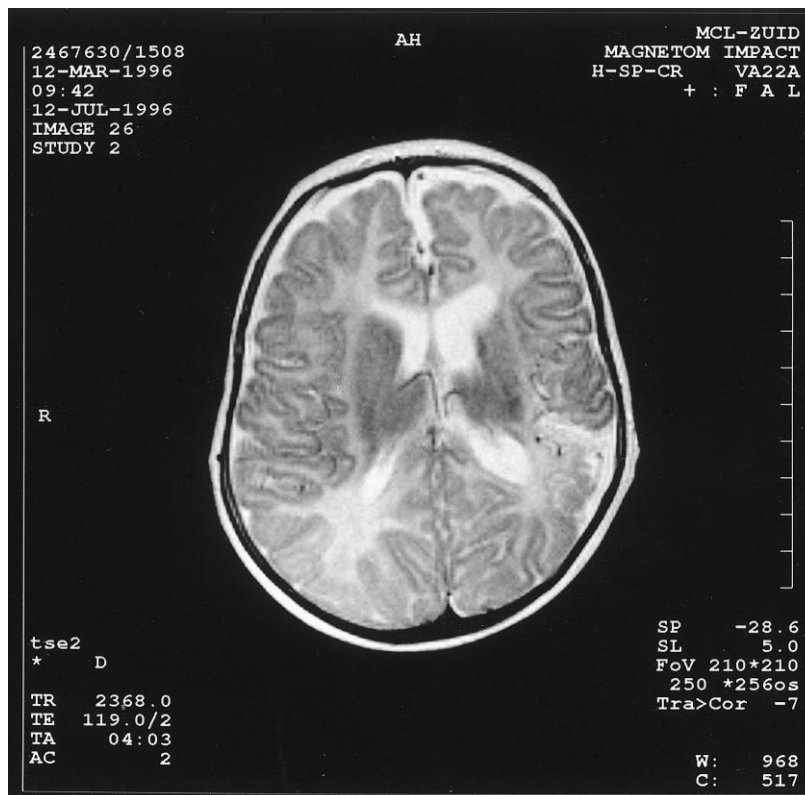
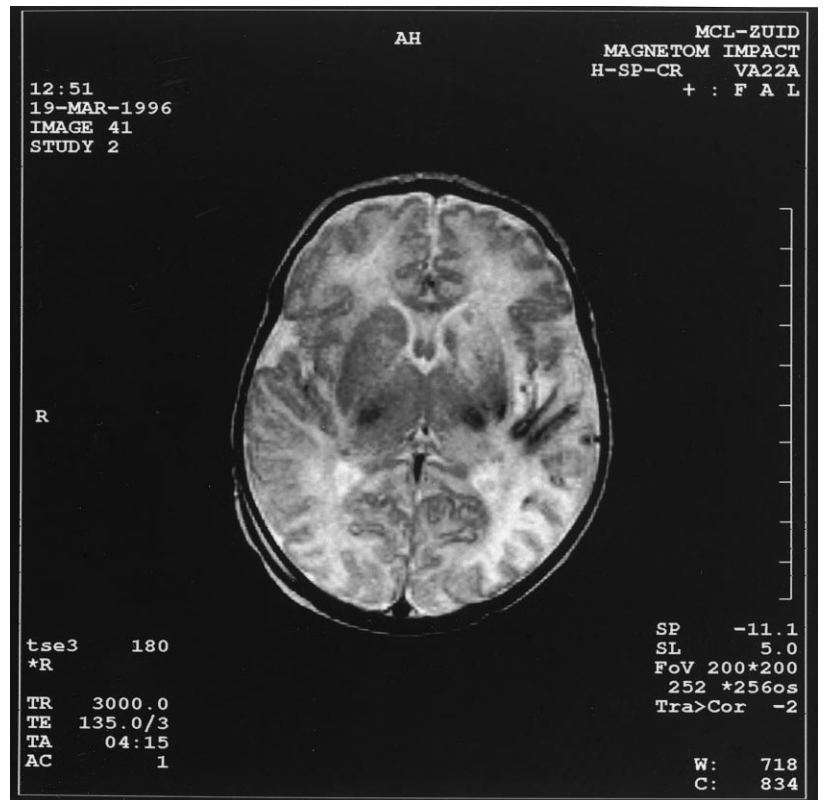


Fig 2. MRI image made at 3 months after birth showing focal cortical atrophy of the left parietal lobe, suggesting an old infarction of the left middle cerebral hemisphere.

factors for thrombosis could be identified to explain the infarction and that APA were found in the offspring of an apparently healthy mother. Whether the prior fetal death was caused by APA remains unclear. The finding of LAC in her child led to the

diagnosis of antiphospholipid antibody syndrome in her. This is comparable with diagnosing systemic lupus erythematosus in mothers of children with Ro-SSA positive congenital heart block or neonatal thrombocytopenia.¹⁰

We believe that in the case of thromboembolism in a neonate, with no trivial cause such as an indwelling catheter or sepsis, both mother and infant should be tested for the presence of APA, even when the mother seems healthy.

O. L. DE KLERK, MD
T. W. DE VRIES, MD
Department of Pediatrics
Leeuwarden Medical Centre
Leeuwarden, The Netherlands

L. G. F. SINNIGE, MD
Department of Neurology
Leeuwarden Medical Centre
Leeuwarden, The Netherlands

REFERENCES

1. Brandt JT, Barna LK, Triplett DA. Laboratory identification of lupus anticoagulant: results of the second international workshop for identification of lupus anticoagulant. *Thromb Haemost.* 1995;74:1597-1603
2. Hill A, Volpe JJ. Neurologic disorders. In: Avery GB, Fletcher MA, MacDonald MG, eds. *Neonatology: Pathophysiology and Management of the Newborn.* 4th ed. Philadelphia, PA: JB Lippincott Company; 1994: 1119-1120
3. Kotlarek F, Thron A, Weber U, et al. Der Schlaganfall beim Kind: Ätiologie, Differentialdiagnose, sinnvolle Diagnostik und therapeutische Möglichkeiten. *Klin Padiatrie.* 1993;205:332-339
4. Sheridan-Pereira M, Porreco RP, Hays T, et al. Neonatal aortic thrombosis associated with the lupus anticoagulant. *Obstet Gynecol.* 1988;71: 1016-1018
5. Finazzi G, Cortelazzo S, Viero P, et al. Maternal lupus anticoagulant and fatal neonatal thrombosis. *Thromb Haemost.* 1987;87:238
6. Lubbe WF, Butler WS, Palmer SJ, et al. Lupus anticoagulant in pregnancy. *Br J Obstet Gynaecol.* 1984;91:357
7. Zurgil N, Bakimer R, Tincani A, et al. Detection of anti-phospholipid and anti-DNA antibodies and their idiotypes in newborns of mothers with anti-phospholipid syndrome and SLE. *Lupus.* 1993;2:233-237
8. Tabbut S, Griswold WR, Ogino, MT, et al. Multiple thrombosis in a premature infant associated with maternal phospholipid antibody syndrome. *J Perinatol.* 1994;14:66-70
9. Silver RK, MacGregor J, Pasternak JF, et al. Fetal stroke association with elevated anticardiolipin antibodies. *Obstet Gynecol.* 1992;80: 497-499
10. Esscher E, Scott JS. Congenital heart block and maternal systemic lupus erythematosus. *Br Med J.* 1979;1:1235

An Unusual Cause of Neonatal Seizures in a Newborn Infant

O. L. de Klerk, T. W. de Vries and L. G. F. Sinnige

Pediatrics 1997;100:e8

DOI: 10.1542/peds.100.4.e8

Updated Information & Services	including high resolution figures, can be found at: http://pediatrics.aappublications.org/content/100/4/e8.full.html
References	This article cites 9 articles, 2 of which can be accessed free at: http://pediatrics.aappublications.org/content/100/4/e8.full.html#ref-list-1
Subspecialty Collections	This article, along with others on similar topics, appears in the following collection(s): Fetus/Newborn Infant http://pediatrics.aappublications.org/cgi/collection/fetus:newborn_infant_sub
Permissions & Licensing	Information about reproducing this article in parts (figures, tables) or in its entirety can be found online at: http://pediatrics.aappublications.org/site/misc/Permissions.xhtml
Reprints	Information about ordering reprints can be found online: http://pediatrics.aappublications.org/site/misc/reprints.xhtml

PEDIATRICS is the official journal of the American Academy of Pediatrics. A monthly publication, it has been published continuously since 1948. PEDIATRICS is owned, published, and trademarked by the American Academy of Pediatrics, 141 Northwest Point Boulevard, Elk Grove Village, Illinois, 60007. Copyright © 1997 by the American Academy of Pediatrics. All rights reserved. Print ISSN: 0031-4005. Online ISSN: 1098-4275.

American Academy of Pediatrics

DEDICATED TO THE HEALTH OF ALL CHILDREN™



PEDIATRICS®

OFFICIAL JOURNAL OF THE AMERICAN ACADEMY OF PEDIATRICS

An Unusual Cause of Neonatal Seizures in a Newborn Infant

O. L. de Klerk, T. W. de Vries and L. G. F. Sinnige

Pediatrics 1997;100:e8

DOI: 10.1542/peds.100.4.e8

The online version of this article, along with updated information and services, is located on the World Wide Web at:

<http://pediatrics.aappublications.org/content/100/4/e8.full.html>

PEDIATRICS is the official journal of the American Academy of Pediatrics. A monthly publication, it has been published continuously since 1948. PEDIATRICS is owned, published, and trademarked by the American Academy of Pediatrics, 141 Northwest Point Boulevard, Elk Grove Village, Illinois, 60007. Copyright © 1997 by the American Academy of Pediatrics. All rights reserved. Print ISSN: 0031-4005. Online ISSN: 1098-4275.

American Academy of Pediatrics

DEDICATED TO THE HEALTH OF ALL CHILDREN™

