

## NOTE

# RIGHT PERSONAL NEGLECT FOLLOWING A LEFT HEMISPHERE STROKE. A CASE REPORT

Andrea Peru<sup>1</sup> and Giampietro Pinna<sup>2</sup>

(Dipartimento di Scienze Neurologiche e della Visione, <sup>1</sup>Sezione di Fisiologia Umana, <sup>2</sup>Sezione di Neurochirurgia, Università di Verona, Verona, Italy)

## ABSTRACT

Neglect phenomena may occur in both extrapersonal and personal space. Whereas extrapersonal neglect has been found associated with both right- and left-sided brain lesions, no case of right personal neglect following a left-sided lesion has been so far reported. We describe a right-handed female patient who, after two left-hemisphere strokes, exhibited a florid personal neglect, but no extrapersonal neglect, anosognosia or somatoparaphrenia. The symptom persisted for a few weeks and then gradually disappeared. At least in the early phase of disease, a personal neglect can also be observed in patients with left brain damage.

## INTRODUCTION

Unilateral spatial neglect is far from being a unitary syndrome. One of the most puzzling fractionation of symptoms found in neglect patients concerns the spatial domains in which deficits occur (see Halligan and Marshall, 1994, for a review). In man, clinical dissociations between extrapersonal and personal neglect have been described by Bisiach and coworkers as first (Bisiach, Perani, Vallar et al., 1986b), and recently by Guariglia and Antonucci (1992). Patients affected by extrapersonal neglect fail to detect visual and auditory stimuli in the contralesional side of the space, whereas patients with personal neglect are typically unable to orient toward the contralesional hemisoma, and, in some cases, lose the perception of the contralesional half of the body (hemisomatagnosia). It is noteworthy that the terms hemisomatagnosia and personal neglect are usually taken as synonymous (see Robertson and Marshall, 1993), as if they were two aspects of a unitary syndrome, the core of which is the defective awareness of one side of the body. However, personal neglect is much less frequent than extrapersonal neglect. It follows that, while personal neglect is usually associated with extrapersonal neglect, there are a number of cases in which extrapersonal neglect occurs in the absence of personal neglect (Bisiach et al., 1986b; Pizzamiglio, Cappa, Vallar et al., 1989). They suggest the existence of two different, functionally distinct, attentional subsystems which orient attention toward personal and extrapersonal space. So far, the attempt to unravel the anatomical bases of the dissociation between personal and extrapersonal neglect has been unsuccessful, since both are almost always consequent to lesions involving the right parietal lobe.

Though, several cases of right extrapersonal neglect following left-sided lesions have been described (see Vallar, 1993, for a review), no convincing evidence of a right personal neglect following left-sided lesions has been so far provided. At least three hypotheses may account for this lack of evidence. First, De Renzi (1982) suggested that aphasic problems could preclude the discovery of neglect following left brain damage. Second, following the claim that right visuospatial neglect produced by acute left-sided lesions is as frequent, albeit less severe, as left visuospatial neglect produced by right-sided lesions (Ogden, 1987), one might argue that personal neglect occurs after lesion to either hemisphere, but resolves sooner in left brain damaged (LBD) patients than in right brain damaged (RBD) patients.

Third, if neglect is an attentional disorder, one might argue that personal neglect after left hemisphere (LH) damage would not be expected, since only the right hemisphere (RH) is specialised for orienting attention to the bodily space.

Hereafter we report a right-handed patient who suffered two LH strokes in a fifteen days period. Language disturbances were present, but did not preclude the patient from disclosing a clear right personal neglect in the absence of extrapersonal neglect, anosognosia, and somatoparaphrenia. These findings demonstrate that personal neglect may also be observed in LBD patients, at least in the acute phase, and suggest that the LH plays a role in the processing of the personal space.

#### CASE REPORT

L.D. is a 56 year-old, right-handed, female, teacher with no previous relevant illnesses. On November 6th 1995, she suddenly complained of a very severe headache followed by a transient loss of consciousness. A CT scan, performed on admission to the Neurological Department at the Hospital of Sassari, showed blood in subarachnoid spaces of the LH, as well as a small hematoma in the left insular fissure. Angiography revealed an aneurysm at the bifurcation of the middle cerebral artery. Neurological signs on hospital admission included right hemiplegia and right somatosensory loss. Anomias and phonemic paraphasias were also evident. Immediately after the onset, L.D. complained about losing her right arm, but such a symptom was so transient as to prevent any further investigation. The subarachnoid hemorrhage was initially managed in a conservative way, and the patient was scheduled for a delayed surgery protocol. On November 18th she was referred to the Neurosurgical Department at the General Hospital of Verona. Three days after admission, a rebleeding of the aneurysm occurred. A CT scan showed blood in the subarachnoid spaces and the recurrence of the left temporo-insular hematoma, but no blood deposition was detectable in the RH (see Figure 1a). Surgery took place on November 22nd. A left fronto-

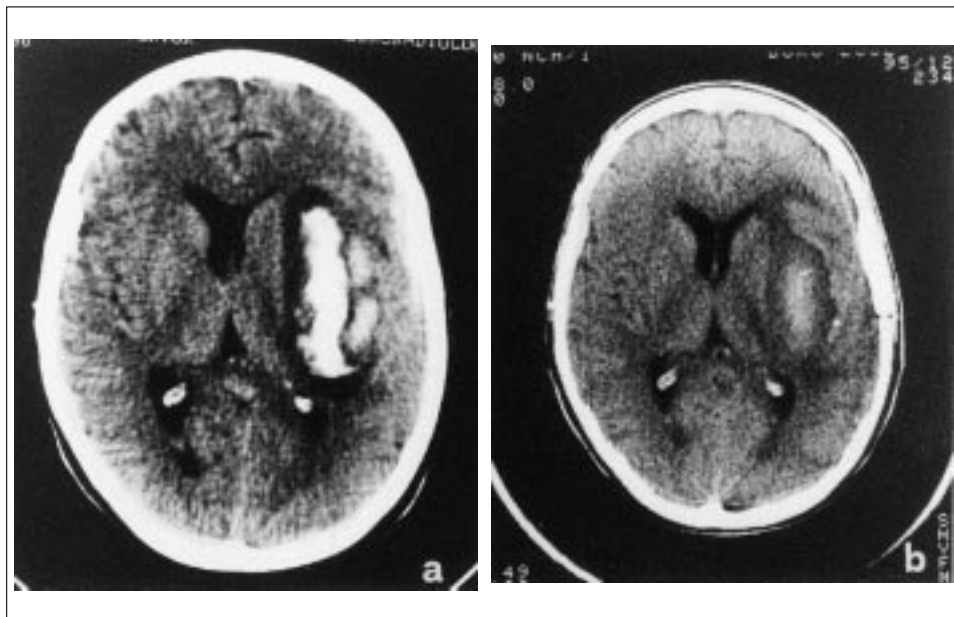


Fig. 1. – CT scans, showing LD's lesions. Blood deposition appears white and ischemic areas appear darker as compared with the brain parenchyma. The left hemisphere is represented on the right. The exams were performed at the Ospedale Maggiore, Verona, on November 21st (a) and December 13th (b), 1995. See text for details.

temporal craniotomy was performed and the aneurysm was clipped. In a control CT scan performed on December 13th (see Figure 1b), the residual blood was hardly detectable and a significant reduction of the ischemic areas around it was evident as well. On December 18th, L.D. was transferred to the Rehabilitation Unit at the Hospital of Negrar. The patient gradually improved in mobility and self care skills so, on January 28th, 1996, was discharged from the hospital. Over the next months intellectual abilities and language functions completely recovered, allowing the patient to resume social relations. However, whereas motor functions of the lower limb recovered almost completely, the right hand remained plegic, preventing L.D. to return to work.

The patient gave an informed consent to the present study.

### *Neurological Examination*

Two days after surgery, on neurological examination L.D. exhibited rightward eye, head and trunk rotation, and a marked neck stiffness. Cranial nerves I through XII were intact, except an inferior VII nerve palsy on the right. In particular, ocular movements were full, and visual field was normal on confrontation. The patient did not move her right limbs spontaneously. When asked, she was able to dorsiflex her foot and to flex her hip and knee, whereas the upper limb remained motionless, thus indicating that hemiplegia was worse in the arm than in the leg. Perception of light touch was absent in the upper limb, and only slightly impaired in the lower limb. Perception of deep pressure and joint position were present, but impaired in the upper limb, and well preserved in the lower limb. No deficit was observed in the left hemisoma.

### *Neuropsychological Evaluation*

Postoperatively, the level of alertness and the ability to concentrate fluctuated considerably, thus preventing a formal psychometric assessment of cognitive functions. In this phase, L.D. showed an instability of mood and was prone to occasional depression. She was disoriented to time, but well oriented to space and personal information. When requested to explain why she was in the hospital, L.D. promptly reported the presence of a motor deficit in the right side of the body, resulting from a cerebral hemorrhage (see Interview). Spontaneous speech was apparently fluent with some phonemic and semantic paraphasias, slight anomia, and a tendency for verbal perseveration, though no confabulation was observed. Comprehension, assessed as patients' ability to perform simple orders imparted by the examiner, turned out to be well preserved. Visual perception, assessed as patient's ability to name several objects shown by the examiner, was unimpaired. The patient had no problem in recognizing relatives and people from the hospital staff. Amnesia for the events of the recent past was present, but no other mnesic deficits became evident. A certain impairment of frontal lobe functions was suggested by L.D.'s verbal perseverations, and by her poor performance on the Verbal Fluency Test, a reliable measure of frontal lobe efficiency (score = 14; cut-off = 19.9). Finally, when assessed for hand preference by means of Briggs and Nebes's questionnaire (1975), L.D. qualified as a full right-handed subject. It is noteworthy that also her parents, her four siblings, and her two sons were right-handed.

### *Neglect Phenomena*

Immediately after surgery, L.D. spontaneously reported the experience of having lost the perception of her right arm (see Interview) and of feeling like an amputee. She never expressed the belief that her plegic limb belonged to someone else and promptly recognized it when the arm was shown her by the examiner. Nevertheless, a few minutes after the right arm was removed from vision, she again claimed that she could not find it. Two days after surgery, to assess personal neglect, we asked L.D. to touch different parts of her body with the unaffected hand. Patient's performance was scored on a four point scale (maximum score = 3; minimum score = 0) according to the procedure suggested by Bisiach and coworkers (Bisiach, Vallar, Perani et al., 1986a). L.D. promptly and accurately reached all

the targets (i.e., ear, eye, nose, shoulder, hip) on both sides of her body (score = 3), but was always unsuccessful in reaching her right arm and hand. When requested to touch the right arm, she always reached the shoulder, as if the arm did not exist. However, she easily acknowledged her mislocalisation, but was unable to correct it spontaneously. Only after the examiner focused her attention on the spatial relationship between the shoulder and the arm, she eventually moved, although with hesitation, from the former to the latter (score = 1). L.D. experienced the feeling of having lost the perception of her right arm for about two weeks, then progressively recovered. L.D.'s performance on personal neglect test paralleled the amelioration of spontaneous feelings and, by the time she was transferred to the Rehabilitation Unit, she was able to reach her right arm and hand without search.

In contrast, L.D. never failed to orient toward and detect all the auditory or visual stimuli presented in her right hemisphere. For instance, she never missed the food on the right side of the plate, and she promptly oriented toward people addressing her from the right. Presented with the Cancellation Test (Albert, 1973), L.D. started the barrage from the left upper corner and performed errorless, thus confirming the absence of extrapersonal neglect. Tactile extinction was tested by delivering a random sequence of unilateral or bilateral light touches to the back of the hands. For 10 trials, stimuli were unilateral (five trials for each hand); for the remaining 10 trials, they were bilateral. L.D. omitted all the single and double tactile stimuli delivered to the right hand. However, since the selective effects of hemianesthesia have not been disambiguated from those of neglect, it is likely that sensorial deficit contribute to the patient's overall performance.

Visual extinction was examined by using a sequence of 10 unilateral finger twitches in either visual hemifield and 10 bilateral finger twitches. L.D. detected all the visual stimuli presented on her right hemisphere, both unilateral and bilateral.

#### *Interview*

This interview took place two days post surgery.

*L.D.:* I've lost my right arm.

*Examiner:* What do you mean, exactly?

*L.D.:* I can't find it.

*Examiner:* So, where do you think your arm is?

*L.D.:* I don't know.

*Examiner:* Try to touch your right arm with your left hand.

*L.D. (reaching her right shoulder):* Here it is.

*Examiner:* Are you sure that that is your arm?

*L.D.:* No it isn't. It's my shoulder.

*Examiner:* So, touch your arm.

*L.D.:* I can't find it.

*Examiner:* You found your shoulder, where do you think your arm is?

*L.D.:* It is below the shoulder, I suppose.

*Examiner:* That's right. Touch it.

Finally, although with hesitation and search, L.D. moved from the shoulder to the arm.

*Examiner:* Do you know where you are?

*L.D.:* I am at the hospital, in Verona.

*Examiner:* Why are you at the hospital?

*L.D.:* I suffered a cerebral hemorrhage, I came from Sassari to undergo surgery.

*Examiner:* Can you describe which are precisely your problems?

*L.D.:* My speech is difficult and I can't move my right limbs.

#### *Discussion*

As a consequence of a left-sided lesion, L.D. exhibited a florid right personal neglect, without signs of extrapersonal neglect. This represents a novelty in the field of personal neglect. Even if several cases of paroxysmal, transient, right hemisomatognosia in the course of epilepsy or migraine have been reported (see De Renzi, 1982, for a review), this

is, to the best of our knowledge, the first description of a persistent right personal neglect following a left-sided lesion in a right-handed patient.

Data in literature demonstrate that personal neglect: (1) Is associated with a lesion of the infero-posterior parietal region, or with damage to subcortical structures such as the thalamus and the basal ganglia, the internal capsule, and the parietal subcortical white matter (Bisiach et al., 1986b; Vallar, 1983). (2) Affects the upper limb more than the lower limb, the elbow more than the shoulder, and the hand more than the elbow (Kinsbourne, 1993). (3) When occurs in absence of extrapersonal neglect is not very severe (Bisiach et al., 1986b). (4) Although is usually associated with a marked impairment of motor and somato-sensory functions and with visual field defect (VFD), its presence is surely compatible with a normal visual field (Bisiach et al., 1986b). (5) In spite of their frequent co-occurrence, anosognosia for hemiplegia, somatoparaphrenia, and hemisomatoagnosia are dissociable phenomena rather than different aspects of a unitary syndrome, and a full awareness of motor impairment is compatible both with the inability to orient toward the paretic limb, and the experience of having lost the perception of one half of the body (Frederiks, 1985; Bisiach et al., 1986a). (6) Although it is possible that personal neglect might not be detected for procedural reasons (Guariglia and Antonucci, 1992), the detection of personal neglect dissociated from extrapersonal neglect may be considered quite a rare occurrence in chronic patients (Pizzamiglio et al., 1989; Zoccolotti and Judica, 1991).

Apart from the side of lesion, findings from our case are largely consistent with these data. CT scans demonstrated a lesion involving the temporo-insular region, and the white matter around the internal capsule. The patient's ability to detect stimuli in the contralesional space, in addition to her errorless performance on a barrage test, attested the absence of extrapersonal neglect (Bisiach et al., 1986b; Rode, Charles, Perenin et al., 1992). Personal neglect was limited to the upper limb, the shoulder and the lower limb being totally spared, and was not very severe: after a verbal suggestion, L.D. moved from her shoulder and, even with search, she eventually reached her right arm and hand. Both motor and somatosensory impairments were present, but no VFD occurred. Although she complained of having lost the perception of the right upper limb, and always failed to orient toward it, L.D. never felt her limb as strange or not belonging to her, and always recognized it. In addition, she was well aware of her motor deficit. Finally, personal neglect persisted in L.D. for a few weeks, then gradually disappeared.

So far, data from the literature provide evidence that, in RBD patients, somaesthetic deficits can be due not only to sensory but also to attentional factors (Gainotti, De Bonis, Daniele et al., 1989; Vallar, Bottini, Rusconi et al., 1993; Smania and Aglioti, 1995), thus suggesting a pivotal role for the RH in orienting attention to personal space. Although a single case does not allow us to draw any definite conclusion, evidence from our case demonstrates that mechanisms for orienting attention to the contralateral side of the body lie in the LH as well as in the RH. However, it seems likely that right personal neglect following left-sided lesions resolves sooner than left personal neglect following right-sided lesions. Finally, since lateralisation of cerebral functions fluctuates considerably in women (Heister, Landis, Regard et al., 1989), one might argue that language functions, but not spatial abilities are well lateralised in this patient. Further investigation on a large number of LBD patients will shed lights on the role of the LH in the processing of the personal space.

*Acknowledgements.* We wish to thank Dr. S. Aglioti and Prof. G. Berlucchi, for their helpful comments on the manuscript. This work was supported by grants from the M.U.R.S.T. and from the Consiglio Nazionale delle Ricerche, Italy.

#### REFERENCES

- ALBERT, M.L. A simple test of visual neglect. *Neurology*, 23: 658-664, 1973.
- BISIACH, E., VALLAR, G., PERANI, D., PAPAGNO, C., BERTI, A. Unawareness of disease following lesions of the right hemisphere: anosognosia for hemiplegia and anosognosia for hemianopia. *Neuropsychologia*, 24: 471-482, 1986a.
- BISIACH, E., PERANI, D., VALLAR, G., BERTI, A. Unilateral neglect: personal and extrapersonal. *Neuropsychologia*, 24: 759-767, 1986b.

- BIGGS, G.G., NEBES, R.D. Patterns of hand preference in a student population. *Cortex*, 11: 230-238, 1975.
- DE RENZI, E. *Disorders of Space Exploration and Cognition*. New York: John Wiley, 1982.
- FREDERIKS, J.A.M. Disorders of the body schema. In J.A.M. Frederiks (Ed.), *Handbook of Clinical Neurology*. Vol. 45: *Clinical Neuropsychology*. Amsterdam: Elsevier Science Publishers B.V., 1985, pp. 373-393.
- GAINOTTI, G., DE BONIS, C., DANIELE, A., CALTAGIRONE, C. Contralateral and ipsilateral tactile extinction in patients with right and left focal brain damage. *International Journal of Neuroscience*, 45: 81-89, 1989.
- GUARIGLIA, C., ANTONUCCI, G. Personal and extrapersonal space: a case of neglect dissociation. *Neuropsychologia*, 30: 1001-1009, 1992.
- HALLIGAN, P.W., MARSHALL, J.C. (Eds.), *Spatial Neglect: Position Papers on Theory and Practice*. Hove: LEA, 1994.
- HEISTER, G., LANDIS, T., REGARD, M., HEISTER, P.S. Shift of functional cerebral asymmetry during the menstrual cycle. *Neuropsychologia*, 27: 871-880, 1989.
- KINSBOURNE, M. Orientation bias model of unilateral neglect: Evidence from attentional gradients within hemispace. In I.H. Robertson and J.C. Marshall (Eds.), *Unilateral Neglect: Clinical and Experimental Studies*. Hove: LEA, 1993, pp. 63-86.
- OGODEN, J.A. The "neglected" left hemisphere and its contribution to visuospatial neglect. In M. Jeannerod (Ed.), *Neurophysiological and Neuropsychological Aspects of Spatial Neglect*. Amsterdam: Elsevier Science Publishers B.V., 1987, pp. 215-225.
- PIZZAMIGLIO, L., CAPPÀ, S., VALLAR, G., ZOCCOLOTTI, P.L., BOTTINI, G., CIURLI, P., GUARIGLIA, C., ANTONUCCI, G. Visual neglect for far and near extrapersonal space in human. *Cortex*, 25: 471-477, 1989.
- RODE, G., CHARLES, N., PERENIN, M.-T., VIGHETTO, A., TRILLET, M., and AIMARD, G. Partial remission of hemiplegia and somatotopaphrenia through vestibular stimulation in a case of unilateral neglect. *Cortex*, 28: 203-208, 1992.
- ROBERTSON, I.H., MARSHALL, J.C. (Eds.), *Unilateral Neglect: Clinical and Experimental Studies*. Hove: LEA, 1993.
- SMANIA, N., AGLIOTTI, S. Sensory and spatial components of somesthetic deficits following right brain damage. *Neurology*, 45: 1725-1730, 1995.
- VALLAR, G. The anatomical basis of spatial hemineglect in humans. In I.H. Robertson and J.C. Marshall (Eds.), *Unilateral Neglect: Clinical and Experimental Studies*. Hove: LEA, 1993, pp. 27-59.
- VALLAR, G., BOTTINI, G., RUSCONI, M.L., STERZI, R. Exploring somatosensory hemineglect by vestibular stimulation. *Brain*, 116 (Pt 1): 71-86, 1993.
- ZOCCOLOTTI, P., JUDICA, A. Functional evaluation of hemi-neglect by means of a semistructured scale: personal extrapersonal differentiation. *Neuropsychological Rehabilitation*, 1: 33-44, 1991.

Dr. Andrea Peru, Università di Verona, Dipartimento di Scienze Neurologiche e della Visione, Sezione di Fisiologia Umana, Strada le Grazie 8; I-37134 Verona, Italy.  
E-mail: andrea@borgoroma.univr.it.

(Received 5 February 1997; accepted 27 March 1997)