

Delayed Traumatic Cerebral Aneurysm After Brain Injury

David O'Brien, Jr., MD, Michael W. O'Dell, MD, Amy Eversol, BA

ABSTRACT. O'Brien D Jr, O'Dell MW, Eversol A. Delayed traumatic cerebral aneurysm after brain injury. *Arch Phys Med Rehabil* 1997;78:883-5.

Traumatic aneurysms (TAs) are an unusual etiology for late neurological deterioration after traumatic brain injury (TBI) and represent less than 1% of all cerebral aneurysms. TAs most often are diagnosed acutely but may be delayed in presentation. To increase awareness of this serious but treatable condition when diagnosed early, we report a delayed TA after a motor vehicle accident. The patient experienced a seizure on day 46 postinjury while in rehabilitation and demonstrated persistent lethargy and hemiparesis. Neuroimaging revealed a large, ruptured left pericallosal artery TA, which was surgically clipped. The patient completed his rehabilitation course and was eventually discharged home with family. Among TBIs, TAs are associated with penetrating injuries and skull base or anterior cranial fossa fractures. Associated mortality is high, especially if rupture has occurred. Although TAs are rare, the clinician should be vigilant in the at-risk patient.

© 1997 by the American Congress of Rehabilitation Medicine and the American Academy of Physical Medicine and Rehabilitation

THERE ARE SEVERAL causes for late neurological deterioration in persons with traumatic brain injury (TBI), including the development of intracranial post-traumatic aneurysms (TAs). TAs are uncommon, representing less than 1% of all intracranial aneurysms.^{1,2} TAs appear to be relatively more common in children than adults.^{3,4} Approximately 250 cases of TAs have been reported in the literature, 23% in children 18 years old or younger.⁵ They are seen three times more often in males than females, reflecting the increased incidence of head trauma in males.⁶

TAs usually present acutely associated with intracranial hemorrhage but may present weeks to years after head trauma.⁷⁻⁹ They can potentially occur with any type of traumatic head injury and manifest in a variety of ways. To increase awareness of this serious but treatable condition, we present an indisputable case of a delayed TA and outline associated clinical findings and likely risk factors involved.

CASE REPORT

A previously healthy 23-year-old man was riding on the roof of a car ("car surfing") which was involved in a collision; he was thrown onto the pavement. His initial Glasgow Coma Score was 3. Initial computed tomography (CT) of the brain showed

a right frontal contusion and possible subarachnoid hemorrhage (SAH). The presence of subarachnoid blood prompted a subsequent cerebral angiogram, which indicated no signs of an aneurysm or any causes for the SAH other than trauma (fig 1). On day 4 after injury, repeat CT showed worsening cerebral edema with midline shift. Because of elevated intracranial pressures, the patient underwent a right frontotemporal lobectomy.

On day 7 postinjury, he was transferred to our rehabilitation unit at Rancho Los Amigos Level of Cognitive Function IV (agitated). He continued to show progressive functional improvement until day 46 postinjury, when he experienced a seizure with persistent lethargy and hemiparesis. CT of the brain showed a large intraventricular hemorrhage with midline shift (fig 2). Subsequent cerebral angiogram revealed a large, left pericallosal artery aneurysm not shown by the initial angiogram (fig 3). He underwent successful neurosurgical clipping and returned to rehabilitation, where he progressed well (fig 4). He was discharged home with his family 76 days after injury.

DISCUSSION

Histologically, TAs can be classified as true, false, mixed, and dissecting. False types are the most common^{6,7,10} and involve complete laceration of the arterial wall. A subsequent perivascular hematoma undergoes cavitation and a false lumen develops. True aneurysms develop secondary to intimal disruption, which produces local vessel wall weakening with subsequent aneurysm formation. Mixed aneurysms are true aneurysms that rupture and form a false aneurysm outside the true one. Dissecting aneurysms result from intimal injury with subsequent hemorrhage into the vessel wall.

The development of a TA in most cases is related to direct arterial wall injury against an adjacent skull fracture. Penetrating injuries, especially knife wounds at the base of the neck or through the orbit, can result in direct arterial damage and subsequent TA formation. Unlike stab wounds, high velocity missile injuries infrequently result in TAs.^{6-9,11}

A majority of TAs are of the false type and associated with basilar skull fractures and fractures involving the anterior cranial fossa.^{7,11} Unlike congenital aneurysms, most TAs are not related to arterial branching points but are usually located in the superficial circulation and often involve the internal carotid artery (ICA). Of 94 cases of TAs reviewed by Yokota and colleagues,¹² 46% were located on distal middle cerebral artery branches, 38% on anterior cerebral artery branches (most distal to the anterior communicating artery), and 7% involved the ICA. Other authors, however, have shown the ICA to be involved in as many as 48% of cases, most often involving the intracavernous segment.^{9,13} TAs involving the ICA sometimes result in fistula formation with sphenoid sinus extension which can present as massive epistaxis appearing months to years after injury. This type of TA is usually nonfatal, but recurrent epistaxis is expected, with mortality reaching 30% to 50% if diagnosis and treatment is not undertaken.^{6,7,9,14,15}

In contrast to the location of most TAs, our case illustrates the delayed development of a pericallosal artery TA (PCTA). PCTAs are usually false aneurysms that occur infrequently and often go unrecognized. They arise with high-velocity, rapid-deceleration head injuries, occur near the falcine edge unrelated

From the Department of Physical Medicine and Rehabilitation, University of Cincinnati College of Medicine, and Brain Injury Rehabilitation Programs, DrakeCenter, Inc., Cincinnati, OH.

Submitted for publication March 18, 1996. Accepted in revised form January 2, 1997.

A commercial party with a direct or indirect interest in the subject matter of this article has conferred or will confer a financial benefit upon one or more of the authors.

Reprints requests to Michael W. O'Dell, MD, 5161 Medical Science Building, Mail Location 530, 231 Bethesda Avenue, Cincinnati, OH 45267-0530.

© 1997 by the American Congress of Rehabilitation Medicine and the American Academy of Physical Medicine and Rehabilitation
0003-9993/97/7808-3948\$3.00/0

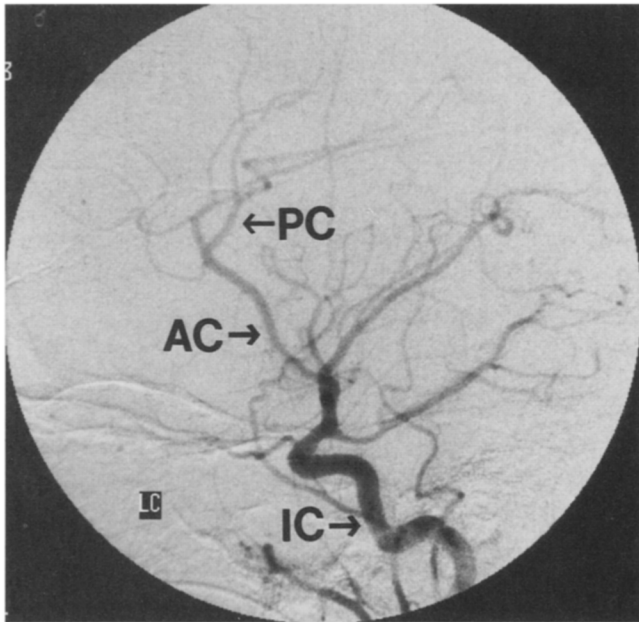


Fig 1. Initial angiogram on day of injury showing no evidence of aneurysm or hemorrhage (IC, internal carotid artery; AC, anterior cerebral artery; PC, pericallosal artery).

to arterial branching points, and often present as delayed, acute intracerebral bleeding.^{6,7} Presumably, sudden brain and arterial movement results in vessel wall injury against the stationary edge of the falx, thus creating a nidus for aneurysm development.^{16,17} As our case demonstrates, PCTAs are not necessarily associated with skull fractures, in contrast to most TAs.

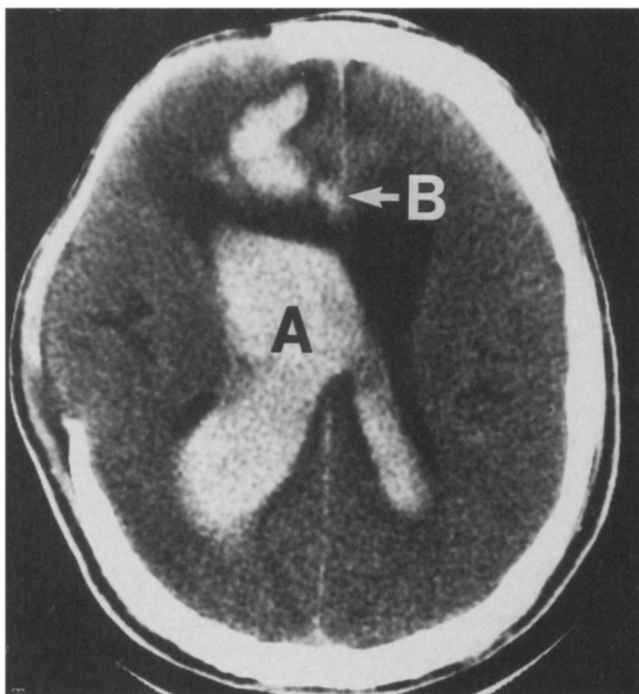


Fig 2. CT of the brain on day 46 postinjury after new onset seizures and hemiparesis showing a large intraventricular hemorrhage (A). The arrow at B indicates area of the aneurysm.

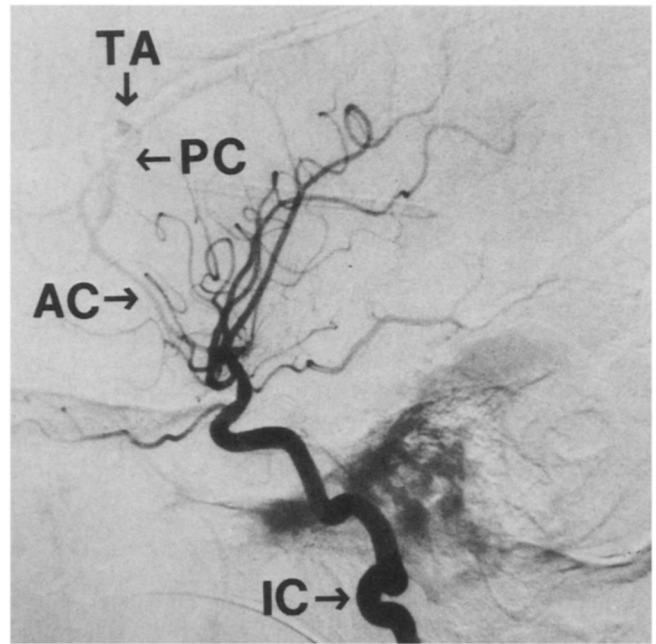


Fig 3. Presurgical angiogram showing a large left pericallosal artery traumatic aneurysm (TA) as the etiology of the patient's clinical deterioration (IC, internal carotid artery; AC, anterior cerebral artery; PC, pericallosal artery).

In general, TAs manifest in numerous ways. Presenting signs and symptoms result from the expanding aneurysm with associated mass effect, hemodynamic changes, or hemorrhage (table 1.) Unlike the PCTA in this case, Maurer's triad of unilateral blindness, orbital fracture, and massive epistaxis should alert the physician to the possibility of an intracavernous TA of the ICA with sphenoid sinus extension.¹⁸

Although TAs are rare, they are potentially devastating lesions with overall mortality rates ranging from 20% to 30%.^{12,15,19} After overt hemorrhage, the mortality rate is approximately 50%, compared with 16% when the TA is found incidentally before rupture.^{7,12,15} The mortality rate in operatively treated patients is between 10% to 20%, compared with approximately 40% for those treated nonoperatively, underscoring the need for early identification and appropriate referral.^{7,12,15}

In summary, we report an indisputable case of TA, confirmed by pre- and post-aneurysm angiography, as a cause of late neurological deterioration during rehabilitation of a TBI. TAs can

Table 1: Presenting Signs and Symptoms for Traumatic Cerebral Aneurysms

Progressive cranial nerve palsy
Enlarging or bulging skull fracture
Recurrent, massive epistaxis
Unilateral visual loss
Progressive exophthalmos and chemosis
Cranial bruits
Headache
Delayed neurologic deterioration (eg, new onset seizures, change in mental status, progressive hemiparesis, etc)
Delayed intracerebral bleeding
Extensive intracerebral blood after minor head injury
Unusual distribution of blood on initial CT of the brain
Unexplained, major arterial bleeding during evacuation of a cerebral hematoma
Discrepancy between amount of subarachnoid or intraventricular blood and severity of brain injury on CT

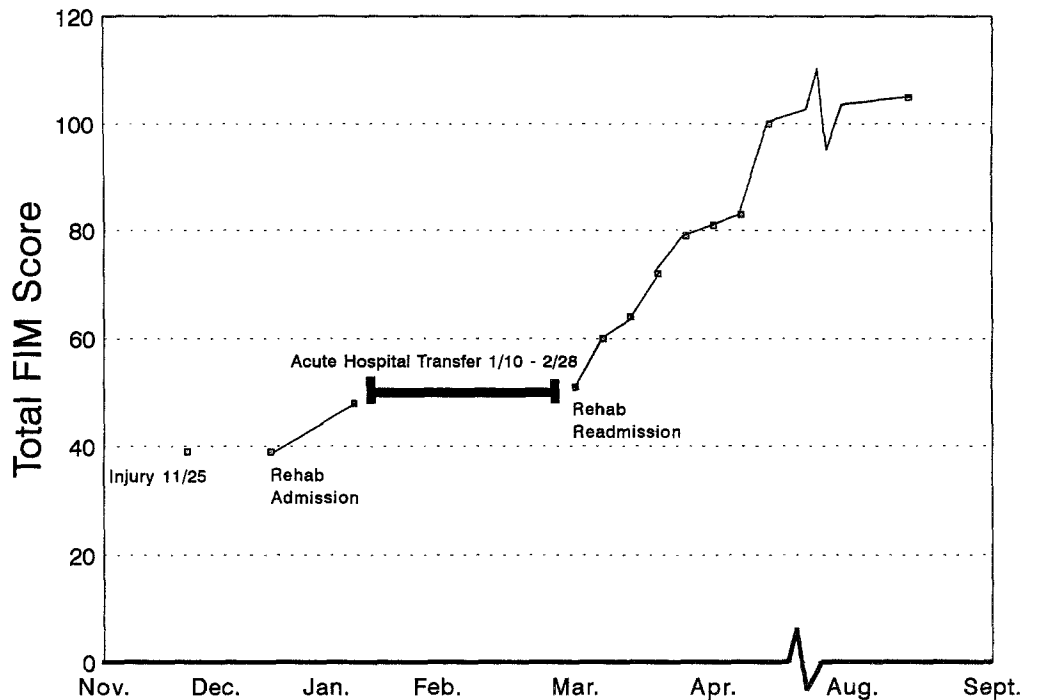


Fig 4. Functional Independence Measure scores for our patient. Data are presented for inpatient rehabilitation admissions and outpatient follow-up.

occur in mild to severe brain injury and open or closed head injuries. They tend to be associated with nonmissile penetrating injuries, fractures across the anterior cranial fossa or skull base, and acceleration-deceleration head injuries. As a TA enlarges, various signs and symptoms may present, such as recurrent epistaxis, seizures, progressive cranial nerve deficits, and an enlarging skull fracture. Radiographic evidence of intracerebral and subarachnoid bleeding should particularly alert the physician to the possibility of a TA. For patients with head trauma demonstrating characteristic signs and symptoms and in whom a high index of suspicion is held, angiography should be considered. TAs can result in delayed deterioration after head trauma, with a high rate of associated morbidity and mortality.

Acknowledgment: The authors thank Mario Zuccarello, MD, University of Cincinnati College of Medicine, Department of Neurological Surgery, for reviewing the manuscript.

References

1. Benoit BG, Wortzman G. Traumatic cerebral aneurysms: clinical features and natural history. *J Neurol Neurosurg Psychiatry* 1973; 36:127-38.
2. Laun A. Traumatic aneurysms. In: Pia HW, Langmain C, Zierski J, editors. *Cerebral aneurysms: advances in diagnosis and therapy*. Berlin: Springer-Verlag; 1979. p. 364-74.
3. Patel AN, Richardson AE. Ruptured intracranial aneurysms in the first two decades of life: a study of 58 patients. *J Neurosurg* 1971; 35:571-6.
4. Almeida GM, Pindaro J, Plese P, Bianco E, Shibata MK. Intracranial arterial aneurysm in infancy and childhood. *Childs Brain* 1977; 3:193-9.
5. Fox JL. *Intracranial aneurysms, Vol III*. New York: Springer-Verlag; 1983.
6. Takakura K, Suito I, Sasaki T. Special problems associated with

- subarachnoid hemorrhage. In: Youmans JR, editor. *Neurological surgery*. 3rd ed. Philadelphia: Saunders; 1990. p. 1864-85.
7. Buckingham MJ, Crone KR, Ball WS, Tomsick TA, Berger TS, Tew JM. Traumatic intracranial aneurysms in childhood: two cases and a review of the literature. *Neurosurgery* 1988;22:398-408.
8. Haddad FS, Haddad GF, Taha J. Traumatic intracranial aneurysms caused by missiles: their presentation and management. *Neurosurgery* 1991;28:1-7.
9. Steinmetz H, Heiss E, Mironov A. Traumatic giant aneurysms of the intracranial carotid artery presenting long after head injury. *Surg Neurol* 1988;30:305-10.
10. Jungueira LC, Carneiro J, Long JA. *Basic histology*. 5th Ed. Norwalk (CT): Appleton-Century-Crofts; 1986.
11. Becker DP, Gade GF, Young HF, Feverman TF. Diagnosis and treatment of head injury in adults. In: Youmans JR, editor. *Neurological surgery*. 3rd ed. Philadelphia: Saunders; 1990. p. 2105-6.
12. Yokota H, Tazaki T, Murayama K. Traumatic cerebral aneurysm: 94 cases from the literature and 5 cases observed by the authors. *No Shiaki Geka (Tokyo)* 1983;11:521-9.
13. Fox JL. *Intracranial aneurysms*. New York: Springer-Verlag, 1983.
14. Burton C, Velasco F, Dorman J. Traumatic aneurysm of a peripheral cerebral artery: review and case report. *J Neurosurg* 1968;28:468-74.
15. Fleisher AS, Patton JM, Tindall GT. Cerebral aneurysms of traumatic origin. *Surg Neurol* 1975;4:223-39.
16. Laurent JP, Check WR, Mims T, McCluggage CW. Traumatic intracranial aneurysm in an infant: case report and review of the literature. *Neurosurgery* 1981;9:303-6.
17. Smith KL, Bardenheier JA. Aneurysm of the pericallosal artery caused by closed cranial trauma: case report. *J Neurosurg* 1968;29: 551-4.
18. Maurer TJ, Mills M, German WJ. Triad of unilateral blindness, orbital fractures and massive epistaxis after head injury. *J Neurosurg* 1961;18:837-49.
19. Asari S, Nakamura S, Yamada O, Beck H, Sugantani H, Higashi T. Traumatic aneurysm of peripheral cerebral arteries: report of two cases. *J Neurosurg* 1977;46:795-803.