

Case Report

Migrainous Stroke Causing Thalamic Infarction and Amnesia During Treatment With Propranolol

Jorge E. Mendizabal, MD; Frank Greiner, MD; William J. Hamilton, DO; John F. Rothrock, MD

From the Departments of Neurology (Drs. Mendizabal, Hamilton, and Rothrock) and Diagnostic Radiology (Dr. Greiner), University of South Alabama College of Medicine, Mobile, Ala.

Address all correspondence to Dr. Jorge E. Mendizabal, Department of Neurology, University of South Alabama College of Medicine, Moorer Building 1101, 2451 Fillingim Street, Mobile, AL 36617.

Accepted for publication March 10, 1997.

We report a case of migraine-associated ischemic stroke causing amnesia, wherein treatment with propranolol may have been contributory. The possible mechanisms involved in migrainous stroke occurring in association with use of propranolol are discussed.

Key words: migrainous stroke, migraine, stroke, thalamic amnesia

(*Headache* 1997;37:594–596)

Stroke is a rare but recognized complication of migraine.¹ While propranolol has been incriminated by some to be a potential contributor to this complication, evidence to support that proposal has been scant. We report a case of migrainous stroke wherein treatment with propranolol was associated temporally with stroke onset and may have played a causative role.

CASE HISTORY

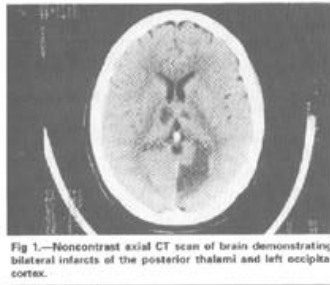
A 47-year-old woman with a long-standing history of episodic headaches characteristic of migraine presented to an emergency department for evaluation and treatment of a particularly severe and protracted migraine attack. In the past, her headaches had occurred either without accompanying aura or with symptomatology characteristic of basilar migraine: bilateral face and hand "numbness and tingling," "slurred" speech, vertigo, gait instability, and horizontal diplopia, all in varying combinations and widely variable in duration. She had been taking 80 mg per day of long-acting (LA) propranolol for migraine prophylaxis and was on estrogen supplementation therapy. She reported a history of hypertension and active cigarette use. Her examination at that time showed right beating nystagmus and gait ataxia. She was treated with intramuscular meperidine and meclizine, but failed to improve. She was instructed to continue taking LA propranolol 80 mg daily.

Her headache and associated symptoms worsened over the next 48 hours, and she was admitted to another hospital. Her examination on admission was significant for "gait ataxia on standing position with eyes closed"; she was noted to be fully oriented and cooperative. Due to persistence of headache, LA propranolol was increased to 120 mg per day. Within 24 hours following the increase in her dose of propranolol, she developed acute confusion and agitation and was transferred to the University of South Alabama Medical Center (USAMC).

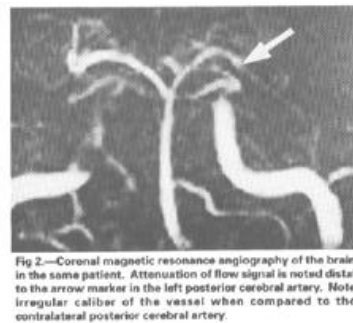
On admission at USAMC, her vital signs included a blood pressure of 155/71, heart rate of 70 beats per minute, respirations of 16 per minute, and she was afebrile. Her neurological examination showed severe stupor without obvious focal findings. Computed tomography (CT) of the brain showed bilateral infarctions of the posterior thalami, left occipital cortex, and left superior cerebellar hemisphere (Figure 1). Brain magnetic resonance imaging (MRI) confirmed these findings. Magnetic resonance angiography (MRA) demonstrated attenuation of flow signal at the level of the distal basilar and left posterior cerebral arteries (Figure 2).

Propranolol was discontinued, and she received vigorous volume expansion with intravenous normal saline solution and pharmacologic treatment with oral nimodipine 30 mg every 6 hours, dexamethasone 4 mg IV every 6 hours, and IV heparin 1000 units per hour. As her level of consciousness gradually improved over the next 72 hours, she had significant confusion and amnesia. She was discharged on warfarin (INR = 2–3) and shortly thereafter begun on divalproex

[Fig 1]



[Fig 2]



sodium 500 mg twice daily for migraine prophylaxis. At 1 month following discharge, she had improved significantly but continued to have deficiencies of short-term memory and concentration. Follow-up brain MRI performed 3 months after the initial study showed no interval change, but MRA demonstrated interval improvement in the distal basilar and left posterior cerebral arteries narrowing seen initially, with only slight tapering of flow signal in those vessels.

COMMENTS

Putative mechanisms for migraine-associated stroke include a prothrombotic state induced by platelet and coagulation abnormalities, cardioembolism associated with mitral valve prolapse, arterial dissection, and a primary migrainous arteriopathy.² While any or all of these mechanisms may contribute to migrainous stroke, angiographic evidence suggests that vasospasm is the primary cause of stroke in a significant proportion of cases.²

Beta-blockers are known to decrease cerebral blood flow, increase cerebral vascular resistance, decrease cerebral glucose metabolism, and decrease cerebral oxygen consumption.³ They also are known to have vasoconstrictive effects in the peripheral circulation and may precipitate Raynaud's phenomenon, producing claudication and gangrene.⁴ It has been proposed that propranolol may potentiate cerebral vasospasm by promoting an unopposed alpha-agonist effect on central receptors.^{3,5} Little evidence exists to support this proposal, however. Gomez et al have demonstrated that propranolol may even be beneficial in relieving migraine-induced vasospasm in the posterior circulation as documented by transcranial Doppler.⁶

Sharpe reported two cases in which initiation of treatment with propranolol for obstructive cardiomyopathy led to new onset of aura in an individual who previously had only migraine without aura.⁷ The temporal association between use of propranolol and the occurrence of migrainous infarction was reported in 1980 by Prendes in a 44-year-old with intermittent Raynaud's phenomenon and a left middle cerebral artery (MCA) infarction, both occurring several months after starting beta-blocker therapy.⁸ Gilbert described a 53-year-old woman who suffered from migraines with aura and developed a right MCA infarction 2 weeks after initiating treatment with propranolol.⁹ Katz reported migrainous ischemic retinopathy occurring after treatment with only three 20-mg doses of propranolol,⁵ and Bardwell and Trott reported a 48-year-old man with hypertension and migraine with aura who developed an infarction in the distribution of the left posterior cerebral artery 2 years after starting LA propranolol.³

In the patient reported here, the temporal association between stroke and treatment with propranolol is obvious but does not prove a causative relationship. Even so, the timing of stroke onset relative to the increase in propranolol dosage, the documentation by MRA of abnormalities consistent with vasospasm, and the cerebrovascular effects that propranolol is known or theorized to have, raise concern that this temporal association was more than coincidental. If so, clinicians might hesitate to advance propranolol dosage or continue treatment at all during a period of acute, protracted migraine, especially when the headache is accompanied by symptoms characteristic of basilar migraine.

REFERENCES

1. Tatemichi TK, Mohr JP Migraine and stroke. In: Bamett HJ, Mohr JP Stein BM, et al, eds. Stroke: Pathophysiology Diagnosis and Management. II. New York: Churchill Livingstone Inc; 1986:847–848.
2. Rothrock JF, Walicke P, Swenson MR, Lyden PD, Logan WR. Migrainous stroke. *Arch Neurol.* 1988;45:63–67.
3. Bardwell A, Trott JA. Stroke in migraine as a consequence of propranolol. *Headache.* 1987;27:381–383.
4. Svendsen TL, Jelnes R, Tonnesen KH. Is adrenergic betareceptor blockade contraindicated in patients with intermittent claudication? *Acta Med Scand Suppl.* 1985 ;693:129–132.
5. Katz B. Migrainous central retinal artery occlusion. *J Clin Neuroophthalmol.* 1986;6:69–75.
6. Gomez CR, Gomez SM, Puricelli MS, Malik MM. Transcranial Doppler in reversible migrainous vasospasm causing cerebellar infarction: report of a case. *Angiology.* 1991;42:152–156.
7. Sharpe CJ. Propranolol in the treatment of migraine. *BMJ.* 1974;34:522.
8. Prendes JL. Considerations on the use of propranolol in complicated migraine. *Headache.* 1980;20:93–95.
9. Gilbert GJ. An occurrence of complicated migraine during propranolol therapy. *Headache.* 1982;22:81–83.