

Kuniaki Tsuchiya · Kenji Ikeda · Toshiki Uchihara
Tatsuro Oda · Hiroyuki Shimada

Distribution of cerebral cortical lesions in corticobasal degeneration: a clinicopathological study of five autopsy cases in Japan

Received: 3 February 1997 / Revised: 14 April 1997 / Accepted: 2 May 1997

Abstract We investigated five Japanese patients with autopsy-proven corticobasal degeneration (CBD) both clinically and pathologically, and examined the distribution of their cerebral cortical lesions in hemisphere specimens. The lesions were classified into three categories (slight, moderate and severe). Only two of our patients had clinical features considered to be typical of CBD. Severe lesions were present in the posterior portions of the frontal lobe, anterior to the precentral gyrus in two patients with the clinical diagnosis of CBD. By comparison, in two patients with clinically diagnosed frontal Pick's disease, and one with the clinical diagnosis of progressive supranuclear palsy (PSP), severe lesions were seen in the anterior portions of the frontal lobe. The primary motor area of all five had mostly slight to moderate lesions. We postulate that the clinical features of CBD have a much wider spectrum than previously believed. Our data also indicate that the lesion responsible for limb-kinetic apraxia in CBD is in the premotor cortex. We suggest that when the anterior portions of the frontal lobe are damaged, the clinical picture mimics those of Pick's disease and PSP. In addition, we consider that focal cerebral atrophy of CBD is multicentric.

Key words Cerebral cortical lesion · Clinicopathological correlation · Corticobasal degeneration · Pick's disease · Progressive supranuclear palsy

Introduction

Corticobasal degeneration (CBD), first described by Rebeitz et al. [20, 21] as corticodentatonigral degeneration with neuronal achromasia, is a progressive neurodegenerative disorder that affects the cortical and subcortical systems [8, 22]. The main clinical characteristics of CBD are apraxia, cortical sensory loss, alien limb, dementia, oculomotor abnormalities, dysarthria, postural instability, akinesia, rigidity, and pyramidal signs. The major neuropathological hallmarks of the disease are a characteristic cortical degenerative process with many ballooned neurons, and neuronal loss with gliosis in the substantia nigra [12]. Recently it has been suggested that there is clinical heterogeneity in CBD [3]. It has become increasingly apparent that there is pathological heterogeneity of disorders with similar clinical phenotype. For example, frontotemporal dementia has been described to be due to CBD, Pick's disease, motor neuron disease-type dementia, dementia of frontal type, and Alzheimer's disease [11]. The distinctive cerebral cortical features of CBD is limb-kinetic apraxia [7, 13], generally believed to be due to a lesion in the paracentral region [13]. The cerebral lesions of CBD are considered to be conspicuous in the precentral and postcentral gyri, hence the limb-kinetic apraxia has been attributed to lesions of these gyri.

The purpose of this report is to describe clinical and pathological findings on five Japanese patients with autopsy-proven CBD, and to delineate the multiplicity of clinical features of this disorder. We also provide a detailed distribution of the cerebral cortical lesions of CBD based on histological examination, and consider that the lesion responsible for limb-kinetic apraxia is present in the premotor cortex. In addition, we also address the clinicopathological correlation between the clinical signs that mimic Pick's disease [19, 27] and progressive supranuclear palsy (PSP) [26], and the presence of moderate to severe lesions in the anterior portion of the frontal lobe. To our knowledge, no similar study has been performed before.

K. Tsuchiya (✉) · H. Shimada
Department of Pathology, Tokyo Medical College,
6-1-1 Shinjuku, Shinjuku-ku, Tokyo 160, Japan
Tel.: 81-3-3351-6141; Fax: 81-3-3354-3780

K. Tsuchiya · K. Ikeda
Department of Neuropathology,
Tokyo Institute of Psychiatry, Tokyo, Japan

T. Uchihara
Department of Neurology,
Tokyo Medical and Dental University, Tokyo, Japan

T. Oda
Department of Psychiatry,
National Shimofusa Sanatorium, Chiba, Japan

Materials and methods

Cases

The present investigation was carried out on five autopsy cases whose clinical records and tissue specimens are stored in the Department of Neuropathology, Tokyo Institute of Psychiatry (case 1, no. 94084; case 2, no. 92008; case 3, no. 91053; case 4, no. 95029; case 5, no. 93013).

After fixation in formalin, the brains of cases 1, 2, 3 and 5 were sectioned in the coronal plane, and that of case 4, in the horizontal plane. Cerebral hemispheric blocks including the frontal lobe, parietal lobe, temporal lobe, occipital lobe, striatum, pallidum, subthalamic nucleus, thalamus, amygdala, and hippocampus were taken in both hemispheres. For case 1, nine cerebral hemispheric blocks were taken; for case 2, five; for case 3, seven; for case 4, five; and for case 5, four. Additional tissue blocks were taken from the midbrain including substantia nigra, brain stem, and cerebellum. The brains were embedded in paraffin and cut to a thickness of 10 μm . The sections were stained with hematoxylin-eosin (H&E), and by the Klüver-Barrera (KB), Holzer, Bodian, and modified Gallyas-Braak methods [1, 4, 10].

The neuropathological diagnosis of CBD in the five cases was made on the basis of the findings described in the Results section, which included many astrocytic plaques [6] in the cerebral cortex and the widespread presence of argyrophilic threads [9] in the central nervous system. The neuropathological features of all five are fundamentally consistent with the pathological criteria of CBD of Feany and Dickson [6] and the recently proposed NINDS criteria [14].

The clinicopathological findings on cases 1, 2, 3, and 5 have been reported previously by Tsuchiya et al. [28], Oda et al. [16], Mitani et al. [15], and Oda et al. [17], respectively. The neuropathological characteristic of case 3, including abnormal cytoskeletal pathology peculiar to CBD was also described by Uchi-hara et al. [29]. The clinical and pathological features of case 4 are described in this report.

Case 4

Clinical course

The patient was in good health until August 1989, when at the age of 58 years she developed abnormal behavior. There was no family history of neurological disease with dementia and parkinsonism. Two months later, lack of spontaneity became apparent. At the age of 59, iteration appeared, such as buying the same type of food every day in large quantities. She could not do any housework after March 1991. Change in taste such as smoking appeared in May 1991. She was bed-ridden after 1992, and died in March 1993, at the age of 62 years. During the course of her illness, limb-kinetic apraxia and parkinsonism, including muscular rigidity and akinesia were not observed. The total duration of the illness was 3 years and 7 months, and the clinical diagnosis was frontal Pick's disease.

Neuropathological findings

The weight of the brain was 987 g. The macroscopic examination revealed atrophy of the bilateral frontal lobes. The atrophy of the gyri orbitales was more marked on the right than on the left. The histological examination disclosed neuronal loss with astrocytosis, status spongiosus, and numerous ballooned neurons in the cerebral cortex of the frontal lobes (Fig. 1a). Neuronal loss with astrocytosis was evident in the striatum, pallidum, thalamus, substantia nigra, and dentate nucleus. There were corticobasal inclusions in the substantia nigra. Neither Pick bodies nor senile plaques were seen in the cerebral cortex or the hippocampus. Modified Gallyas-Braak method showed many argyrophilic threads in the central nervous

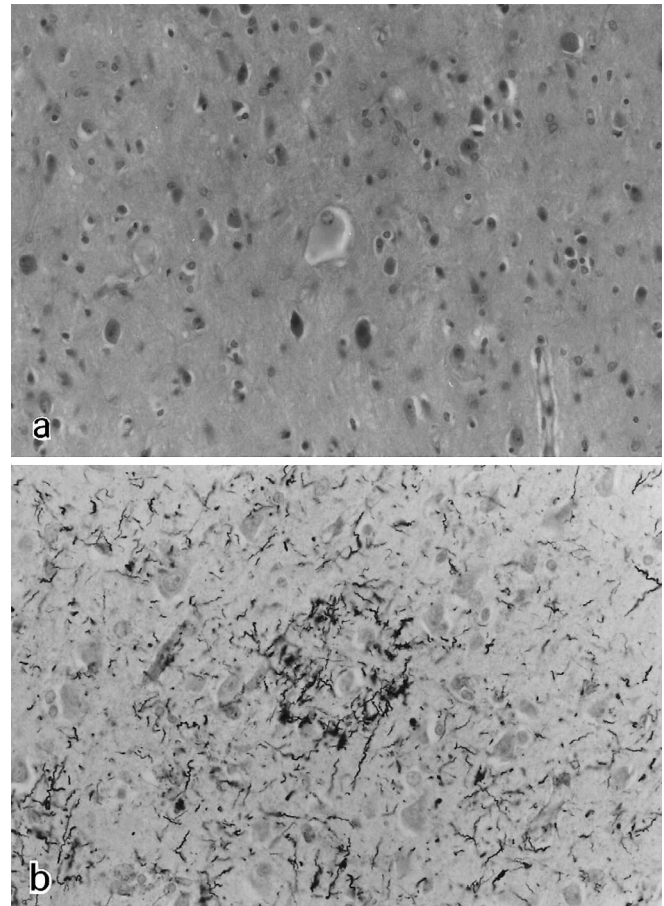


Fig. 1a, b Neuropathological findings on case 4. **a** Ballooned neuron in the frontal cortex. H&E stain. **b** Astrocytic plaque and many argyrophilic threads in the frontal cortex. Modified Gallyas-Braak stain. **a** $\times 150$, **b** $\times 225$

system, and numerous astrocytic plaques in the cerebral cortex (Fig. 1b).

Classification of cerebral cortical lesions

The lesions identified by light microscopy were classified into three categories: slight, slight neuronal loss and gliosis of the superficial layers; moderate, obvious neuronal loss with gliosis of the second and third layers, often accompanied by status spongiosus and relative preservation of the neurons of the fifth and sixth layers; or severe, pronounced neuronal loss with gliosis of the second to sixth layers (Fig. 2). The primary motor area, including Betz cells, was identified on the hemisphere specimens of the five cases. The data obtained for each patient are depicted schematically in Figs. 3–7.

Results

Clinical features

The main clinical information on the five patients is summarized in Table 1. There were two males and three females. None of them were related. None of patients included in this study had a family history of neurological

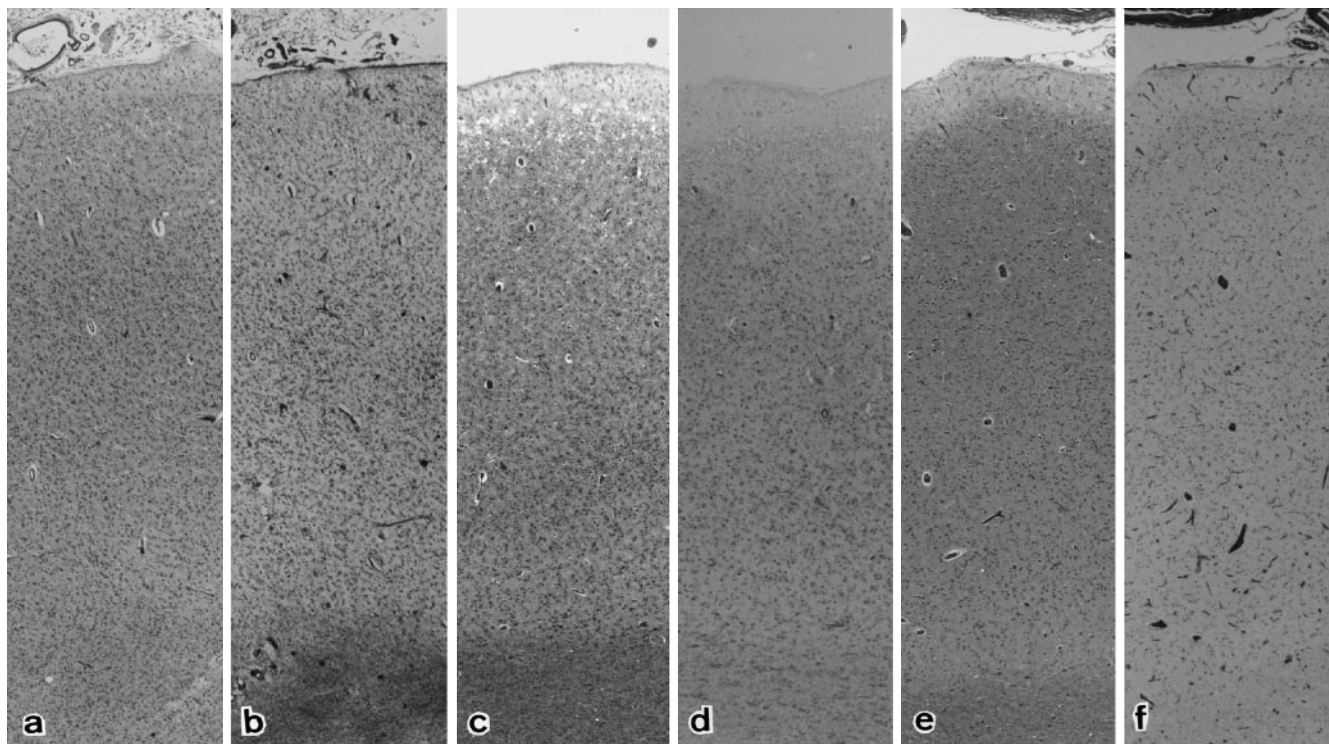


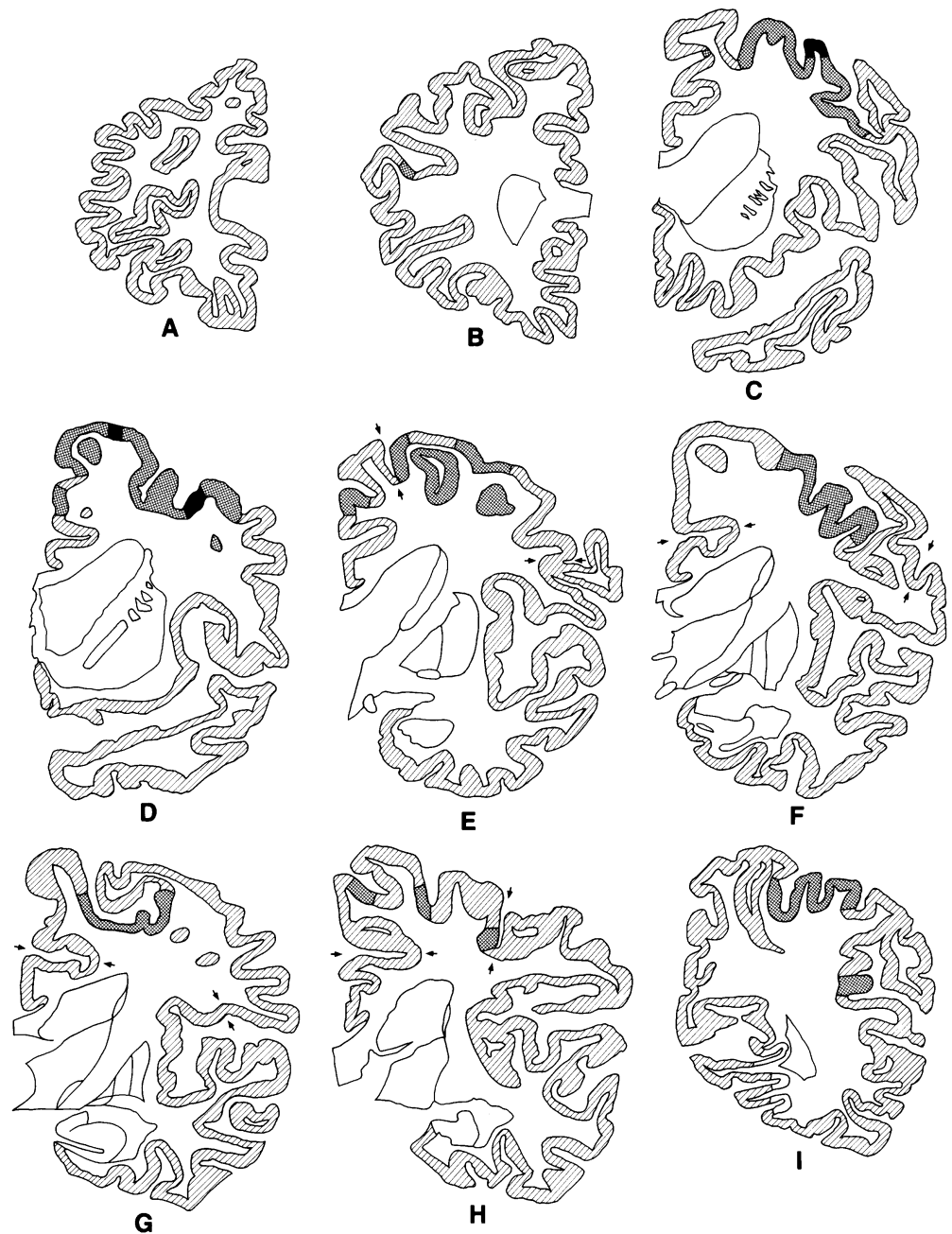
Fig. 2 Neuronal loss and gliosis in the frontal cortex (**a, b** from case 5; **c, d** from case 3; **e, f** from case 1). **a** Severe: Pronounced neuronal loss of the second to sixth layers. H&E stain. **b** Severe: Prominent gliosis of the cerebral cortex with marked fibrillary gliosis of the white matter. Holzer stain. **c** Moderate: Obvious neuronal loss of the second and third layers accompanied by status spongiosis and relative preservation of neurons of the fifth and sixth layers. H&E stain. **d** Moderate: Obvious gliosis of the cerebral cortex with slight fibrillary gliosis of the white matter. Holzer stain. **e** Slight: Slight neuronal loss of the superficial layers. H&E stain. **f** Slight: Slight gliosis of the superficial layers. Holzer stain. **a-f** $\times 21$

disease with dementia and parkinsonism. The age at onset of symptoms varied between fifth and seventh decades of life, with the average being 63.6 years. The duration of the disease ranged from 25 months in case 1 to 8 years in case 2; the mean duration was 4 years and 11 months. Only cases 1 and 3 showed limb-kinetic apraxia as the initial sign; the other three showed psychiatric signs, including delusion of persecution and abnormal behavior. Dementia was noted in all patients. Oculomotor abnormalities were evident in cases 1, 2, and 3. Vertical gaze palsy was observed in three patients. In case 2, who was diag-

Table 1 Summary of clinical and pathological features (*M* male, *F* female, + present, – absent, *CBD* corticobasal degeneration, *PSP* progressive supranuclear palsy)

Case	1	2	3	4	5
Sex	M	F	M	F	F
Heredity	–	–	–	–	–
Age at death (years)	67	53	67	62	69
Duration of the disease	2 years 1 month	8 years	3 years 10 months	3 years 7 months	7 years
Initial signs	Limb-kinetic apraxia	Delusion of persecution	Limb-kinetic apraxia	Abnormal behavior	Abnormal behavior
Limb-kinetic apraxia	+	–	+	–	–
Personality changes	+	+	–	+	+
Dementia	+	+	+	+	+
Oculomotor abnormalities	+	+	+	–	–
Muscular rigidity	+	+	+	–	+
Involuntary movements	Tremor	Tremor	Tremor	–	–
Pyramidal sign	+	+	+	–	+
Clinical diagnosis	CBD	PSP	CBD	Pick's disease (frontal type)	Pick's disease (frontal type)
Brain weight (g)	1370	1050	1040	987	940
Asymmetric atrophy of the cerebrum	+	–	+	+	–

Fig. 3 Distribution of cerebral cortical lesions of case 1. The lesions are classified into three categories: slight (▨), moderate (▩), severe (■). Normal cerebral cortex is also depicted (□). The primary motor areas are between the arrows. The right side of the brain is on the right of the photograph



nosed as having PSP, downward gaze palsy was evident. Muscular rigidity was evident in four cases. The clinical diagnosis of two patients was CBD, that of one, PSP and that of the remaining two, frontal Pick's disease.

Neuropathological findings

The weight of the patients' brain ranged from 940 to 1370 g (average: 1077 g) (Table 1). Neuronal loss with many ballooned neurons and gliosis was evident in the cerebral cortex of all cases; asymmetric atrophy of the cerebrum was obvious in three (Table 1). Loss of neurons with gliosis was found in the striatum, pallidum, thalamus, sub-

stantia nigra, and dentate nucleus of all five. Corticobasal inclusions in the substantia nigra was also present in the five cases. Staining by the modified Gallyas-Braak method revealed the widespread presence of argyrophilic threads in the central nervous system and many astrocytic plaques in the cerebral cortex of the five patients.

Distribution of cerebral cortical lesions

The data obtained are schematized in Figs. 3–7. In case 1, whose initial sign was limb-kinetic apraxia and who was clinically diagnosed as having CBD, we found severe lesions in the posterior portions of the frontal lobe, includ-

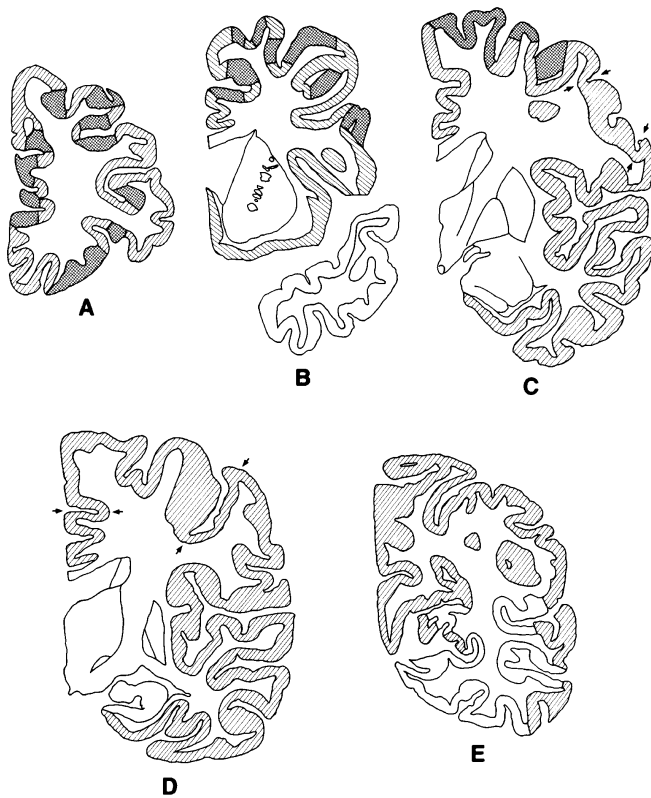


Fig. 4 Distribution of cerebral cortical lesions of case 2. For details see Fig. 3

ing the premotor area, anterior to the precentral gyrus (area 6 after Brodmann) (Fig. 3C, D). His primary motor area had slight to moderate lesions (Fig. 3E–H). Moderate lesions were seen in the anterior portions of the frontal lobe of case 2, who exhibited delusion of persecution as the initial sign and was diagnosed as having PSP (Fig. 4A–C). The primary motor area of this patient showed slight lesions (Fig. 4C, D). Case 3, who presented limb-kinetic apraxia as initial sign and was clinically diagnosed as CBD, had severe lesions in the posterior portions of the frontal lobe and in the anterior portions of the parietal lobe (areas 1–7 after Brodmann) (Fig. 5C–G). The lesions in the primary motor area of this patient were mostly moderate (Fig. 5C–F). Obvious severe lesions were found in the anterior portions of the frontal lobe of case 4, whose initial sign was abnormal behavior and whose clinical diagnosis was frontal Pick's disease (areas 6, 8, 9, and 44–46 after Brodmann) (Fig. 6A–D); the lesions in the primary motor area were slight to moderate (Fig. 6A, B). Case 5, who had the same initial sign and clinical diagnosis as case 4, had severe lesions in the anterior portions of the frontal lobe (areas 6, 8, 9, and 45–47 after Brodmann) (Fig. 7A–C). The lesions in the primary motor area of this patient were slight to moderate (Fig. 7D).

Clinicopathological correlations

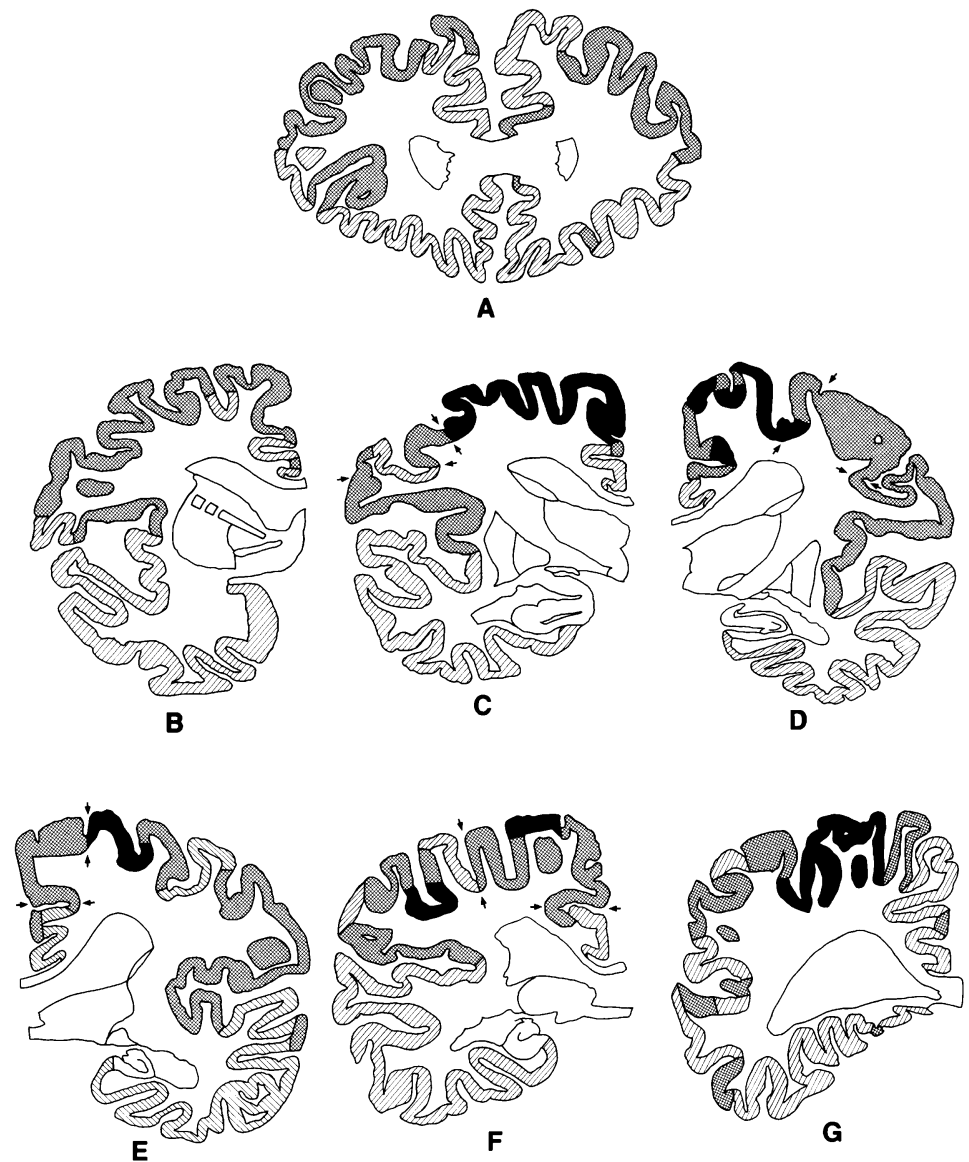
Only the two patients who presented limb-kinetic apraxia as initial sign, followed by parkinsonism and dementia, were clinically diagnosed as having CBD. Both had severe lesions chiefly in the posterior portions of the frontal lobe, including the premotor area, anterior to the precentral gyrus. By contrast, in the three other patients, moderate to severe lesions were evident in the anterior portions of the lobus frontalis.

The clinical and pathological data indicated above suggest that the lesion responsible for limb-kinetic apraxia in CBD is present in the premotor area. Our results also lead us to believe that when the anterior regions of the frontal lobe are damaged, the resulting clinical picture mimics those of frontal Pick's disease and PSP, and that when the main damage is in the posterior portions of this lobe, the clinical picture is typical of CBD.

Discussion

The characteristic clinical features of CBD were thought to be asymmetric motor disturbance with cortical sensory loss and apraxia without marked cognitive dysfunction, supranuclear gaze palsies, parkinsonism, and involuntary movements [12]. However, despite these criteria, it is very difficult to make a clinical diagnosis of CBD. For instance, of the three autopsy cases of CBD reported by Gibb et al. [8], no definite clinical diagnosis could be made for one, and PSP was suspected in the other two. Moreover, an autopsy case of PSP that was clinically diagnosed as CBD has been reported recently [25]. Even though Rebeiz et al. [20, 21] indicate in their original report that mental ability was surprisingly intact until the late stages of the disease, several autopsy cases of CBD presenting initially with dementia have been recorded [3, 5, 18, 23, 30]. Paulus and Selim [18] reported an atypical autopsy case of CBD; the patient had a 2-year history of progressive forgetfulness, apathy, sexual recklessness, episodic depression, and difficulty in walking. The gross examination of the patient's brain revealed mild atrophy of the cerebrum with frontal accentuation, and the histological examination disclosed pathological changes typical of CBD, including globular inclusions positive for tau protein in the neurons of the upper cortical layers. Of the three autopsy cases reported by Wakabayashi et al. [30], one presented with memory impairment and difficulty in carrying out housework as initial symptoms at the age of 71. This patient died 6 years later; the gross examination revealed marked atrophy of the frontal lobe, mainly on the left, with the histology being compatible with CBD, including positive tau pathology in the neurons of the cerebral cortex. In a clinical study of 36 cases, Rinne et al. [23] described one patient with neuropathologically confirmed CBD who presented with gait difficulties and falls as the initial signs, followed by a profound behavioral syndrome with personality changes, bulimia, impulsiveness and frontal lobe release signs. More recently, Brown et al.

Fig. 5 Distribution of cerebral cortical lesions of case 3. For details see Fig. 3



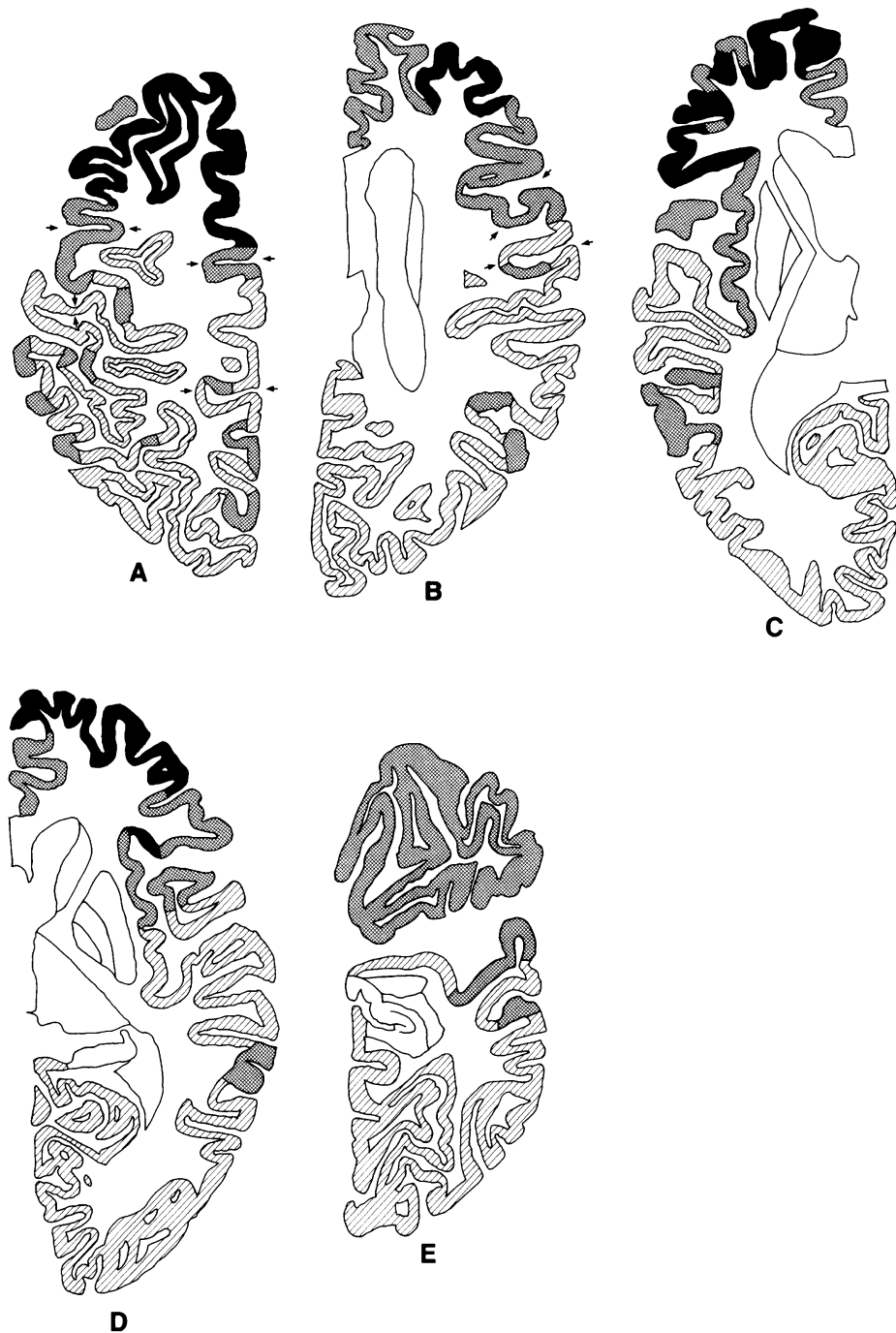[5] reported on two families in which 15 individuals developed progressive dementia with features of frontal lobe dysfunction, including personality changes and stereotyped behavior. The postmortem examination of two patients from separate families disclosed lobar atrophy of the frontotemporal cortex with many swollen neurons and neuronal loss, as well as neuronal loss with gliosis in the pallidum and substantia nigra. Immunohistochemically, the swollen neurons of the two patients showed positive reaction with an antibody to tau protein. The authors indicated that on clinical assessment, the families had many features of Pick's disease, but that the pathological examination revealed hallmarks suggestive of CBD. In regard to the multiplicity of clinical features of the disease, the study by Feany and Dickson [6], who examined 11 patients with autopsy-proven CBD, is particularly interesting. They state that few cases have clinical features generally considered to be typical of CBD, and suggest that

most patients meeting the neuropathological criteria for the disorder would not be diagnosed ante mortem.

Based on our data, and on the atypical autopsy cases referred to above, we postulate that the clinical features of CBD have a much wider spectrum than previously believed.

It has been reported that the focal atrophy in CBD was confined to the frontal and/or parietal lobes. Of the three cases described by Rebeiz et al. [20, 21], the most striking abnormality was in the superomedial frontoparietal cortex with asymmetry in two of them. The Betz cells in the precentral cortex of one patient appeared normal with a good complement of Nissl granules [21]. In another study on neuropathologically verified CBD, the gross examination disclosed very marked atrophy of the precentral and postcentral gyri, and the microscopic examination of the precentral gyrus revealed severe neuronal loss with gliosis and absence of Betz cells [24]. On the other hand, the

Fig. 6 Distribution of cerebral cortical lesions of case 4. For details see Fig. 3



macroscopical brain examination of the three cases of Gibb et al. [8] disclosed atrophy of the superior parietal region with slight accentuation of the left in one patient, mild atrophy of the posterior frontal and parietal region in another, and mild atrophy of the frontal region in the third.

From the previous data [8, 20, 21, 24] it is evident that the distribution of cerebral cortical lesions in CBD has been determined mainly by macroscopic examination. Hence, our study on the distribution of such lesions based on the detailed microscopic examination of hemisphere specimens provides information not available heretofore.

From our results it is obvious that the lesions do not predominate in the paracentral region, and that the most severe lesions of CBD are mainly in the frontal lobe. By comparison, the primary motor area of the CBD patients exhibited mostly slight to moderate damage.

The lesion responsible for limb-kinetic apraxia has until now been a matter of discussion. Limb-kinetic apraxia has been most commonly attributed to alterations of frontal or rolandic areas from the proposal by Liepmann [13]. The lesion responsible for limb-kinetic apraxia has also been attributed to the premotor area by some researchers

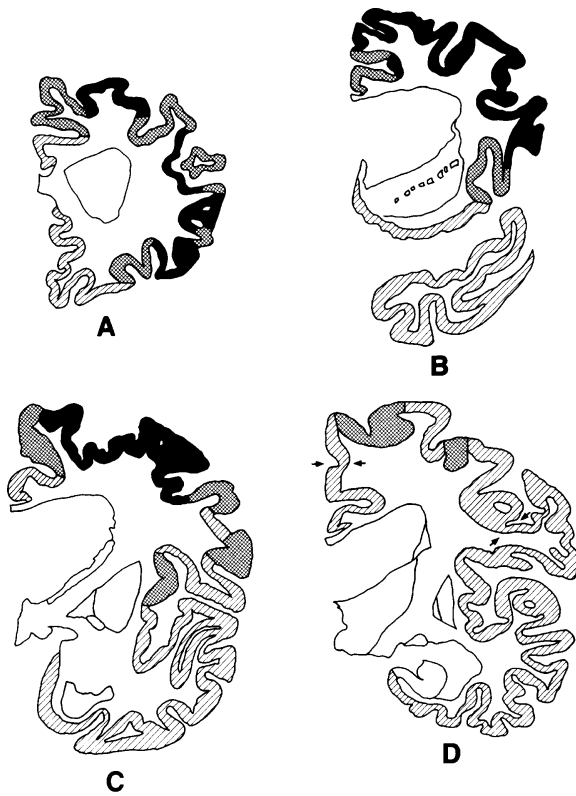


Fig. 7 Distribution of cerebral cortical lesions of case 5. For details see Fig. 3

[7]. Freund and Hummelsheim [7], who observed 11 patients with frontal lobe lesions on the side opposite to limb-kinetic apraxia, attributed limb-kinetic apraxia to an involvement of the premotor area. The cerebral lesion of CBD has been thought to be prominent in the paracentral region, chiefly based on macroscopical examination. Therefore, limb-kinetic apraxia of CBD has been attributed to the lesion of precentral and postcentral gyri.

Our CBD patients whose initial sign was limb-kinetic apraxia (cases 1 and 3), had slight to moderate lesions in the primary motor area, including Betz cells. By contrast, both had mostly severe lesions in the posterior portions of the frontal lobe, including the premotor and supplementary motor areas. We suggest on the basis of these findings that the limb-kinetic apraxia of CBD patients would appear to be due to damage of the premotor area, with or without involvement of the supplementary motor area.

There have been several recent reports on autopsy cases of CBD presenting with primary progressive aphasia [2, 3, 30]. The case reported by Arima et al. [2] developed aphasia and hearing loss as the initial signs at the age of 64, followed by personality changes and dementia, and died at the age of 73. The postmortem examination revealed severe focal atrophy of the cerebral convolutions in the frontal operculum, superior frontal gyrus, and superior and transverse temporal gyri. In this case, argyrophilic neuronal inclusions of the cerebral cortex and deep gray matter showed positive reaction with anti-tau. An atypical autopsy case of CBD was described by Berg-

eron et al. [3], in which extensive deposition of abnormal tau in the neurons was evident. The patient had had an isolated speech disturbance for 5 years before developing the more typical motor features of CBD. The neuropathological examination showed atrophy of the left posterior frontal lobe. Wakabayashi et al. [30] also described a variant case of CBD with positive tau pathology, who presented motor aphasia as the initial sign at the age of 67. The patient died at age 73, and the neuropathological examination revealed marked atrophy of the frontal, precentral, and parasylvian gyri, with the histology being compatible with CBD.

Based on our results on the distribution of cerebral cortical lesions in CBD, and on the atypical autopsy cases who had primary progressive aphasia [2, 3, 30], we consider that focal cerebral atrophy of CBD is multicentric. We can assume that the "atrophic center" is present in the anterior and posterior portions of the frontal lobe and in the parasylvian region, including the first temporal gyrus. In addition, we also believe that when the lesion starts in the anterior portion of the lobus frontalis, the clinical features of CBD mimic those of PSP or frontal Pick's disease, and that when these features present with primary progressive aphasia, the lesion begins in the parasylvian region including the first temporal gyrus.

References

1. Arai N, Oda M (1996) A variety of glial pathological structures by the modified Gallyas-Braak method. *Neuropathology* 16: 133–138
2. Arima K, Uesugi H, Fujita I, Sakurai Y, Oyanagi S, Andoh S, Izumiyama Y, Inose T (1994) Corticonigral degeneration with neuronal achromasia presenting with primary progressive aphasia: ultrastructural and immunohistochemical studies. *J Neurol Sci* 127: 186–197
3. Bergeron C, Pollanen MS, Weyer L, Black SE, Lang AE (1996) Unusual clinical presentations of cortical-basal ganglionic degeneration. *Ann Neurol* 40: 893–900
4. Braak H, Braak E, Ohm T, Bohl J (1988) Silver impregnation of Alzheimer's neurofibrillary changes counterstained for basophilic material and lipofuscin pigment. *Stain Technol* 63: 197–200
5. Brown J, Lantos PL, Roques P, Fidani L, Rossor MN (1996) Familial dementia with swollen achromatic neurons and corticobasal inclusion bodies: a clinical and pathological study. *J Neurol Sci* 135: 21–30
6. Feany MB, Dickson DW (1995) Widespread cytoskeletal pathology characterizes corticobasal degeneration. *Am J Pathol* 146: 1388–1396
7. Freund HJ, Hummelsheim H (1985) Lesions of premotor cortex in man. *Brain* 108: 697–733
8. Gibb WRG, Luthert PJ, Marsden CD (1989) Corticobasal degeneration. *Brain* 112: 1171–1192
9. Ikeda K, Akiyama H, Haga C, Kondo H, Arima K, Oda T (1994) Argyrophilic thread-like structure in corticobasal degeneration and supranuclear palsy. *Neurosci Lett* 174: 157–159
10. Ikeda K, Akiyama H, Kondo H, Haga C (1995) A study of dementia with argyrophilic grains. Possible cytoskeletal abnormality in dendrospinal portion of neurons and oligodendroglia. *Acta Neuropathol* 89: 409–414
11. Jackson M, Lowe J (1996) The new neuropathology of degenerative frontotemporal dementias. *Acta Neuropathol* 91: 127–134

12. Lang AE, Riley DE, Bergeron C (1994) Cortical-basal ganglionic degeneration. In: Calne DB (ed) *Neurodegenerative disease*. Saunders, Philadelphia, pp 877–894
13. Liepmann H (1920) Apraxie. *Ergeb Ges Med* 1: 516–543
14. Litvan I, Hauw JJ, Bartko JJ, Lantos PL, Daniel SE, Horoupian DS, Mckee A, Dickson D, Bancher C, Tabaton M, Jellinger K, Anderson DW (1996) Validity and reliability of the preliminary NINDS neuropathologic criteria for progressive supranuclear palsy and related disorders. *J Neuropathol Exp Neurol* 55: 97–105
15. Mitani K, Uchihara T, Tamaru F, Endo K, Tsukagoshi H (1993) Corticobasal degeneration: clinico-pathological studies on two cases (in Japanese with English abstract). *Clin Neurol (Tokyo)* 33: 155–161
16. Oda T, Kogure T, Tominaga I, Onaya M, Mimura M, Kato Y, Iwabuchi K, Haga C (1994) An autopsy case of progressive supranuclear palsy with echolalia showing psychiatric symptoms at the beginning (in Japanese). *Seishinagaku* 36: 1159–1166
17. Oda T, Ikeda K, Akamatsu W, Iwabuchi K, Akiyama H, Kondo H, Seta K, Kato Y, Kogure T, Hori K, Tominaga J, Onaya M (1995) An autopsy case of corticobasal degeneration clinically misdiagnosed as Pick's disease (in Japanese with English abstract). *Psychiatr Neurol Jpn* 97: 757–769
18. Paulus W, Selim M (1990) Corticonigral degeneration with neuronal achromasia and basal neurofibrillary tangles. *Acta Neuropathol* 81: 89–94
19. Pick A (1892) Über die Beziehungen der senile Hirnatrophie zur Aphasie. *Prag Med Wochenschr* 17: 165–167
20. Rebeiz JJ, Kolodny EH, Richardson EP Jr (1967) Corticodentatonigral degeneration with neuronal achromasia: a progressive disorder of late adult life. *Trans Am Neurol Assoc* 92: 23–26
21. Rebeiz JJ, Kolodny EH, Richardson EP Jr (1968) Corticodentatonigral degeneration with neuronal achromasia. *Arch Neurol* 18: 20–33
22. Riley DE, Lang AE, Lewis A, Resch L, Ashby P, Hornykiewicz O, Black S (1990) Cortical-basal ganglionic degeneration. *Neurology* 40: 1203–1212
23. Rinne JO, Lee MS, Thompson PD, Marsden CD (1994) Corticobasal degeneration. A clinical study of 36 cases. *Brain* 117: 1183–1196
24. Scully RE, Mark EJ, McNeely BU (1985) Case records of the Massachusetts General Hospital (case 38–1985). *N Engl J Med* 313: 739–748
25. Scully RE, Mark EJ, McNeely WF, McNeely BU (1993) Case records of the Massachusetts General Hospital (case 46–1993). *N Engl J Med* 329: 1560–1567
26. Steele JC, Richardson JC, Olszewski J (1964) Progressive supranuclear palsy. A heterogeneous degeneration involving the brain stem, basal ganglia and cerebellum with vertical gaze and pseudobulbar palsy, nuchal dystonia and dementia. *Arch Neurol* 10: 333–359
27. Tsuchiya K, Watabiki S, Owada K, Kusano F, Hamaguchi H, Horikawa N, Ii E, Sano M (1994) Pick's disease in senescence (in Japanese with English abstract). *Brain Nerve (Tokyo)* 46: 787–792
28. Tsuchiya K, Ikeda K, Watabiki S, Shiozu H, Hashimoto K, Mitani K, Okiyama R, Sano M, Kondo H, Shimada H (1996) An unusual autopsy case of corticobasal degeneration with special reference to clinicopathological differentiation from progressive supranuclear palsy and slowly progressive aphasia (in Japanese with English abstract). *Brain Nerve (Tokyo)* 48: 559–565
29. Uchihara K, Mitani K, Mori H, Kondo H, Yamada M, Ikeda K (1994) Abnormal cytoskeletal pathology peculiar to corticobasal degeneration is different from that of Alzheimer's disease or progressive supranuclear palsy. *Acta Neuropathol* 88: 379–383
30. Wakabayashi K, Oyanagi K, Makifuchi T, Ikuta F, Homma A, Homma Y, Horikawa Y, Tokiguchi S (1994) Corticobasal degeneration: etiopathological significance of the cytoskeletal alterations. *Acta Neuropathol* 87: 545–553