

12. Tolge CF, Factor S. Focal dystonia secondary to cerebral toxoplasmosis in a patient with AIDS. *Mov Disord* 1991;6:69-72.
13. Metzger WS. Movement disorders with AIDS encephalopathy: case report. *Neurology* 1987;37:1438.
14. Lee MS, Marsden CD. Movement disorders following lesions of the thalamus or subthalamic region. *Mov Disord* 1994;9:493-507.
15. Mooro Y, Hirayama K, Kojima S. Involuntary movements caused by thalamic lesion. *Rinsho Shinkeigaku* 1994;34:804-811.
16. Lee MS, Lee SA, Heo JK, Chor IS. A patient with resting tremor and a lacunar infarction at the border between the thalamus and the internal capsule. *Mov Disord* 1993;8:244-246.
17. Chika J, Bogousslavsky J, Henderson J, et al. The "jerky dystonic unsteady hand": a delayed motor syndrome in posterior thalamic infarctions. *J Neurol* 1994;241:537-542.
18. Miwa H, Hatori K, Kondo T, Imai H, Mizuno Y. Thalamic tremor: case reports and implications of the tremor-generating mechanism. *Neurology* 1996;46:75-79.
19. Navia BA, Petito CK, Gold JWM, et al. Cerebral toxoplasmosis complicating the acquired immune deficiency syndrome: clinical and neuropathological findings in 27 patients. *Ann Neurol* 1986;19:224-238.

### Delayed Onset Postural Tremor Caused by Parietal Lesion



Postural tremor stemming from a focal brain lesion was originally described by Benedikt (1) and Holmes (2) as being caused by a lesion of the midbrain and was recently reported as being associated with lesions of the thalamus (3-5). In this

A videotape accompanies this article.

Received February 8, 1996; revision received June 25, 1996. Accepted January, 1997.

Address correspondence and reprint requests to Dr. I. Moroo at Biotechnology Laboratory, Room 237, Wesbrook Building, University of British Columbia, 6174 University Boulevard, Vancouver, BC, V6T 1Z3 Canada.

report, we describe a patient suffering from tremor of the same character, but after a lesion in the parietal lobe.

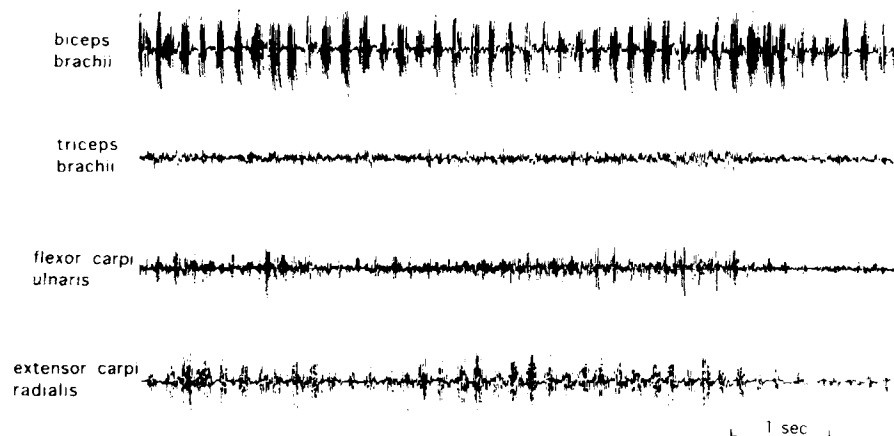
### Case Report

A 56-year-old right-handed man was referred to our hospital for tremor in his right arm. At age 43 (13 years prior to this referral), he had developed sudden right-sided hemiparesis and sensory disturbances associated with paraphasia and alexia. Within several days, his ability to speak and read had improved, but his motor and sensory disturbances continued for months. Six months after the onset of his stroke, when his hemiparesis had improved, he first noticed tremor in his right arm. For the 13 years between its appearance and his referral, the tremor neither worsened nor improved. On examination, he was fully oriented and had neither aphasia nor alexia. His muscular tone and strength of his right arm and leg were normal. The tendon reflexes were generally diminished, with no plantar responses. He had diminished senses of touch, pain, and vibration on his right side, prominently at the distal ends of his limbs but sparing the medial part of his face.

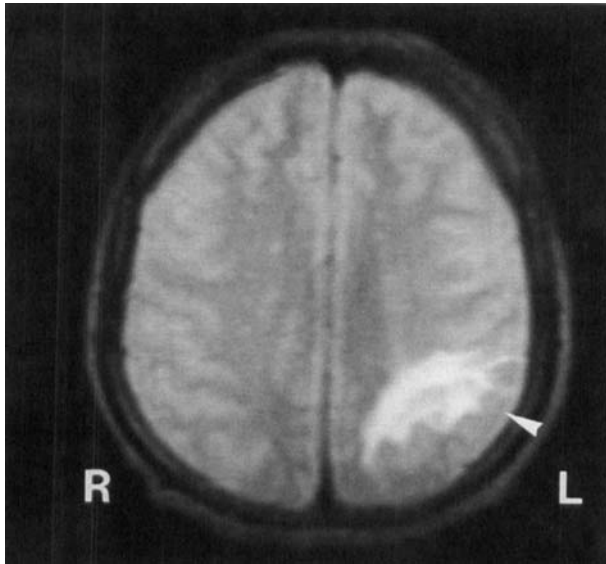
Discriminative senses of position and weight were impaired in his right arm. The tremor was characterized as follows: when lifting his right arm to the horizontal, particularly when his elbow joint was flexed, his forearm moved up and down around his elbow joints. No involuntary movements were observed when his arm was at rest. Surface electromyography recorded from the muscles of the upper right limb showed regular grouping discharge at a rate of 5 Hz (Fig. 1). Magnetic resonance imaging showed a circumscribed lesion in the white matter of the left inferior parietal lobule (Fig. 2). No thalamic, brainstem, or cerebellar lesion was identified. Signal intensity was low in the T1-weighted image and high in the T2-weighted image, which was compatible with infarction. Somatosensory evoked potentials following median nerve stimulation showed disappearance of late cortical components after right stimulation (Fig. 3).

### Discussion

This patient had postural tremor and disturbances of discriminative senses that were most likely caused by a parietal



**FIG. 1.** Surface electromyograph recorded at right biceps brachii, triceps brachii, flexor carpi ulnaris, and extensor carpi radialis shows reciprocal discharges between extensor and flexor muscle groups.



**FIG. 2.** Axial T2-weighted magnetic resonance image (TR = 2,080, TE = 80) at the level of centrum semiovale, showing increased signal intensity at the left inferior parietal lobule (arrowhead) compatible with infarction extending to white matter.

lobe infarction. It is noteworthy that there was a delay between the stroke and the onset of tremor, because this delay is also seen in cases of tremor caused by rubral or thalamic lesions. Such tremor is very rare among patients with a focal parietal lesion. In 1982, Andrews et al. (6) reported delayed-onset tremor of a similar character following infarction in the white matter of the parietal lobe, but did not refer to sensory disturbances accompanied by parietal lesion. According to the presumed mechanism that lesions involving the dentatorubrothalamic pathway induce tremor, it is difficult to explain the relationship between the tremor and the lesion. Ohye (7)

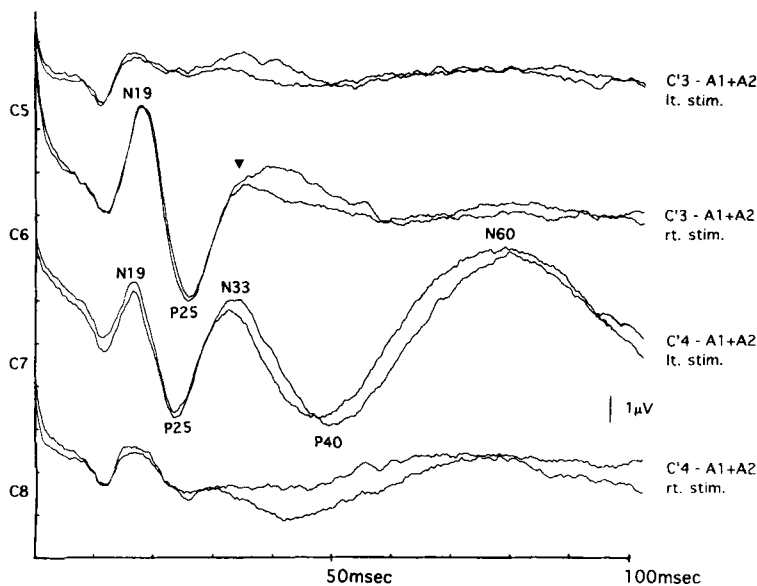
proposed that thalamocortical fibers are one of the neural structures maintaining the rhythmic thalamic discharges. The absence of late cortical components on the affected site, in spite of the presence of preserved early cortical components, suggests that the sensory system was disturbed after reaching the potentials of the primary sensory cortex. Magnetic resonance imaging shows the subcortical white matter of the inferior parietal lobule located in the associated sensory area.

The clinical feature of sensory disturbance, the abnormality of the somatosensory evoked potentials, and the magnetic resonance imaging findings all suggest that this case primarily involves the associated sensory area. We suspect that the parietal subcortical lesion influences the neural circuit of the tremor, thereby inducing the thalamus to generate rhythmicity. In this way, the disturbance of thalamocortical fibers could elicit a postural tremor similar to that from a thalamic lesion. We also think that the time gap between the onset of stroke and the occurrence of tremor reveals that the tremor is not the symptom of a simple defect of neuronal circuitry, but the result of secondary repairing of the nervous system, for example, sprouting.

**Legend to the Videotape**

When the patient stretches his arm to the front of his body, a flexion-extension movement emerges at the wrist joint of his right hand. The tremor does not appear during action and goal-directed movements, but does emerge when the patient reaches his finger to his nose. The tremor is characterized by flexion-extension movement of the forearm and is most prominent when the patient puts his forefingers close together in front of his face.

Iku Moroo  
Keizo Hirayama  
Masashi Nakajima  
*Department of Neurology  
School of Medicine  
Chiba University  
Chiba, Japan*



**FIG. 3.** Alternative stimulation of bilateral median nerves' somatosensory evoked potentials recorded at C'3 and C'4. Right stimulation shows a small delay of N19 (20.0 ms) compared with left stimulation (18.6 ms). N33 was clearly identified at C'4 by left stimulation, but by right stimulation N33 failed to form a clear peak at C'3 (arrowhead). P40 and N60 were absent on the left cortex by right stimulation, whereas an apparent wave was detected on the right cortex by left stimulation.

### References

1. Benedikt M. Tremblement avec palayie croisée du moteur oculaire commun. *Bull Med* 1889;3:547-548.
2. Holmes G. On certain tremors in organic cerebral lesions. *Brain* 1904;27:327-375.
3. Kim JS. Delayed onset hand tremor caused by cerebral infarction. *Stroke* 1992;23:292-294.
4. Mossuto-Agatiello L, Puccetti G, Castellano AE. "Rubral" tremor after thalamic haemorrhage. *J Neurol* 1993;241:27-30.
5. Miwa H, Hatori K, Kondo T, Imai H, Mizuno Y. Thalamic tremor: case reports and implications of the tremor-generating mechanism. *Neurology* 1996;46:75-79.
6. Andrews J, Fowler CJ, Harrison MJG, Kendall BE. Post-traumatic tremor due to vascular injury and its treatment by stereotactic thalamotomy. *J Neurol Neurosurg Psychiatry* 1982;45:560-562.
7. Ohye C. Neurons of thalamic ventralis intermedialis nucleus: their special reference to tremor [in Japanese]. *Shinkei Kenkyu No Shinpo* 1985;29:222-231.

### Sustained Effect of High-Dose Intrathecal Baclofen in Primary Generalized Dystonia: A 2-Year Follow-Up Study



Baclofen is a muscle relaxant and antispastic agent with selective agonist action on GABA-B receptors. In dystonia its mechanism of action remains speculative: At the central level, enhanced GABAergic output from the putamen may cause thalamocortical inhibition, and at the spinal level GABAergic receptor binding may decrease the release of neuroexcitatory transmitters (1,2). Despite these uncertainties, it has been used orally in the treatment of generalized dystonia, with a favorable response in up to 30% of the patients (1). However, marked sedation often precludes the use of therapeutic dosages. Intrathecal delivery of baclofen via an implanted pump (IT-B) could be an alternative because it achieves higher cerebrospinal fluid concentrations and diminishes systemic side effects (3,4). Earlier case reports on its use in dystonic syndromes of mixed origin have given conflicting results. Many issues concerning the method of the intrathecal loading trial, adequate maintenance dosage, and the long-term effect remain unresolved (2, 5-9).

### Case History

A 32-year-old man had developed focal dystonia of the left arm, appearing at age 13. Birth history and early developmental milestones had been normal; prior exposure to neuroleptics was absent. He later developed oromandibular dystonia. At the age of 18, dystonia spread to the lower extremities. At the age of

25, the patient presented to our clinics, disabled by generalized dystonia with features of spasmodic adductor dysphonia, oromandibular and pharyngeal dystonia, intermittent opisthotonus, marked lordotic arching of the trunk, and dystonic movements of all limbs, worse on the left. He could not lie on his back and was mostly wheelchair-bound. Dystonic spasms produced severe muscular pains. His dysphagia and persistent muscle activity left him cachectic. Parkinsonian or spastic features were absent, and the patient denied diurnal fluctuation of his symptoms.

His family history was remarkable for a 25-year-old sister with moderate retrocollis and an 8-year-old nephew with mild lordosis. Laboratory evaluations showed mild iron deficiency anemia and normal values for thyroid, folic acid, B12, ceruloplasmin, prealbumin, retinol binding protein, VDRL, and porphyrins. Peripheral smear for acanthocytosis was negative. Results of cerebrospinal fluid (CSF) testing were normal. Duodenal biopsy, electroencephalography, computed axial tomography with contrast, and psychometric tests also produced normal results.

Medical treatment with benzodiazepines at the age of 13 produced a transient amelioration. The addition of trihexyphenidyl 30 mg/day at the age of 18 was without benefit. The patient failed to show sustained benefit from polytherapy over the next 7 years, including different combinations of trihexyphenidyl (up to 50 mg/day), diazepam (up to 30 mg/day), oxazepam (up to 15 mg/day), haloperidol (up to 4 mg), and levomepromazin (up to 50 mg/day). Oral baclofen was given without sufficient effect up to a dosage of 150 mg/day, at which the patient suffered intolerable and dose-limiting tiredness.

After obtaining oral informed consent, an IT-B test infusion was initiated. IT-B loading dose infusion of 42 µg/h was given continuously during 24 h by an external micropump. Under close supervision, the patient demonstrated a dramatic relief of his dystonic movements at all levels within 12 h. Response was complicated by marked but transient periods of somnolence, without autonomic dysfunction. Upon completion of the infusion challenge, the patient was discharged to home. His dystonic symptoms returned to baseline. One year later, a programmable subcutaneous infusion pump (SynchroMed pump; Medtronic, Minneapolis, MN, U.S.A.) and intrathecal lumbar catheter were implanted for long-term continuous infusion after written informed consent had been given by the patient. The dystonic condition worsened during the immediate postoperative phase, causing suture disruption and dislodgement of the catheter. Other acute complications included temporary catheter disconnection and leak of sterile CSF in the tissue. After catheter revision and vancomycin treatment, baclofen infusion was reinstated, beginning at 150 µg/day and increased to 900 µg/day over a 15-month period. Oral trihexyphenidyl was substantially reduced, and the type of benzodiazepine was exchanged (see Table 1).

The patient was followed as an outpatient with the baclofen pump for 23 months without further side effects or complications. Because of the marked benefit, the patient refused to reduce the IT-B dose. Although the IT-B improved the axial dystonia, cervical dystonia remained unchanged. Therefore, the patient received injections of botulinum toxin into cervical muscles. Five videotape segments were obtained before and during IT-B treatment: The first two clips had been recorded 13 and 4 months before the pump installation and the three others

A videotape accompanies this article.

Received June 19, 1996; revisions received February 25 and April 15, 1997. Accepted May 8, 1997.

Address correspondence and reprint requests to Dr. N. J. Diederich, Department of Neurosciences, Centre Hospitalier de Luxembourg, 4, rue Barblé, L-1210 Luxembourg.